

Otrzymano: 2006.01.24  
Zaakceptowano: 2006.02.08

## Spondylo-metaphyseal dysplasia – Kozlowski type

### Dysplazja kregostupowo-przynasadowa – Kozlowski

Marik I<sup>1</sup>, Zemkova D<sup>1,2</sup>, Baksova A<sup>3</sup>, Kozlowski K<sup>4</sup>

<sup>1</sup> Ambulant Centre for Defects of Locomotor Apparatus, Prague, Czech Republic

<sup>2</sup> Paediatric Clinic of the University Hospital Motol, Prague, Czech Republic

<sup>3</sup> Institute of Biology and Medical Genetics, Charles University, 1<sup>st</sup> Medical Faculty, Prague, Czech Republic

<sup>4</sup> Department of Medical Imaging, Children's Hospital at Westmead, Sydney, Australia

**Adres autora:** K Kozlowski, Children's Hospital at Westmead, Locked Bag 4001; Westmead NSW 2145, Sydney, Australia, e-mail: Kaz.Kozlowski@bigpond.com

### Summary

<b>Background:</b>	Kozlowski type spondylo-metaphyseal dysplasia is the most frequent form among spondylo-metaphyseal dysplasias.
<b>Case report:</b>	The first cases of such dysplasia among Gypsies – a father and two sons – have been described.
<b>Conclusions:</b>	Radiographic examination is the only means by which to diagnose Kozlowski type spondylo-metaphyseal dysplasia with certainty. Correct diagnosis is not only prognostic for the course of the disease and its complications, but also excludes the necessity of further, often expensive, investigations.
<b>Key words:</b>	Spine • kyphosis • metaphyses • spondylo-metaphyseal dysplasia
<b>PDF file:</b>	<a href="http://www.polradiol.com/pub/pjr/vol_71/nr_2/8695.pdf">http://www.polradiol.com/pub/pjr/vol_71/nr_2/8695.pdf</a>

### Background

We report the first Gypsy family with spondylo-metaphyseal dysplasia Kozlowski type (SMDK). The radiographic examination is the only method to diagnose this disorder with certainty. The exact diagnosis is important as it makes all the other investigations including the biochemical tests unnecessary. It also predicts the clinical course and prognosis of the disorder.

### Case Report

#### Case I

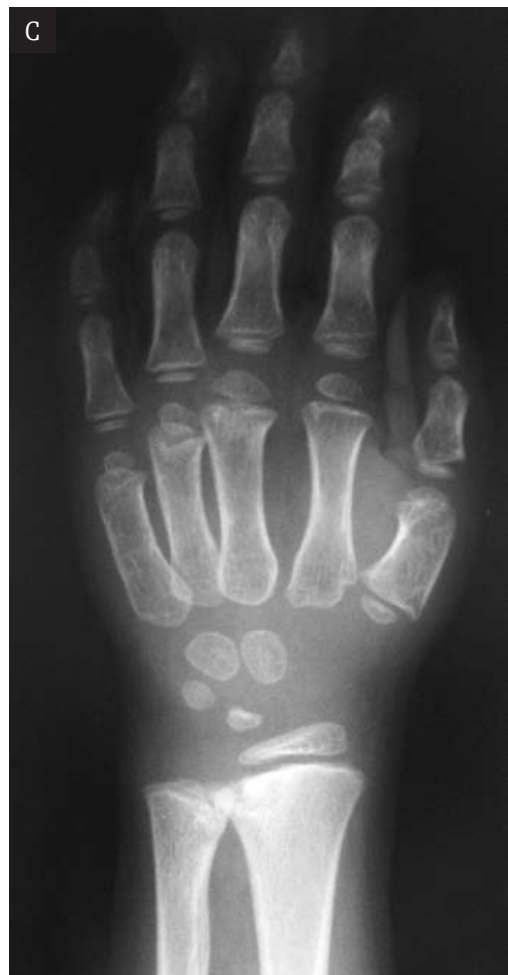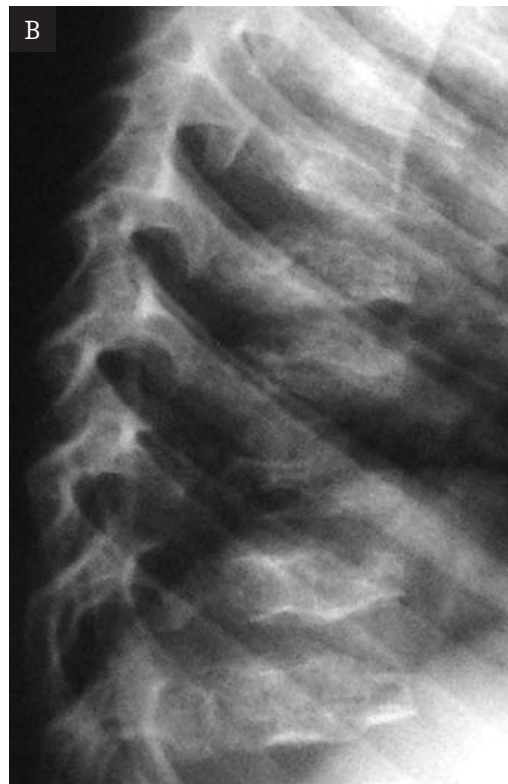
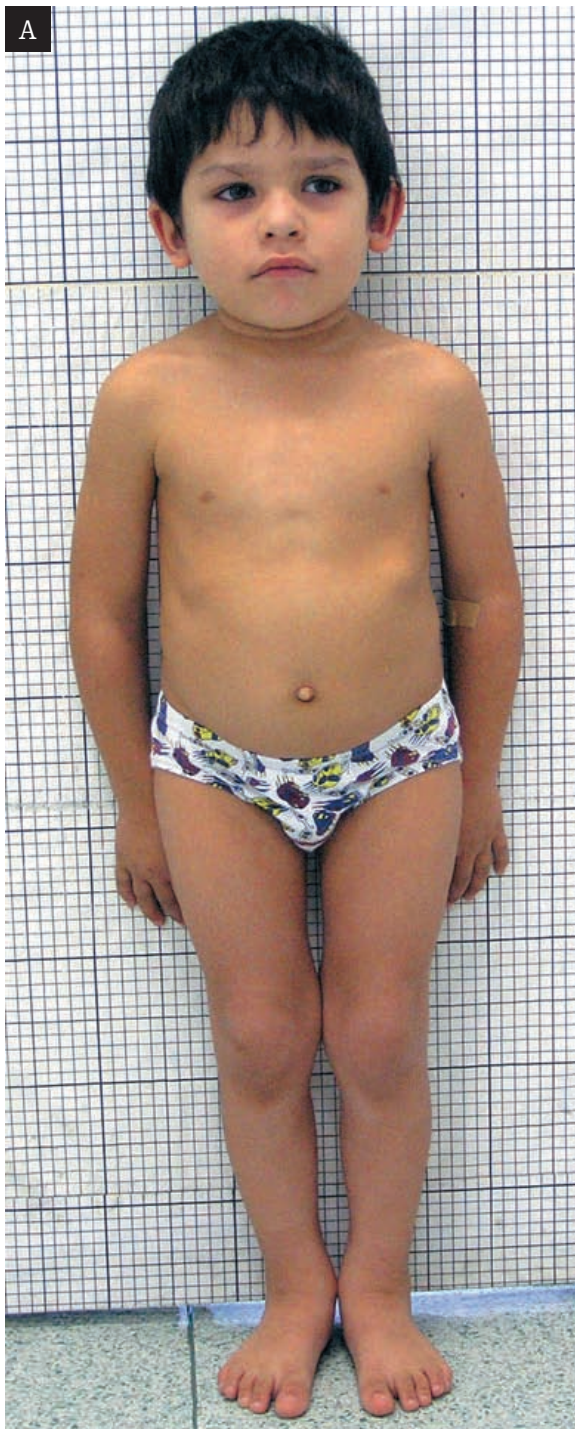This 5 ½ year-old boy born to a G1P1AO normal 19 year-old mother, following a normal confinement. Birth weight 3200 g, length 46 cm. Ultrasound examination in the third trimester of pregnancy showed shortening of the long bones. He was the second child in the family. The first child was normal. The 26 year-old father (CASE III) was of short stature. At 5 ½ years the boy's height was 101 cm (-3SD),

weight 19.5 kg (50–75 centile), sitting height 55 cm (-3.4SD), lower extremities 46.2 cm (-2.3SD), arm span 105 cm (-2.3SD) (Fig. 1A). Apart from prominent forehead no facial dysmorphism was noted. There was kyphosis with limitation of the spine movements. His mental development was normal.

Routine blood, urine and bone turnover examinations (alkaline phosphatase, pyridinoline, desoxypyridinoline, osteocalcine) were all normal. The skeletal survey documented generalised platyspondyly; metaphyseal changes characterised by irregular metaphyseal ossification (most marked at the proximal end of the femora) & narrowing of the growth plates; markedly retarded bone age (Fig. 1B&C).

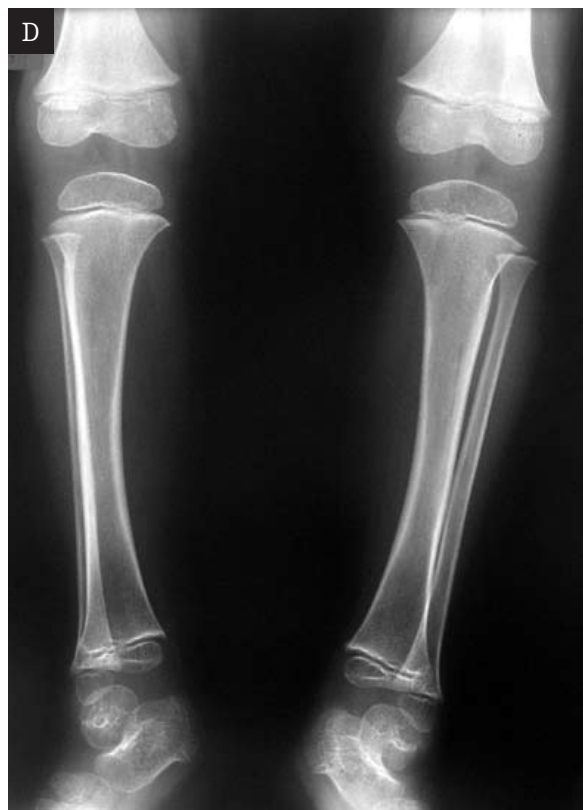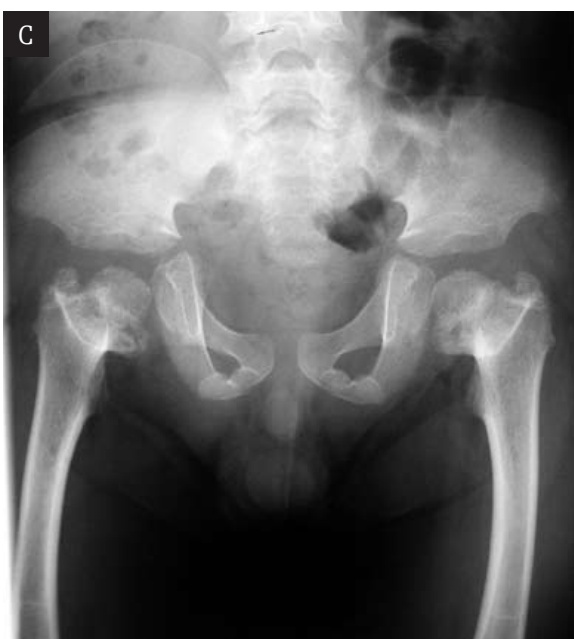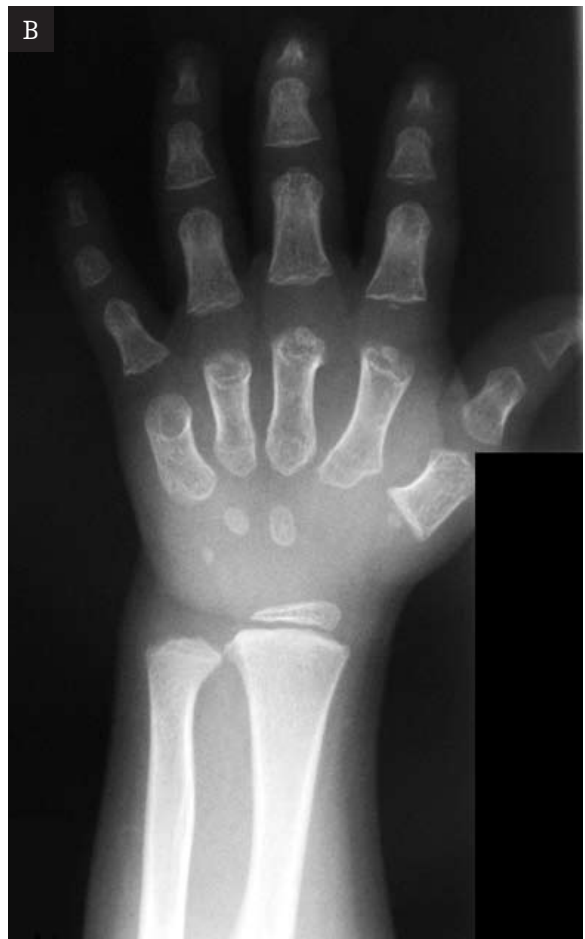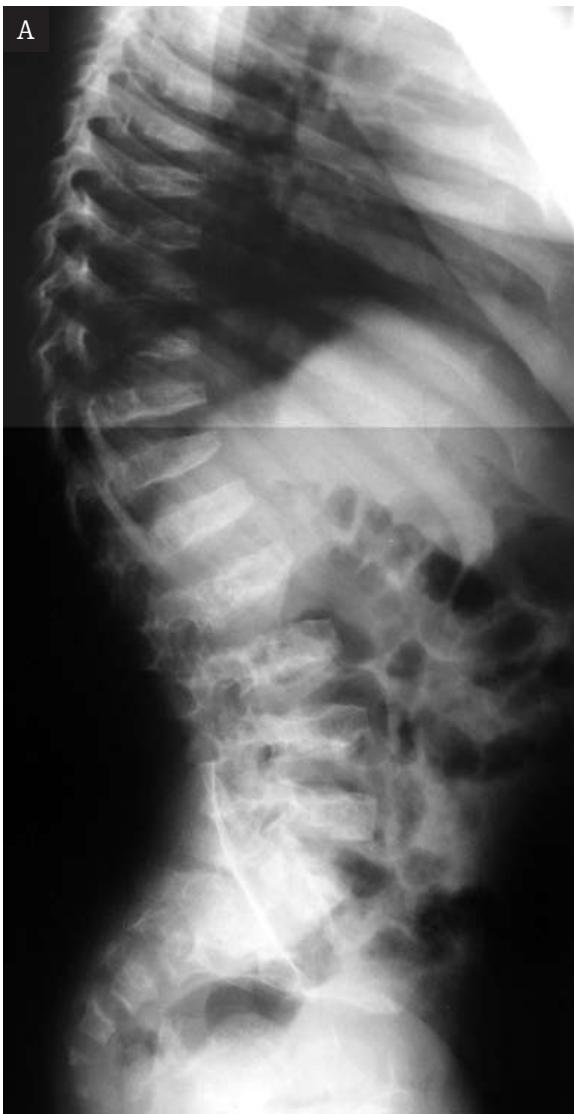#### Case II

This 4 year-old boy, brother of CASE I was born after a normal confinement. Birth weight 3400 g, length 47 cm. Ultrasound examination during the pregnancy was reported as normal.



**Figure 1 A-C.** CASE I. A 5 ½-year-old boy. **A.** Photograph of the patient. Height 112cm (-2SD). The trunk and the extremities are shortened. Note the broad thorax. **B.** Thoracic kyphosis. Platyspondyly with anterior wedging of the thoracic vertebrae. **C.** Bone age corresponds to the chronological age of about 3 ½ years. Note narrow radial growth cartilage.

**Rycina 1 A-C.** Przypadek I. Chłopiec w wieku 5 ½ lat. **A.** Zdjęcie chłopca. Wzrost 112cm (-3SD). Skrócenie tułowia i kończyn. Szeroka klatka piersiowa. **B.** Tylne skrzywienie kręgosłupa piersiowego. Spłaszczenie kręgów piersiowych zwłaszcza w części przedniej. **C.** Wiek kostny odpowiada wiekowi chronologicznemu 3 ½ lat.



**Figure 2 A-D.** CASE II. A 4-year-old boy. **A.** Thoracic kyphosis, lumbar hyperlordosis. Platyspondyly with anterior wedging of the thoracic vertebrae. **B.** Bone age corresponds to the chronological age of about 2 years. Note narrow radial growth cartilage and minimal metaphyseal irregularity. **C.** Short sacro-iliac notches, broad prominent iliac wings. Horizontal acetabular roofs. Short femoral necks with severely dysplastic proximal femoral metaphyses. Normal proximal femoral epiphyses. **D.** Minimal metaphyseal irregularity. Note very narrow growth cartilage.

**Rycina 2 A-D.** Przypadek II. Chłopiec w wieku 4 lat. **A.** Tylne skrzywienie kręgosłupa piersiowego, hyperlordoza kręgosłupa lędźwiowego. Spłaszczenie kręgów piersiowych zwłaszcza w części przedniej. **B.** Wiek kostny odpowiada wiekowi chronologicznemu około 2 lat. Zwężenie chrząstki wzrostowej kości promieniowej wraz z niewielką nieregularnością przynasady. **C.** Skrócone wcięcia biodrowo-krzyżowe, szerokie, rozłożyste talerze kości biodrowych. Poziome panewki stawów biodrowych. Krótkie szyjki kości udowych z znacznymi zmianami dysplastycznymi w bliższej przynasadzie kości udowych. Jądra kostnienia główek kości udowych są w normie. **D.** Nieznaczna nieregularność przynasad. Wyraźne zwężenie chrząstek wzrostowych.

At the age of 4 7/12 years he showed marked shortening of the trunk and the extremities. There was a thoracolumbar kyphoscoliosis with limitation of spinal and hip movements. Measurements: height 87cm (-4.3SD), weight 14 kg (90 centile). Sitting height 51 cm (-3.9SD), lower extremities 36 cm (-4.8SD), arm span 89 cm. His face was normal. Biochemical tests, as in his brother were all normal. Radiographs showed same changes as his brother (Fig. 2A-D).

### Case III

Father of cases I and II was diagnosed as being affected, having spondylo-metaphyseal dysplasia, possibly SMDK. Measurements: height 133 cm (-6.7SD), sitting height 62.9 cm (-8.8SD), leg length 70.1cm (-3.1SD), arm span 158 cm. No other members of his previous generations were of short stature.

### Discussion

The major radiographic signs of SMDK are **platyspondyly with characteristic shape (wedging) of the vertebral bodies, dysplastic metaphyseal involvement and retarded bone age**. All these features are not present at birth but develop in the first few years of life. They disappear – apart from platyspondyly – in adulthood (CASE III). Therefore the diagnosis of SMDK can not be established early in life. It can be suspected in adults. The optimal age for the diagnosis of the disease is childhood when all the

radiographic characteristics – platyspondyly, metaphyseal dysplasia and retarded bone age – are present [1–5].

Both our boys presented all the diagnostic features of SMDK (Fig1&2). Diagnosis of spondylo-metaphyseal dysplasia possibly Kozłowski type was made in the father (CASE III) by AB. It became a certainty after the skeletal surveys of the sons were performed (CASES I & II).

The diagnosis of SMDK is easy in our experience. Diagnostic difficulties appear with *insufficient radiographic documentation*. Similar spinal changes might be present in brachyrrhachia, other rare ill defined forms of spondylo-metaphyseal dysplasia, and specifically, metatropic dysplasia. In brachyrrhachia the changes – platyspondyly – are limited to the spine. The ill defined forms of spondylo-metaphyseal dysplasia have different pattern of distribution of the spinal, metaphyseal and carpo/tarsal changes. In metatropic dysplasia spinal changes may be identical to those of SMDK. However metatropic dysplasia is a spondylo-epi-metaphyseal dysplasia and the epiphyses are also affected. Further clues to diagnosis of metatropic dysplasia is the narrow chest and elongation of sacro-coccygeal spine. Shape of the pelvis and hip involvement may present additional useful differential diagnostic sign (6). SMDK is an autosomal dominant disorder. About 60 cases, none of them in Gypsies, were reported up to 2000. The corresponding author knows of several single cases and a large USA family not yet reported. The chromosomal location and molecular defect of the disease is unknown.