

Otrzymano: 2006.05.23  
Zaakceptowano: 2007.09.30

## Radiologic features of all-trans-retinoic acid syndrome (ATRAS) – case report

Joanna Konarzewska<sup>1</sup>, Damian Szatkowski<sup>2</sup>, Arkadiusz Szarmach<sup>3</sup>,  
Agnieszka Bianek-Bodzak<sup>1</sup>

<sup>1</sup> Department of Neonatological Gynaecological and Urological Radiology, Medical University of Gdańsk, Poland

<sup>2</sup> Hematology Department, Medical University of Gdańsk, Poland

<sup>3</sup> Radiology Department, Institute of Radiology and Nuclear Medicine, Medical University of Gdańsk, Poland

**Author's address:** dr med. Joanna Konarzewska, Department of Neonatological Gynaecological and Urological Radiology, Medical University of Gdańsk, Poland, e-mail: j.konarzewska@wp.pl

### Summary

**Background:**

ATRA Syndrome appears as a side effect of acute promyelocytic leukemia treatment with ATRA, vitamin A derivative. The etiopathogenesis of the syndrome remains unclear. Fever, generalized edema, pleural or pericardial effusion, respiratory distress, coagulation disorders and sometimes renal failure are the most common clinical symptoms of ATRAS. Radiological features of the syndrome are very diverse. Early diagnosis followed by introduction of appropriate treatment (corticosteroids) prevents worsening of the patients' condition and significantly reduces the risk of death. Although clinical symptomatology of ATRAS has been widely described, there are still few descriptions of its radiological manifestation.

**Case report:**

A 53-year-old female was referred to the Hematology Department for further detailed diagnostics and appropriate therapy from the district hospital, where she had been primarily admitted due to weakness, easy fatigue, loss of appetite and blood extravasations on the skin of the extremities. The patient's general condition on admission was assessed as quite good. Acute promyelocytic leukemia (AML M3 according to FAB classification) was diagnosed. The introduced treatment included ATRA. On the second day of treatment, the patient developed fever, dyspnea, generalized edema, and coagulation disorders increased. Chest X-ray findings reminded ARDS. The diagnosis of ATRAS was established, which resulted in ATRA withdrawal. After administration of corticosteroids, the patient's condition improved gradually within a few days. ATRA was reintroduced then, since the signs of leukemia had intensified. The patient remains in charge of the Hematology Department.

**Conclusions:**

Changes of chest X-ray pictures in AML patients treated with ATRA should be interpreted in clinical context due to lack of radiological features specific for ATRAS.

**Key words:**

**ATRAS • AML M3 • chest X-ray • radiological features of ATRA**

**PDF file:**

<http://www.polradiol.com/fulltxt.php?ICID=510542>

### Background

ATRA Syndrome (All-Trans-Retinoic Acid Syndrome, ATRAS) develops as a complication associated with treatment of some myeloproliferative diseases with ATRA, a vitamin A derivative, which is a physiological component of plasma. Administered to patients with acute promyelocytic leukemia (M3 according to FAB classification), ATRA stimulates the process of promyelocytic differentiation into mature granulocytes.

Etiopathogenesis of the syndrome, described for the first time by Frankel et al. in 1992, has not been elucidated equivocally [1, 2, 3]. According to Dubois et al. [4, 5] and Gentile et al. [6], increased secretion of cytokines (IL-1beta, IL-6, IL-8 or TNF-alpha) in the process of ATRA-induced differentiation of promyelocytes may play a role here. Another hypothesis presumes that promyelocytes differentiated as a result of treatment with ATRA, despite some properties characteristic of neutrophils (e.g. migration to tissues), remain in other respects functionally

immature, which may lead to some organic abnormalities observed in the course of ATRAS [7, 8, 9, 10]. Some researchers emphasize also the role of integrins (leukocytic adhesion receptors) in the mechanism of endothelial damage. ATRA increases the expression of genes encoding these receptors [3, 7, 11].

Characteristic symptoms of ATRAS include: fever of unclear etiology, body mass increase due to excessive fluid accumulation in the extravascular space, transudates to the cavities of the body (especially the pleural cavity and the pericardium), respiratory problems, abnormalities of the coagulation system, diffuse bleeding, and sometimes also the signs of renal insufficiency.

The radiological presentations of ATRAS are characterized by a wide variety of abnormalities: enlarged heart contour (increased cardiopulmonary index), enhanced vascular markings, signs of congestion, interlobar fissure widening due to fluid transudation present in the pleura, air bronchogram. The pulmonary interstitial abnormalities, may appear in the form resembling frosted glass, densities or nodular pattern. Sometimes bronchial wall thickening is noted. The aforementioned changes resemble those observed in acute pulmonary edema or ARDS.

Although the complication is infrequent, numerous symptoms and sometimes dramatic clinical course require intensive therapy. As indicated by the literature data, early diagnosis and prompt institution of treatment (corticosteroids, oxygen therapy) prevents progression of organic dysfunctions and significantly reduces the risk of fatal outcome.

The clinical symptomatology of ATRAS has been described extensively in available literature. However, reports concerning radiological manifestations of this syndrome are scarce [7, 12, 13].

## Case report

A 53-year-old female patient was referred for extended diagnostics and treatment to the MUG Hematology Department from the Municipal Hospital in Gdynia, where she had been admitted because of weakness, easy fatigue, loss of appetite and effusions on the extremities.

Eight years before, the patient had been diagnosed with type 2 diabetes, treated subsequently with oral hypoglycemic agents (Metformin). She had also been treated for arterial hypertension (Enarenal, Amlozek) for a few years. She was also suffering from glaucoma and had occasionally taken medication for osteoarthritis during the last 3 years preceding hospitalization.

The patient's general condition on admission to the Hematology Department was assessed as quite good. On physical examination, overweight, leucoderma, blood extravasations on distal parts of the extremities, as well as signs of dehydration were observed. Laboratory investigations revealed anemia (hemoglobin level (Hb) – 8.8 g/dl), increased leukocytosis (leukocytes (WBC) – 48 g/l), thrombocytopenia (blood platelets (PLT) 22g/l), abnormal coagulation system parameters (increased D-dimers level, decrease

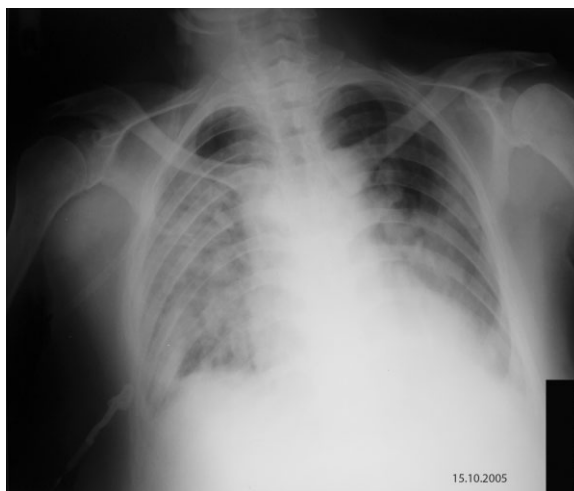of kaolin-kephalin time, prothrombin index and fibrinogen) and hyperglycemia (glucose – 358 mg/dl). On the basis of overall clinical presentation, including blood cell count, immunophenotyping, cytochemical and cytogenetic investigations of the bone marrow, acute promyelocytic leukemia (AML M3 according to FAB) was diagnosed.

The treatment was instituted: Vesanoid, Cyclonamine, platelet mass. In order to compensate the glycemia level, a short-lasting insulin preparation and Mixtard 30 insulin was introduced in addition to Metformin. The patient received also Omeprazole and rehydrating fluids. On the second day, daunorubicin and Zofran were added. Fresh frozen plasma transfusion was also given to the patient.

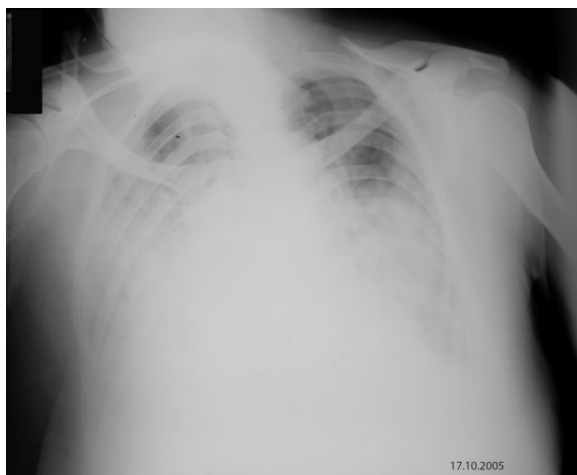
On the third day of hospitalization, the patient developed fever (39.6°C) with significant dyspnea. Physical examination revealed bilaterally reduced vesicular murmur in the lower 2/3 of the lungs, which was accompanied by numerous crepitant rales on auscultation. The heart rate was regular (84/min), blood pressure 140/80. Edema of the lower legs and feet was noted. Chest X-ray (fig. 1) visualized extensive merging areas of interstitial opacities or condensating in the lower and central portions of both lungs, and traces of fluid in the pleural cavity. Despite the heart contours obscured by a mediastinal shadow, the left ventricle was described as enlarged. The radiological picture resembled that of ARDS. The aforementioned X-ray, as well as all subsequent ones, were performed using the same technique.

On a radiogram obtained a few days before in the Municipal Hospital, the picture of thoracic organs revealed no abnormalities.

Laboratory tests still shared increased leukocytosis (WBC–32.5 g/l), anemia (Hb–9.59 g/dl), thrombocytopenia (PLT–35 g/l), decreased fibrinogen level and hyperglycemia. Bacteriological investigations (swabs from body cavities, blood and urine cultures) were negative.



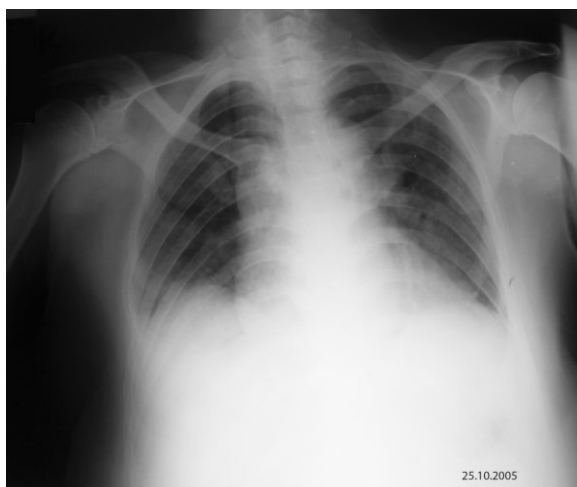**Figure 1.** Third day of hospitalization (ATRAS beginning). Extensive parenchymal infiltrates in both lungs. Pulmonary apices spared. Trace of fluid in the pleural cavities. Enlarged left ventricle. Radiological findings resemble ARDS.



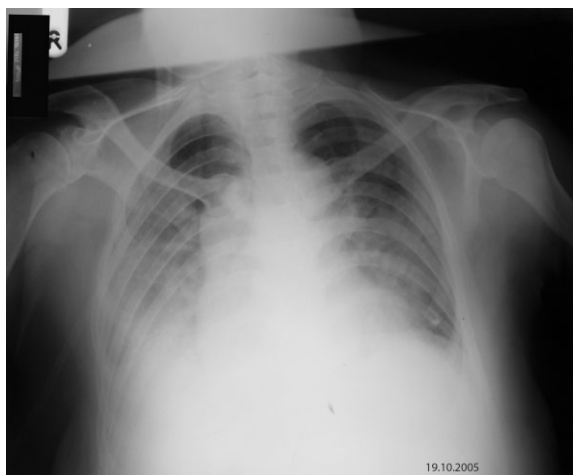**Figure 2.** Fifth day of hospitalization. Pulmonary consolidations still present. Amount of pleural effusion increased.

The diagnosis of ATRAS was established. Vesanoïd and daunorubicin were withdrawn. Corticosteroids (Dexamethasone) and oxygen therapy were instituted. Other medications were given in unchanged doses. The patient also received antibiotics (Augmentin, Aminkin) until the results of bacteriological investigations were obtained.

Temperature reduction to the level below 37°C was obtained, with a slight improvement of the patient's general condition. X-ray performed on day 5 of hospitalization still revealed extensive density areas and increased amount of fluid in both pleural cavities (fig. 2). On the next days, the patient's condition improved gradually – the dyspnea and edema were reduced, and no new extravasations appeared. Crepitant rales over the lung fields were still present on auscultation. Laboratory tests revealed reduction of leukocytosis (WBC–13 g/l). On day 7, another chest X-ray (fig. 3), revealed partial regression of interstitial abnormalities, total regression of exudate in the right pleural cavity and a small amount of fluid in the right pleural cavity, as well as normalization of heart size.



**Figure 4.** Thirteenth day of hospitalization. Further regression – the lungs free from pathological changes, trace of fluid within the right pleural cavity.



**Figure 3.** Seventh day of hospitalization. Partial regression of parenchymal infiltrates. Complete regression of pleural effusion within the left pleuro-costal recess and trace of fluid within the right one. Heart shape – normal.

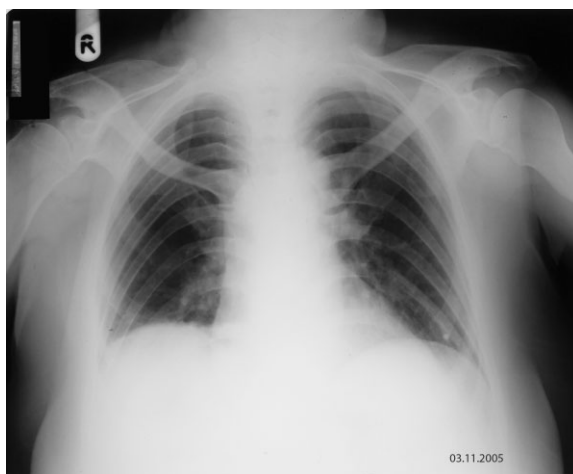
On the subsequent days of hospitalization, the respiratory symptoms subsided gradually. However, the signs of hemorrhagic diathesis (extravasations) increased, and laboratory investigations revealed increased leukocytosis (on day 12, WBC 47.95g/l), aggravation of anemia and worsening of the coagulation system parameters. At that time (day 13), further regression of pulmonary abnormalities was observed on chest X-ray – no densities in the lung fields and traces of fluid in the left pleural cavity (fig. 4).

Because of deterioration of symptoms of the underlying disease, it was decided to reintroduce daunorubicin and Vesanoïd.

Control chest X-ray performed on day 37 (fig. 5) revealed no pathologic changes. The patient remains in charge of the Hematology Department because of the underlying disease.

## Discussion

As it follows from literature data, the signs of ATRAS have been observed mainly in the course of AML M3. The use of



**Figure 5.** Thirty seventh day of hospitalization. Normal chest X ray picture.

ATRA in other forms of AML is still being tested in clinical trials, and the reports concerning the development of ATRAS in the course of the disease are casuistic in character [14]. In a study by Frankel et al., the signs of the syndrome were observed in 25% of 35 treated patients [1]. According to Jung et al., the symptoms of ATRAS appeared in 22% of 69 patients [7]. In a study by Botton et al., carried out in a larger group of patients, the incidence of the syndrome amounted to 15% [15].

The time of onset of ATRAS ranged from a few hours to several dozen days after the institution of the therapy [1, 7, 15, 16, 17]. In the reported case, like in the studies by Botton et al. and Frankel et al. [1], the symptoms were observed starting from the second day of treatment.

The predominant symptoms included the signs of respiratory failure, increased body temperature and edema – observed most frequently also by other authors [1, 2, 3, 7, 10, 13, 15]. No signs of renal failure, observed sometimes in the course of the syndrome [3, 7, 15], were noted in our patient. The patient demonstrated no clinical signs indicating intrapulmonary hemorrhage, which can be observed at the later stages in more dramatic forms of the syndrome [2, 13, 18, 19].

A chest radiogram obtained on the first day of hospitalization revealed cardiomegaly, merging density areas in the lungs and the present of fluid in the pleural cavities

– which are relatively consistent radiological symptoms of ATRAS [1, 2, 3, 7, 12, 15]. The picture of lungs resembled that of ARDS. According to Jung et al., the picture of this type usually corresponds with progression of the syndrome and deterioration of the patient's clinical condition [7].

In differential diagnosis, Jung recommends consideration of cardiogenic pulmonary edema, ARDS, pulmonary lesions associated with the myeloproliferative process and pneumonia [7].

Although the lack of histopathological verification makes it impossible to determine unequivocally the character of the changes observed in the reported case, negative bacteriological results seem to exclude the infectious etiology. Cardiogenic edema also seems unlikely in view of negative cardiovascular history, (except for mild hypertension). Normal radiological findings before and after the regression of clinical symptoms, as well as regression of the observed changes after the withdrawal of ATRA and institution of standard treatment (corticosteroids) allow to exclude pulmonary abnormalities due to the myeloproliferative process.

## Conclusions

In view of lack of radiological features specific for ATRAS, changes of chest X-ray pictures in AML patients treated with ATRA require interpretation in clinical context.

## References:

1. Frankel SR, Eardley A, Lauwers G et al. The "retinoic acid syndrome" in acute promyelocytic leukemia. *Ann Intern Med* 1992; 117: 292-6.
2. Lee-Chiong T, Matthay RA. Drug-induced pulmonary edema and acute respiratory distress syndrome. *Clin Chest Med* 2004; 25: 95-104.
3. Larson RS, Tallman MS. Retinoic acid syndrome: manifestations, pathogenesis, and treatment. *Best Pract Res Clin Haematol* 2003; 16: 453-61.
4. Dubois C, Schlageter MH, de Gentile A et al. Modulation of IL-8 and IL-1 beta and G-CSF secretion by all-trans retinoic acid in acute promyelocytic leukemia. *Leukemia* 1994; 8: 1750-7.
5. Dubois C, Schlageter MH, de Gentile A et al. Hematopoietic growth factor expression and ATRA sensitivity in acute promyelocytic blast cells. *Blood* 1994; 83: 3264-70.
6. de Gentile A, Toubert ME, Dubois C et al. Induction of high-affinity GM-CSF receptors during all-trans retinoic acid treatment of acute promyelocytic leukemia. *Leukemia* 1994; 8: 1758-62.
7. Jung IJ, Choi JE, Hahn ST et al. Radiologic features of all-trans-retinoic acid syndrome. *Am J Roentgenol* 2002; 178: 475-80.
8. Itoh Y, Ohyashiki K, Ohtaka M et al. All-trans-retinoic acid induced enrichment of functionally normal neutrophils in vivo in a patient with acute promyelocytic leukemia. *Leukemia* 1992; 6: 806-8.
9. Frankel SR. Neutrophil function following therapy for acute promyelocytic leukemia. *Leukemia* 1993; 7: 1478-9.
10. Datta D, Gerardi DA. Retinoic acid syndrome. *Conn Med* 2003; 67: 541-3.
11. Tallman MS. New agents for the treatment of acute myeloid leukemia. *Best Pract Res Clin Haematol* 2006; 19: 311-20.
12. Islam MU, Bumey IA, Khurshid M. Retinoic acid syndrome – radiologic features. *Acta Radiologica* 1997; 38: 340.
13. Limper AH. Chemotherapy-induced lung disease. *Clin Chest Med* 2004; 25: 53-64.
14. Lester WA, Hull RD, Fegan CD et al. Respiratory failure during induction chemotherapy for acute myelomonocytic leukaemia (FAB M4Eo) with ara-C and all-trans retinoic acid. *Br J Haematol*. 2000 Jun; 109: 847-50.
15. De Botton S, Dombret H, Sanz M et al. Incidence, clinical features, and outcome of all-trans-retinoic acid syndrome in 413 cases of newly diagnosed acute promyelocytic leukemia. *Blood* 1998; 92: 2712-8.
16. Kawasaki K, Akaike H, Miyauchi A et al. Sivelestat relieves respiratory distress refractory to dexamethasone in all-trans retinoic acid syndrome: a report of two cases. *Eur J Haematol* 2006; 77: 448-52.
17. Avvisati G, Tallman MS. All-trans retinoic acid in acute promyelocytic leukaemia. *Best Pract Res Clin Haematol* 2003; 16: 419-32.
18. Raanani P, Segal E, Itai L et al. Diffuse alveolar hemorrhage in acute promyelocytic leukemia patients treated with ATRA – A manifestation of the basic disease or the treatment. *Leuk Lymphoma* 2000; 37: 605-10.
19. Nicolls MR, Terada LS, Tuder RM et al. Diffuse alveolar hemorrhage with underlying pulmonary capillaritis in the retinoic acid syndrome. *Am J Respir Crit Care Med* 1998; 158: 1302-5.