

Received: 2007.11.07  
Accepted: 2008.05.20

## Synchronous colon and renal cancer – case report

Elżbieta Łuczyńska, Tomasz Pawlik, Joanna Anioł, Anna Chwalibóg

Department of Diagnostic Imaging, Maria Skłodowska-Curie Memorial Cancer Center and Institute of Oncology, Cracow Branch, Cracow, Poland

**Author's address:** Elżbieta Łuczyńska, Department of Diagnostic Imaging, Maria Skłodowska-Curie Memorial Cancer Center and Institute of Oncology, Cracow Branch, ul. Garncarska 11, 31-115 Cracow, Poland, e-mail: dgn.ela@interia.pl

### Summary

**Background:**

Primary cancer may occur synchronously in two different organs.

We present an example of pathologically proven, coexistent renal and colony double malignant tumors.

**Case Report:**

A 59 year old man, was admitted to the Institute of Oncology due to left renal lesion, discovered during a routine abdominal ultrasound examination. The CT exam was performed before surgery. The CT scans reveled a second abnormality, presenting irregular shaped and thickened to 20 mm intestinal wall within a patient's large bowel. As a next diagnostic step a CT-colonoscopy was undertaken, which confirmed the presence of an exophytic sigmoid lesion, eccentrically affecting the colonic wall and protruding into the lumen moderately narrowing it, placed about 50 cm from the external rectal sphincter.

Patient underwent simultaneous radical left nephrectomy and sigmoidectomy. Both tumors were confirmed in pathologic evaluation, reveling renal clear cell carcinoma (Fuhrman G II) and colonic adenocarcinoma (Astler-Coller B2).

**Conclusions:**

Preoperative careful imaging studies reveled neoplastic tumors in two different organs, allowing for radical resection at the same surgical procedure.

**Key words:**

renal cancer • colon cancer • virtual colonoscopy

**PDF file:**

<http://www.polradiol.com/fulltxt.php?ICID=866885>

### Background

Primary cancer may occur synchronously in two different organs.

We present an example of pathologically proven, coexistent renal and colonic double malignant tumors. In the case reported here, a kidney lesion was discovered first, both tumors were asymptomatic and possibility of one carcinoma being a metastasis of the other was excluded.

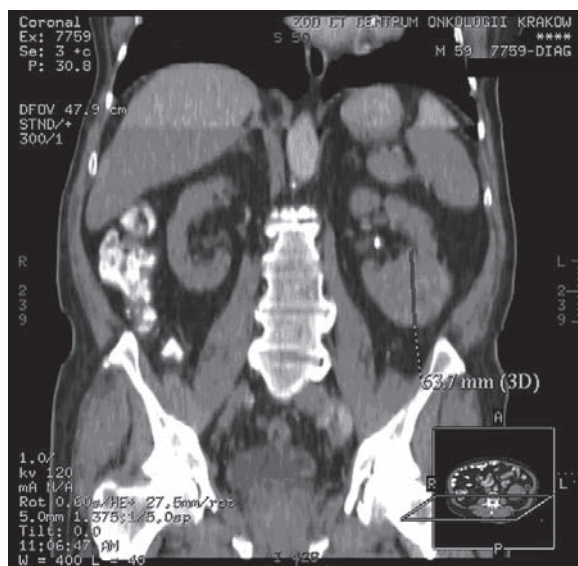
### Case Report

A 59year old man, admitted to the Institute of Oncology due to left renal lesion, discovered during a routine abdominal ultrasound examination. The results have shown 7×6 cm hypoechogenic solid tumor, situated around lower pole of left kidney, composed of extended pathological vascular system and multiple calcifications.

Physical examination and laboratory data were irrelevant.

In order to determine the extent of neoplasmatic process, an abdominopelvic CT scan was performed, using a Light Speed GE helical scanner. As a patient preparation, an oral contrast was given one day in advance and additionally 30 min prior to examination. An intravenous contrast (60 ml) was administrated by means of a power injector with a speed 3 ml/sec.

The study timed to be performed at all phases of contrast enhancement, demonstrated heterogeneous, well-circumscribed 6.5cm mass, located in the left inferior renal pole (Figure 1). The tumor has markedly distorted a normal calyx structure and protruded into the renal pelvis cavity. In front of the mass a barely thickened renal fasciae was visible, but there was no clear evidence of contiguity infiltration towards descending colon. The contours of renal



**Figure 1.** Abdominal CT. Tumor of the lower pole of the left kidney.

peduncle were preserved. The lesion manifested as very well vascularised, having a strong arterial phase contrast media enhancement, with imaging pictures being indicative of renal carcinoma.

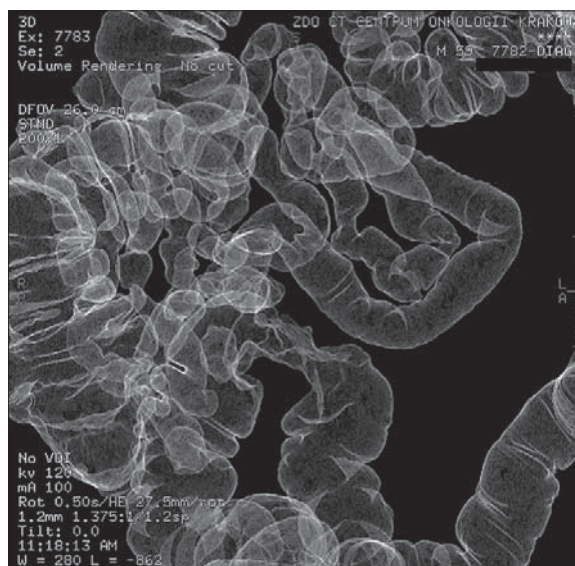
Additional findings included a calcified concrement situated in renal pelvis, together with multiple simple cortical cysts seizing up to 20 mm. No lesions were imaged with regard to right kidney. The CT scans revealed a second abnormality, presenting irregular shaped and thickened to 20 mm intestinal wall within a patient's large bowel. A pericolic fat tissue around enlarged wall was obliterated. The CT pictures suggested coexistent large bowel malignant tumor. All other abdominopelvic organs did not present any pathological changes and metastatic workups were negative.

As a next diagnostic step a colonoscopy was undertaken, which confirmed the presence of an exophytic sigmoid lesion, eccentrically affecting the colonic wall and protruding into the lumen moderately narrowing it, placed about 50 cm from the external rectal sphincter.

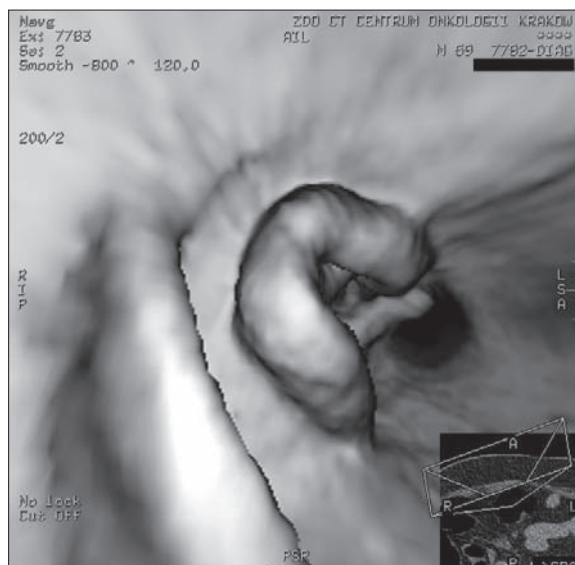In order to exclude all other eventual large bowel lesions, being placed beyond colonoscope's range capability, the patient was qualified for virtual CT-colonoscopy.

That exam was performed after careful intestines preparation (cleaning using Fleet). The colon was distended by air till the final part of the small bowel. Patient was examined in both prone and supine position using following technical parameters: collimation 5 mm, reconstruction intervals 1.25 mm, pitch 1.0. The whole data was afterwards processed in accordance with GE application protocol. The final film has shown, the 6cm long sigmoid mass (Figures 2,3), as well as a 12mm rectal polypus, with no other potentially malignant abnormalities.

Patient underwent simultaneous radical left nephrectomy and sigmoidectomy. Both tumors were confirmed in pathologic evaluation, revealing renal clear cell carcinoma (Fuhrman G II) and colonic adenocarcinoma (Astler-Coller B2).



**Figure 2.** Virtual colonoscopy. Irregular lesion narrowing lumen of the colon.



**Figure 3.** Virtual colonoscopy. Tumor inside the lumen of the colon.

## Discussion

Primary cancer may occur synchronously at two different organs of abdominal cavity.

A steady accumulated data shows a strong association of a renal carcinoma with multiple malignancies. According to O'Boyle & Kemeny, a 29% of the patients with kidney tumor at autopsy had another primary, making it the most common type of cancer associated with multiple neoplastic lesions of other organs [1]. On the other hand, in 9% of the patients with a colon cancer, there was another, second primary malignant finding at autopsy. Depending on medical center providing statistics on this subject, incidence of simultaneous colon and renal tumors reaches from 3.8 to 7.4%.

Renal carcinomas are often completely asymptomatic, being discovered only by chance on CT scans, done to stage

the extent of the patients' tumor, or to follow up on their colon cancer. Since they often remain silent and clinically unrecognized, it makes colon adenocarcinoma usually the primary tumor found first, and also the most frequent cause of death among this patients [2].

Although it's rare colon cancer can metastatize to the kidney and renal carcinoma is reported to give secondaries to the colon [3]. The correct recognition of these findings is critically important, since solitary recurrence of renal cell carcinoma is not always associated with a poor prognosis and surgical resection of the recurrent tumor, has been reported, to give a long-term survival. This situation was,

however excluded in our case, with histologic data proving clearly simultaneous colon and renal primaries [4].

## Conclusions

In conclusion, the relatively high incidence of synchronous renal and colonic carcinomas, recommend a routine use of preoperative imaging studies, to rule out coexistent, asymptomatic kidney malignant lesion in patients with colorectal cancer, as it may impact on the further management of these patients. In such cases staged renal and colon surgeries are sometimes performed, but simultaneous resection is recommended if possible.

## References:

1. O'Boyle KP, Kemeny N. Synchronous Colon and Renal Cancers: Six Cases of a Clinical Entity. *Am J Med*, 1989; 87(6): 691-93
2. Napolitano C, Santoro GA, Valvano L et al: Simultaneous Totally Laparoscopic Radical Nephrectomy and Laparoscopic Left Hemicolectomy for Synchronous Renal and Sigmoid Colon Carcinoma. *Int J Colorectal Dis*. 2006; 21: 92-93
3. Diaz-Candamio MJ, Pombo S, Pombo F: Colonic Metastasis from Renal Cell Carcinoma: Helical-CT Demonstration. *European Radiology*; 2000; 10: 139-40
4. Kim SH, Park JY, Joh YG: Simultaneous Laparoscopic Radical Nephrectomy and Laparoscopic Sigmoidectomy for Synchronous Renal Cell Carcinoma and Colonic Adenocarcinoma. *J J Laparoendosc Adv Surg Tech A*, 2004; 14(3): 179-81