

Received: 2008.03.06

Accepted: 2008.06.25

Rapid progression of massive hepatic calcification visible by CT: The case of a dialyzed patient

Tomasz Gorycki¹, Arkadiusz Szarmach², Jacek Kot³, Anna Szymańska-Dubowik², Anna Szostak⁴

¹ Department of Imaging Diagnostics, Academic Center of Maritime and Tropical Medicine, Gdynia, Poland

² Department of Radiology, Medical University of Gdańsk, Poland

³ Department of Hyperbaric Medicine, Academic Centre of Maritime and Tropical Medicine, Gdynia, Poland

⁴ Department of Radiology, Specialist Hospital, Gdańsk-Zaspa, Poland

Author's address: Tomasz Gorycki, Department of Imaging Diagnostics, Academic Center of Maritime and Tropical Medicine in Gdynia, ul. Powstania Styczniowego 9B, Gdynia, Poland, e-mail: tgor@acmmmit.gdynia.pl

Summary

Background:

There have been single reported cases of patients with diffuse hepatic calcifications revealed 4–36 months after the first examination in the course of hemodialysis-treated renal failure, severe heart failure, shock liver, primary amyloidosis, or corticosteroid administration. In the presented case, many different factors for liver calcification and dynamic tomographic manifestation are seen.

Case Report:

A 23-year-old man who was on hemodialysis because of acute renal failure after a motor vehicle accident (multiorgan trauma) with occurrence of hypovolemic shock was admitted to the hospital's intensive care unit presenting with clostridial infection of the lower extremities. During his stay at a prior hospital, ultrasonography did not reveal hepatic lesions. He underwent 22 sessions of treatment with hyperbaric oxygen as well as several necrectomies and amputation of both lower limbs. Abdominal CT performed three weeks after the accident demonstrated diffuse hepatic calcification which was later confirmed during autopsy. Liver parenchymal calcifications may be related to elevated calcium-phosphorus products in the uremic state and after multiple bone fractures and possible ischemic liver injury. Although a definitive explanation for the unusually short time of the appearance of liver calcification was not obtained, it may be related to many factors acting synergistically. Hyperbaric oxygen treatment is of unknown significance in this process.

Conclusions:

CT plays a basic role in detecting and assessing liver calcifications forming both diffuse lesions and those with well-defined borders. Diffuse calcifications revealed by CT must be analyzed together with the patient's history, especially considering renal and heart failure, bone fractures, states of shock, and treatment. Diffuse liver calcifications in these patients after respiratory therapy and transfusions when no subcapsular hematoma is found should be considered of metabolic origin.

Key words:

diffuse liver calcification • CT imaging • shock liver

PDF file:

<http://www.polradiol.com/fulltxt.php?ICID=866881>

Background

Of all the numerous causes of diffuse hepatic calcification, those in the course of renal failure, liver parenchymal ischemia, and multiorgan trauma, especially with multiple bone injuries, appear rarely. Systemic calciphylaxis in these cases is usually detected after several months of observation by imaging methods. The case of hepatic calcification presented here is characterized not only by different etio-

logical factors, but also by a dynamic increase in lesions seldom described in the literature.

Case Report

A 23-year-old patient in a serious state, with no contact, intubated, and mechanically ventilated, was admitted to the Intensive Care Unit of the Academic Center of Maritime and Tropical Medicine of the Public Clinical Hospital of

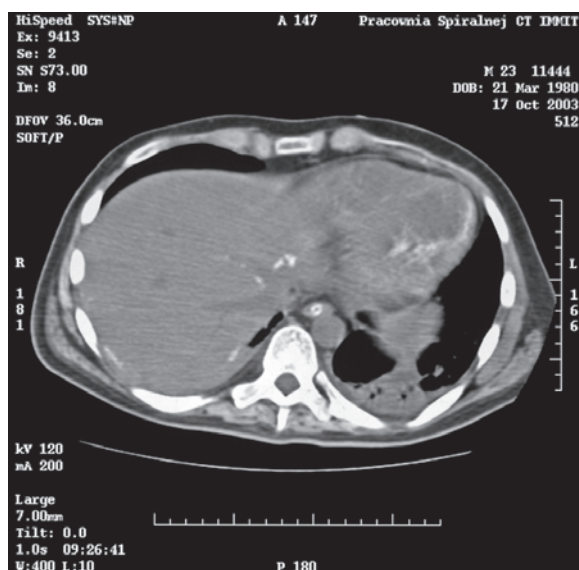


Figure 1. Linear areas of calcifications in the region of the confluence of the systemic veins.

the Medical University of Gdańsk to undergo sessions of treatment with hyperbaric oxygen because of clinical and bacteriological features of clostridial infection. Two weeks before, he had suffered from multiorgan trauma in a traffic accident, with open fracture of the right femur with features of ischemia of the limb, open fracture of the right humerus, fracture of the bones of the left shank, and fracture of bones of the left metacarpus. Ultrasonographic examination after the accident had not revealed any abnormalities in the liver parenchyma. At the Specialist Hospital in Gdańsk-Zaspa the patient underwent operations to reposition the right femur and right humerus, thrombendarterectomy of the right femoral artery, right shank fasciotomy, and, after admission to the Academic Center of Maritime and Tropical Medicine, also necrectomy of the right upper limb and several necrectomies of the left shank, hand, arm, and forearm, exarticulation in the right coxofemoral joint because of persistent bleeding, and left femoral amputation because of clinical and bacteriological features of clostridial acral gangrene. During his stay at both hospitals the patient was dialyzed because of acute renal failure. During his treatment in the Academic Centre of Maritime and Tropical Medicine, acute respiratory failure with the beginnings of multiorgan insufficiency, bilateral pneumonia, liver failure, and disseminated intravascular coagulation was diagnosed. The patient underwent complete treatment with hyperbaric oxygen at a pressure of 2.5 Atm in 22 sessions in a hyperbaric chamber.

Coagulation disturbances and bleeding from wounds caused massive transfusions of blood preparations. There was continuous respiratory therapy and daily dialysis as well as supplementation of proteins and parenteral nutrition. The patient also had chest radiograms taken at bedside in which some inflammatory lesions were found in the bases of the lungs, more on the right side, which partly made both hemi-diaphragms hazy, with different intensity of stasis in pulmonary circulation, and the location of the venous catheter and endotracheal tube were also checked.

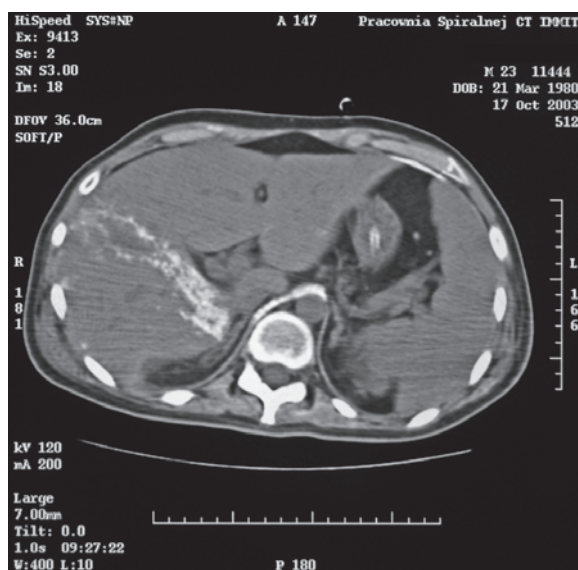


Figure 2. CT performed 3 weeks after the accident demonstrated diffuse hepatic calcification. Calcified right diaphragm crus is also revealed.

Abdominal CT including the lower parts of the lungs revealed some calcification in the heart, especially in structures of the valvular ring, interventricular septum, the free wall of the left ventricle, and in the papillary muscles of the left ventricle. Atelectasis and inflammatory lesions were seen in pulmonary segments 9 and 10 of both lungs, with domination of the right side. Massive fascicular hyperdense areas which included all of section V of the right segment of the liver with a length of 11 cm and width of 2.5 cm reached the site of the gall bladder, presenting densities measured with an oval-shaped region-of-interest (ROI) in the range between 60–150 HU on native pictures (Figure 1). Because of trauma in anamnesis and the possibility of the interaction of different factors in producing the picture of hyperdense lesions with heterogeneous infiltrative character in segment V in the differential diagnosis (except for calcifications), attention was given to the possibility of distant posttraumatic lesions in the mechanism of cumulative microtrauma of the hepatic parenchyma and to determining the influence of other processes connected with the intensive treatment. Smaller linear hyperdense areas were also observed in the liver parenchyma in the region of confluence of the systemic veins into the inferior caval vein (Figure 2). There was also a massive infiltration with the presence of gas bubbles in the perivesical region. Calcifications (150–250 HU) were in the crura of the diaphragm. The remaining organs of the abdomen and pelvis revealed a lack of abnormalities in CT examination.

After 11 days of stay at the Academic Centre of Maritime and Tropical Medicine and completed treatment in the hyperbaric chambers, the patient was moved to the Intensive Care Unit of the Specialist Hospital in Gdańsk-Zaspa for surgery there and to consider indications for repeating the hyperbaric oxygen therapy. Unfortunately, in spite of the intensive treatment with symptoms of intensification of multiorgan insufficiency, the patient died 14 days later.

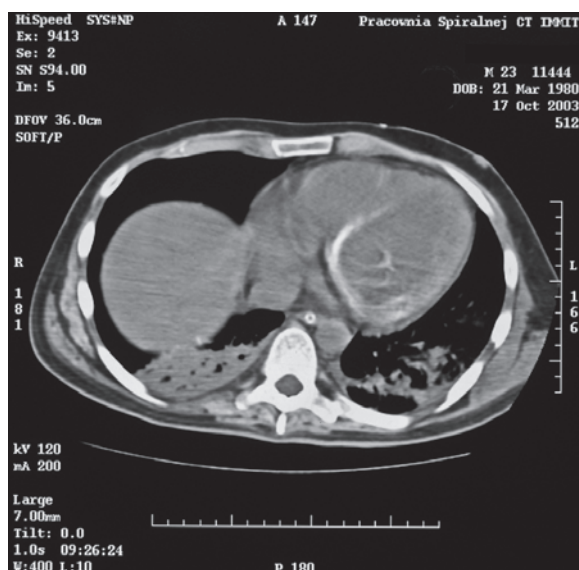


Figure 3. Myocardial calcifications, atelectasis, and inflammatory lesions in the basal pulmonary segments.

Discussion

Analysis of the imaging examinations of the abdomen performed in this case showed four types of lesions found. The first group consisted of irregular hyperdense areas located fascicularly in the transversal surface of the right segment of the liver and some which were smaller capsular and subcapsular and in the region of the confluence of the hepatic veins. The second group of lesions were calcifications of the myocardium of the free wall and septum of the left ventricle and in the projection of the papillary muscles (Figure 3).

The third group were atelectatic and inflammatory lesions in the bases of the lungs, which are often found in lying patients after multiorgan injuries in which, besides immobilization, difficulties with evacuation of secretion from the respiratory tract and adjunctive respiration, segmental contusion of the lung parenchyma can also be important. The fourth group concerned hematoma and inflammatory infiltration in the pelvis located at the height of the bone fractures of the pelvic girdle.

Irregular calcifications of the liver parenchyma appearing over several months or several years of observation in patients with renal failure treated with hemodialysis and peritoneal dialysis, having had transfusions of many blood products, are rarely presented in the literature. In this case the most important fact is that the calcifying lesions appeared during a short time of observation. On the one hand, this can happen because of many different factors appearing synergistically, such as renal failure treated by hemodialysis, transfusions, respiratory therapy, multiorgan trauma with numerous bone fractures, and surgical operations of necrectomies and limb amputations. It is hard to assess the influence of high-pressure oxygen treatment, as this factor has not been reported in the literature so far. On the other hand, the rapid appearance of fascicular hyperdense areas needed differentiation from liver parenchymal damage in a delayed mechanism.

Diffuse liver calcifications after respiratory therapy and transfusions in a patient with renal failure when no subcapsular hematoma has been noted should be considered to be of metabolic origin. Calcifications of the pericardial sac and myocardium were described together with renal failure [1,2]. In the present case we can assume that they were caused by the same factors as those responsible for lesions in liver.

Also described in the literature were chronic renal failure treated with hemodialysis together with the appearance of 48 hours of shock caused by ventricular tachycardia and bleeding from the upper part of digestive tract. After this incident, an increase in blood transaminase was observed. After four months, some small diffuse calcifications in areas of the degenerative lesions were found. Their appearance was connected with an intracellular calcium homeostasis disorder as an effect of liver parenchymal ischemia or may have been related to elevated calcium-phosphorus products in the uremic state [3]. Some tiny diffuse calcifications were found in areas of degenerative lesions in the liver parenchyma in patients with renal disorder and heart insufficiency. Their appearance is an effect of intracellular calcium homeostasis disorder as a result of liver parenchymal ischemia or may be related to the elevated calcium-phosphorus products in the course of the hyperparathyroidism which accompanies renal insufficiency [4]. More often in some cases of calcifications in hepatic parenchyma in the course of amyloidosis, renal insufficiency was also found [5]. Another factor responsible for systemic calciphylaxis including liver parenchyma in the course of renal disorder and secondary hyperparathyroidism are incidents of bone fracture [1]. Sugiura described a case of centrilobular, differently shaped calcifications of the liver parenchyma in a female patient five months after she had had a four-hour-long incident of hypovolemic shock in the course of massive hemorrhage from a dialysis shunt vein [6].

The term "shock liver" refers to an inflammatory reaction which is the result of ischemic damage, usually in course of cardiogenic shock or hypovolemia, with an increase in transaminase as a result of liver cell damage, usually without any clinical symptoms or, rarely, with symptoms similar to those of viral hepatitis. It is usually a self-limiting process without any important clinical consequences. Liver parenchymal ischemia in patients with renal insufficiency treated with hemodialysis after trauma incidents with bone fractures is a chase where the risk factors result in differently formed and shaped calcifications [7]. Calcifications of the pericardium and myocardium were reported in patients with renal failure who were treated with hemodialysis as well as peritoneal dialysis [8]. Systemic calciphylaxis was reported in patients with chronic renal failure while undergoing dialysis therapy, but with no evidence of noticeable hyperparathyroidism. In this group the administration of corticosteroids might act synergistically to cause calciphylaxis [9].

It seems that the most important factor for the occurrence of liver calcifications is evidence of calcium-phosphorus homeostasis disorder in the course of renal failure and after shock, where there is a decrease in liver

parenchymal perfusion. Other factors that act synergistically might determine the rapidity and range of lesions [9]. Circulatory disorders together with gas gangrene may manifest with ischemic necrosis [2]. In the case of ischemic necrosis, reports of calciphylaxis are not rare. We cannot deny the importance of increased oxygen pressure on metabolic lesions in the damaged area of the liver and in the surroundings, which also can promote calciphylaxis, although no information about this is reported in the literature.

References:

1. Varma DG, Murayama S, Etheredge E: Computed tomography demonstration of unusual diffuse metastatic calcification secondary to renal failure. *J Comput Tomogr*, 1988; 12(4): 282-86
2. Tamura M, Hiroshige K, Osajima A: A dialysis patient with systemic calciphylaxis exhibiting rapidly progressive visceral ischemia and acral gangrene. *Intern Med*, 1995; 34(9): 908-12
3. Shibuya A, Unuma T, Sugimoto T: Diffuse hepatic calcification as a sequela to shock liver. *Gastroenterology*, 1985; 89(1): 196-201
4. Milstein MJ, Moulton JS: Diffuse hepatic calcification after ischemic liver injury in a patient with chronic renal failure. *AJR Am J Roentgenol*, 1993; 161(1): 75-76
5. Evans C, Kennan NM: Case report: hepatic and splenic calcification due to amyloid. *Clin Radiol*, 1991; 44(1): 60-61
6. Sugiura H, Yoshida K, Nakanuma Y: Hepatic calcification in the course of hemodialysis. *Am J Gastroenterol*, 1987; 82(8): 786-89
7. Giallourakis CC, Rosenberg PM, Friedman LS: The liver in heart failure. *Clin Liver Dis*, 2002; 6(4): 947-67
8. Marcu CB, Caracciolo E, Donohue T: Rapid progression of pericardial calcification in a patient with end-stage renal disease. *Catheter Cardiovasc Interv*, 2005; 65(1): 43-46
9. Milstein MJ, Moulton JS: Diffuse hepatic calcification after ischemic liver injury in a patient with chronic renal failure. *AJR Am J Roentgenol*, 1993; 161(1): 75-76

Conclusions

CT plays a basic role in detecting and assessing liver calcifications forming both diffuse lesions and those with well-defined borders. Diffuse calcifications revealed by CT must be analyzed together with the patient's history, especially considering renal and heart failure, bone fractures, states of shock, and treatment. Diffuse liver calcifications in these patients after respiratory therapy and transfusions when no subcapsular hematoma is found should be considered of metabolic origin.