

Otrzymano: 2008.01.02
Zaakceptowano: 2008.02.28

The value of perfusion CT in evaluating locoregional staging in post-radical prostatectomy patients with elevated serum PSA level

Elżbieta Łuczyńska¹, Joanna Anioł¹, Andrzej Stelmach², Janusz Jaszczyński²

¹ Department of Diagnostic Imaging, Maria Skłodowska-Curie Memorial Cancer Center and Institute of Oncology, Cracow Branch, Poland

² Department of Surgery, Maria Skłodowska-Curie Memorial Cancer Center and Institute of Oncology, Cracow Branch, Poland

Author's address: Elżbieta Łuczyńska, Department of Diagnostic Imaging, Maria Skłodowska-Curie Memorial Cancer Center and Institute of Oncology, Cracow Branch, ul. Garncarska 11, 31-115 Poland, email: dgn.ela@interia.pl

Summary

Background:

The aim of the study was to evaluate the efficiency of perfusion CT (p-CT) in assessing cancer foci in the prostate gland in patients with elevated PSA level who had radical prostatectomy after the p-CT exam.

Material/Methods:

Prostate p-CT was performed at the Oncology Institute, Cracow, in 2006 in 24 patients aged 49-72 years. The examination was followed by core needle biopsy of the prostate (6-12 cores). PSA levels in the blood ranged from 5.15 to 33.1 ng/ml. The Gleason score estimated after radical prostatectomy ranged from 5 to 8. The parameters BF, BV, PS, and MTT for both prostate lobes at three levels (base, mid-gland, and apex) were measured. Relationships between the presence of pathological foci found in p-CT, serum PSA level, and histopathological findings in the removed prostate gland were analyzed.

Results/Conclusions:

On the basis of the analyzed material, positive correlation was found between serum PSA level and Gleason score in the post-radical prostatectomy patients. Positive correlation was also found between serum PSA and the presence of pathological lesions detected in p-CT. The higher the level of serum PSA, the higher the probability of detecting a pathological lesion within the prostate gland. No significant correlation between histopathological and p-CT outcome concordance and serum PSA level was noted. However, no correlation between Gleason score and p-CT examination results was found, which suggests that there is no relationship between Gleason score and presence of pathological foci detected in p-CT examination.

Key words:

prostate • carcinoma • angiogenesis • prostate cancer • perfusion

PDF file:

<http://www.polradiol.com/fulltxt.php?ICID=857100>

Background

Prostate cancer takes the second place among malignant neoplasms in men. Because the disease develops without any symptoms for an extended period of time, early detection by means of additional examinations (biochemistry or diagnostic imaging screening) is of great importance. The course of prostate cancer is poorly symptomatic, while significant general symptoms of cancer, such as anuria, oli-

guria accompanying non-kidney-related kidney failure, ostealgia, and anemia, are indicative of advanced disease. Three modalities exist to reduce cancer-related mortality: reduction of cancer incidence, improvement of therapeutic approaches, and increased early detection. Only the last now appears available for patients with prostate carcinoma.

According to other publications, computed tomography (CT) of the pelvis does not serve as a modality to be utilized for

assessing cancer foci within the prostate, although it was helpful in the general staging of prostate cancer. Due to the development of CT techniques and the introduction of multi-slice CT, perfusion CT (p-CT) became possible. We hypothesized that faster multidetector scanners would provide better dynamic imaging of contrast enhancement and improved detection of prostate cancer. p-CT is of special value in cases where pathological foci in the peripheral prostate zone are not detected by TRUS but the patient's serum PSA level is elevated or when performing MRI is impossible. The aim of the study was to evaluate the efficiency of p-CT in assessing cancer foci within the prostate gland in patients with elevated PSA levels who had radical prostatectomy after the p-CT exam.

Materials and methods

Prostate p-CT was performed at the Cancer Center in Cracow in 2006 in 24 patients. The examination was performed before prostate core biopsy. The ages of the patients ranged from 49 to 72 years, with a mean of 63 years. In the evaluated group, serum PSA ranged from 5.15 to 33.1 ng/ml. p-CT was performed with a 16-slice CT scanner (Light Speed, GE Medical Systems). The perfusion level was measured during a baseline scan of the minor pelvis without administration of contrast and the perfusion zone was outlined. Fifty ml of non-ionic contrast medium with a density of 370 mgI/dl was administered using a pressure injector at the rate 5 ml/sec. Perfusion was measured using the repeated dynamic scans technique. The scans were started at a delay of 5-7 sec following the beginning of contrast injection. The total time of a complete examination from contrast injection was about 50 sec. The thickness of the slice was 1.25 mm.

In order to perform quantitative analysis, the prostate was evenly divided in the craniocaudal dimension into three segments, i.e. the base, mid-gland, and apex. The area of maximum perfusion was identified at each of these three levels on both sides of the prostate for a total of six areas. A region of interest (ROI) was drawn around each of these areas, taking care to avoid central areas of periurethral flow or obvious benign prostate hyperplasia. A total number of ROIs were defined in the areas of maximum perfusion along the periphery of each prostate gland. Local perfusion within each ROI was then estimated from the maximum slope of enhancement.

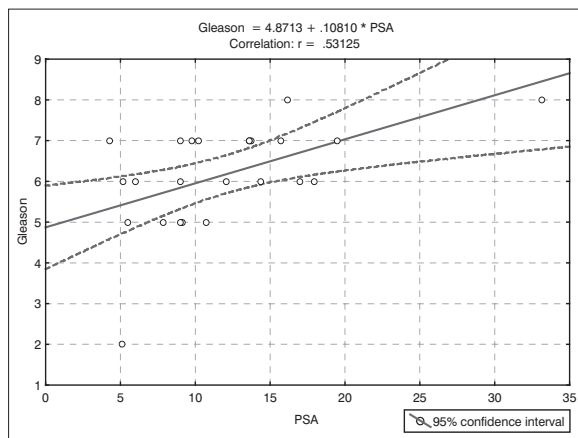


Figure 1. Correlation between serum PSA level and Gleason score.

On completion of the study, the data were transferred to an image processing workstation (Advantage Workstation) and analyzed by CT Perfusion 3 software (GE Medical Systems). The following parameters were measured:

1. blood flow (BF), the volume of blood flowing within a specific time through a specific area. As a reference point we assumed 200 ml/100 g/min.
2. blood volume (BV), the total amount of blood within the vasculature of a specific area. As a reference point we assumed 40 ml/100 g.
3. permeability surface (PS) estimates the permeability of the vessels for contrast media flowing from the endovascular to extravascular area. As a reference point we assumed 10 ml/100 g/min.
4. mean transit time (MTT), the mean time of blood flow through a tissue, given in seconds; as a reference point we assumed 10 s.

Perfusion CT was used to assess the presence or lack of pathological foci in the peripheral zone at three levels in every patient. In case of the presence of foci in the peripheral zone, their number and location, i.e. whether in one or both lobes, were estimated (Fig. 5).

Following radical prostatectomy, whole-mount prostatectomy specimens were processed and stained with hematoxylin and eosin. Then slides were produced by step section of the gland from the apex to the base, every 5 mm. Then the number and location of the foci in the prostate gland seen in p-CT were compared with their number and location in the histopathological findings. Statistical correlation between the p-CT results and histological data and between serum PSA level and Gleason score were performed with Pearson's correlation coefficient. When reporting these results we considered a correlation coefficient >0.3 as evidence of a positive association.

Results

Prostate adenocarcinoma was present in all the patients, but there was one patient who demonstrated a mucinous variant of adenocarcinoma. All the patients demonstrated

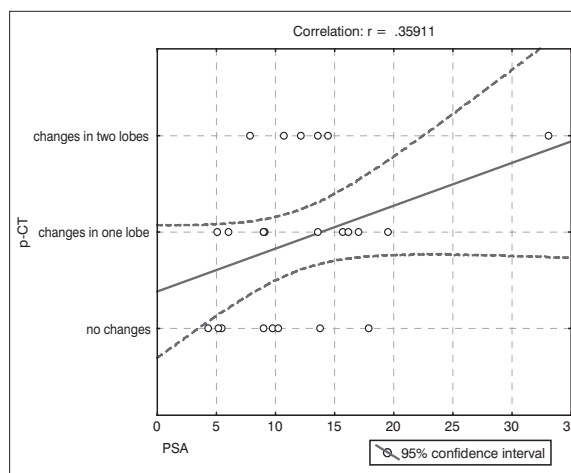


Figure 2. Correlation between serum PSA and presence of cancer foci detected by p-CT.

Table 1. Correlation between PSA level in blood serum, Gleason score, p-CT results and histopathological findings in patients post prostatectomy.

Patient no.	PSA	Highest Gleason score	Histopathological findings post-prostatectomy	p-CT
1	10.7	5	I	I
2	13.7	7	I	IV
3	5.11	2	III	III
4	9.78	7	I	IV
5	17.93	6	I	IV
6	9.12	5	I	III
7	12.1	6	I	I
8	10.2	7	I	IV
9	33.1	8	I	I
10	5.48	5	I	IV
11	14.4	6	I	I
12	4.29	7	I	IV
13	9.0	7	II	II
14	9.01	5	I	III
15	17.0	6	II	II
16	15.69	7	I	III
17	6.01	6	I	II
18	16.17	8	I	I
19	13.6	7	I	II
20	9.02	6	I	IV
21	7.84	5	I	I
22	5.17	6	II	IV
23	13.6	7	I	I
24	19.5	7	III	III

I – findings demonstrated in both lobes of the prostate, II – findings only in the right lobe, III – findings only in the left lobe, IV – no lesions within prostate detected.

enhancement of the prostate, with obvious enhancement of the periurethral tissue. Many patients also demonstrated enhancement of the hypertrophied inner gland tissue on either side of the urethra.

Histopathological examination of the resected prostate revealed Gleason scores ranging from 5 to 8 (grade 5 in two patients, grade 8 in 3 patients, and grades 6 or 7 in the others). Table 1 presents a comparison of serum PSA level and Gleason score from histopathological examination and the presence of cancer foci in the histopathological examination and p-CT. As we can see, p-CT revealed the presence of pathological foci in the peripheral zone in one lobe only in 9 patients, in 7 patients the foci were located in both lobes, and no foci were detected in 8 patients.

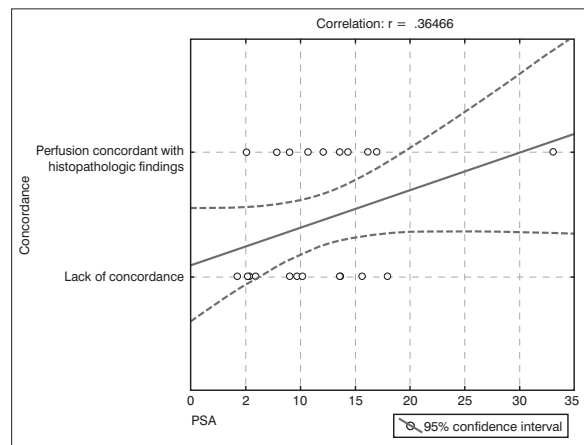


Figure 3. Correlation between serum PSA level and concordance of histopathologic findings with p-CT results.

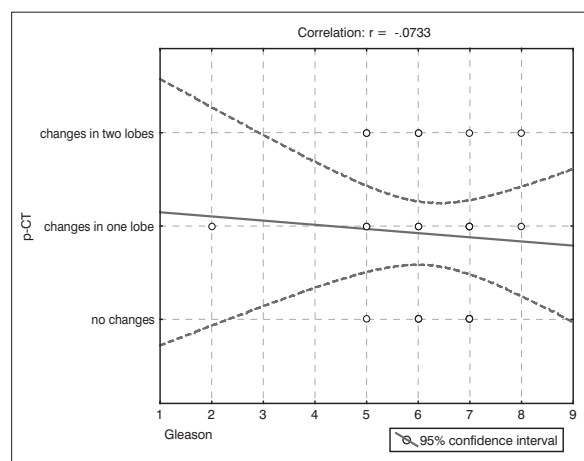


Figure 4. Correlation between Gleason score and presence of cancer foci detected in p-CT examination.

Histopathological examination after resection of the prostate proved 19 cases of cancer localized in both lobes and 5 cases of localization in one lobe. The results of Figure 1 indicate correlation between serum PSA level and Gleason score in patients who underwent radical prostatectomy. The higher the serum PSA level, the higher the Gleason score (Fig. 1). This correlation was statistically significant ($p=0.008$). Figure 2 presents the correlation between serum PSA and the presence of cancer foci detected in the p-CT examination. From this we can conclude a positive correlation between serum PSA level and the presence of cancer foci detected by p-CT. The higher the serum PSA level, the higher the probability of detecting a cancer focus within the prostate gland. Figure 3 presents the correlation between serum PSA level and concordance between histopathological findings and p-CT results. We can conclude the existence of an average correlation between the concordance of histopathological findings with p-CT results and serum PSA level. Figure 4 presents the relationship between Gleason score in patients after radical prostatectomy and their serum PSA level, demonstrating no correlation between the analyzed data, which suggests that there is no correlation between Gleason score and the presence of pathological foci detected by p-CT.

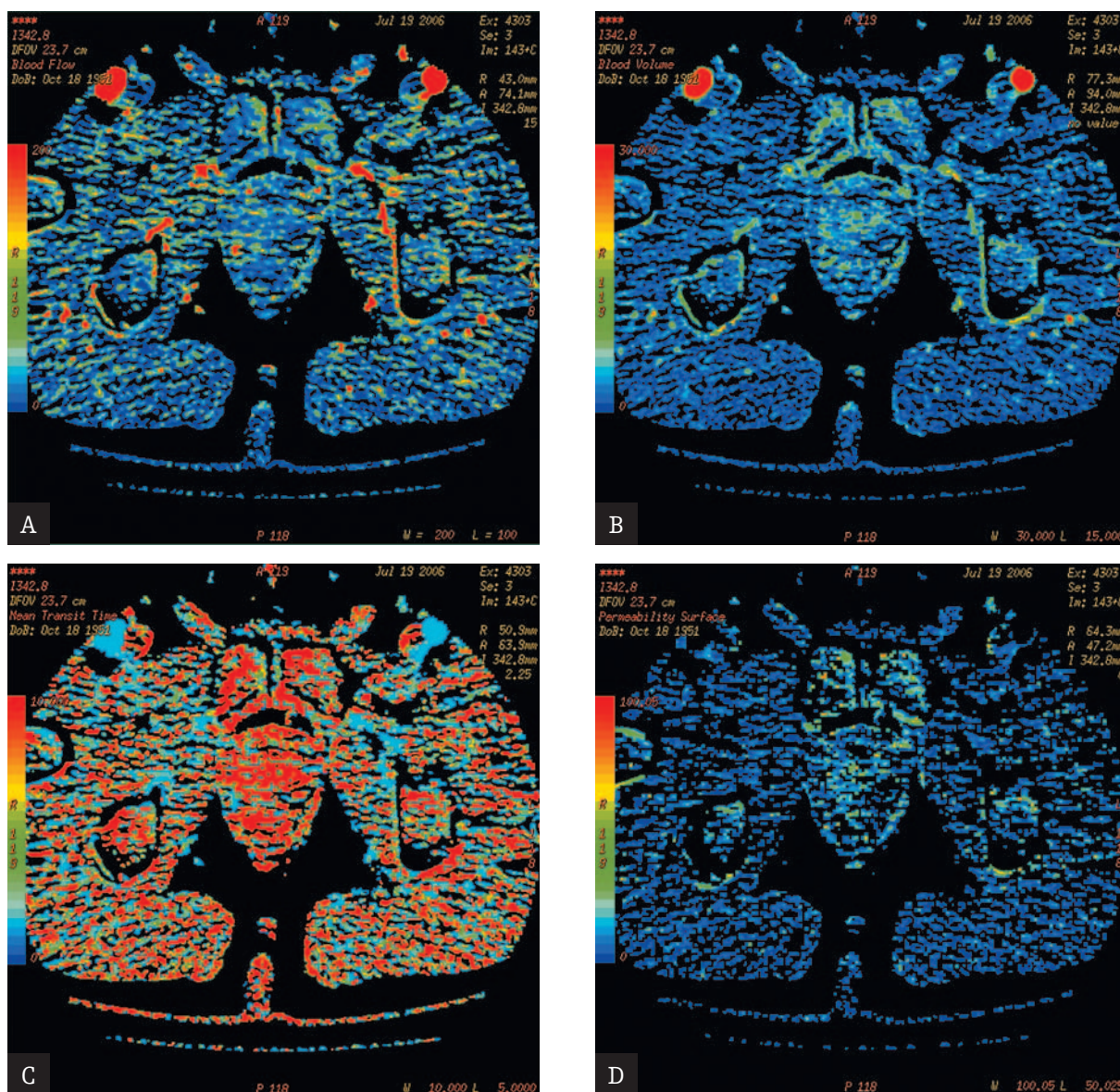


Figure 5. Prostate p-CT, parametric maps of: **A.** Blood Flow, **B.** Blood Volume, **C.** Mean Transit Time, and **D.** Permeability Surface Focal pathological perfusion in the peripheral part of the right lobe.

Discussion

Computed tomography was not indicated for locoregional prostate cancer staging due to its lack of efficiency in assessing cancer foci within the gland; also, its zonal structure and anatomical capsule were poorly visible. What is more, the accuracy of CT in assessing neoplasm infiltration beyond the organ is low. It is stated in literature that the accuracy of CT in assessing periprostate fat tissue infiltration is 24% and seminal vesicle infiltration 65%. According to literature, CT is performed when a patient's serum PSA level is over 20 ng/ml and Gleason score is 8-10 [3]. To our knowledge there has been only one study to evaluate contrast-enhanced computed tomography for the detection of prostate cancer. The study successfully identified the presence of prostate cancer using a single-detector helical scanner. We hypothesized that faster multidetector scanners would provide better dynamic imaging of contrast enhance-

ment and improved detection of prostate cancer. Perfusion CT is a technique that can be readily incorporated into existing CT protocols. The technique allows visualizing the vascularity of the prostate and it seems it will soon become an *in vivo* marker of tumor angiogenesis.

Normal prostatic tissue has a regular orientation of the microvessels along the basement membrane. Adenocarcinoma of the prostate shows an increased proliferation of microvessels as well as abnormalities in the size, shape, and structure of these vessels [4]. In benign tissue the capillaries are uniform in size and diameter. In contrast, carcinoma capillaries vary in size and cross-sectional shape. The diameter of their lumen is very small. The endothelial cells are immunoreactive [5, 6, 7].

Pathologic neoangiogenesis, the formation of a large number of new, imperfect capillaries (characterized by increased

permeability) within the gland, is highly associated with tumor outgrowth. Few imaging methods allow for tumor-associated vasculature assessment, these being TRUS integrated with color Doppler mode, p-CT, and the visualization of parenchymatous organs with some radionuclide methods. Since cancer capillary lumens vary from 2-5 μm , the traditional imaging method is not useful in neoangiogenesis visualization [8, 9, 10, 11]. Functional screening such as p-CT provides the opportunity to assess vascular overgrowth through the presentation of increased BF and BV values. Imperfect function of these vessels means pathologically increased permeability within the specific area, which indicates malignancy. Together with the increase in permeability, the values of PS are also elevated. Perfusion CT provides an opportunity to estimate the mean transit time of blood flow through the tumor (MTT). If a short transit time is demonstrated, which means a decreased MTT value, the flow through the investigated area is fast and indicates its pathological vascularization [12, 13, 14, 15, 16]. Prostate carcinomas are generally not considered to be very vascularized tumors. In the present investigation we wanted to determine whether there were quantifiable differences in vascularity between carcinoma of the prostate and benign prostatic tissue.

The Gleason scores in the presented group varied from 5 to 8. According to reports there is a correlation between tumor malignancy grade (Gleason score) and foci visible in p-CT;

however, this was not confirmed in the present study. We found significant correlation between serum PSA level and malignancy grade in the investigated group. There was also positive correlation between serum PSA level and the presence of foci found by p-CT. We also noted average correlation with serum PSA in patients who had demonstrated concordance between histopathological examination and the presence of foci in p-CT. We did not find any correlation between tumor grade and the presence of foci in p-CT within the prostate. This fact could result from differences in the patient group: there were no surgically treated patients in our population of 24 subjects with very high Gleason scores (>8), which indicates a high-grade tumor. Only one subject presented a mucinous variant of adenocarcinoma, but in a previously reported group there were four such cases per 10 patients. We found correlation between serum PSA level and the presence of foci in p-CT in one case. The higher the serum PSA level, the higher the probability of detecting a cancer focus within the prostate gland in the peripheral zone. A well-differentiated pathological focus was demonstrated by p-CT in the patient with the mucinous variant of adenocarcinoma, which was confirmed by histopathological examination. According to the literature, patients with mucinous carcinoma have higher Gleason scores in the histopathological examination and demonstrate the presence of lesions in p-CT. Another limitation of our study was the small number of patients in the tested group. We need a larger group of patients to confirm our former results.

References:

- Miles KA. Perfusion CT for the assessment of tumor vascularity: which protocol? *Br J Radiol* 2003; 76: S36-S42.
- Yu K.K, Hricak H. Imaging Prostate Cancer. *Radiologic Clinics of North America* 2000; 38: 59-85.
- Hricak H, DoomsGC, Jeffrey RB, et al. prostatic carcinoma: Staging by clinical assessment, CT, and MR imaging. *Radiology* 1987; 162: 331.
- Prado A, Wallace S. Helical CT of prostate Cancer: early clinical experience. *AJR Am J Roentgenol* 2000; 175: 343-346.
- Miles KA. Measurement of tissue by dynamic computed tomography. *BR J. Radiol* 1991; 64: 409-412.
- Bigler SA, Deering RE, Brawer MK. Comparison of microscopic vascularity in benign and malignant prostate tissue. *Human Pathol* 1993; 24: 220-226.
- Brawer MK, Deering RE, Brown M et al. Predictors of pathologic stage in prostatic carcinoma. The role of neovascularuty. *Cancer* 1994; 73(3): 678-687.
- Siegel JA, Yu E, Brawe MK. Tomography of neovascularity in human prostate carcinoma. *Cancer* 1995; 75(10): 2545-51.
- Deering Re, Bigler Sa, Brown M, et al. Microvascularity in BPH. *Prostate* 1995; 26(3): 111-5.
- Gleason DF, Mellinger Gt. Prediction of prognosis for prostatic adenocarcinoma by combined histologic grading and clinical staging. *1974 J Urol* 111; 58-69.
- Fregene TA, Khanuja PS, Noto AC, et al. Tumor-associated angiogenesis in prostate cancer. *Anticancer Res* 1993; 13: 2377-2381.
- Miles KA Tumor angiogenesis and its relation to contrast enhancement on computed tomography: a review *Eur J Radiol* 1999; 30: 198-2005.
- Brawer M.K. Quantitative Microvessel Density. *Cancer* 1996; 78: 345-349.
- Engeler CE, Wasserman NE, Zhang G. Preoperative assessment of prostatic carcinoma by computerized tomography. Weaknesses and new perspectives. *Urology* 40: 346. 1992.
- Ives EP, Burke MA, Edmonds PR. Quantitative computed tomography perfusion of prostate cancer: correlation with whole-mount pathology. *Clinical Prostate Cancer* 2005 Sep; 4(2): 109-12.
- Manyak MJ, Javitt MC. The role of computed tomography, magnetic resonance imaging, bone scan and monoclonal antibody nuclear scan for prognosis prediction in prostate cancer. *Semin Urol Oncol* 1998; 16: 145-152.