Signature: © Pol J Radiol, 2009; 74(4): 93-98

Polish Journal of Radiology
www.PolRadiol.com

CASE REPORT

Received: 2009.08.29
Accepted: 2009.11.26

Focal lesions in the liver in the course of glycogenosis type I, in CT and MR images

Robert Chrzan, Andrzej Urbanik, Izabela Herman-Sucharska, Wadim Wojciechowski

Radiology Department, Jagiellonian University, Collegium Medicum, Cracow, Poland

Author's address: Robert Chrzan, Radiology Department, Jagiellonian University, Collegium Medicum, Kopernika 19 Str., 31-501 Cracow, Poland, e-mail: rchrzan@mp.pl

Summary

Background: Glycogenosis type I (von Gierke's disease) is an inherited hepatic glycogen storage disease. The main diagnostic criteria are: hepatomegaly, hypoglycemia and hyperlacticacidemia. Its transmission is autosomal recessive. Depending on the intensity of fatty degeneration and amount of glycogen, the liver density may be decreased, normal or increased. Hepatocellular adenomas develop in most patients and malignant degeneration of adenomas into hepatocellular carcinomas has been reported in some cases.

Case Report: Two siblings with glycogenosis type I were initially followed up using US. Focal liver lesions detected in US were then followed up in CT and MR and reported as adenomas. However, some lesions enlarged considerably in the course of observation and developed foci of degeneration suspicious for malignant transformation, so were referred for biopsy. FNB repeated several times revealed no malignant transformation.

Conclusions: Patients with glycogenosis type I must be periodically screened for malignant transformation of adenoma into hepatocellular carcinoma using biochemical markers and imaging.

Suspicion of malignant transformation in imaging may be difficult to verify in cytology/pathology.

Surgery/interventional radiology is suggested in every case of a lesion suspicious in imaging.

Liver transplantation is recommended as a definite treatment.

Key words: **glycogenosis • adenoma • computer tomography • magnetic resonance**

PDF file: http://www.polradiol.com/fulltxt.php?ICID=900397

Background

Glycogenosis type I is an inherited hepatic glycogen storage disease. Its subtype Ia (von Gierke's disease) is caused by insufficiency of glucose-6-phosphatase taking part in the synthesis of glucose from glucose-6-phosphate, produced in the process of gluconeogenesis and glicogenolysis. Subtype Ib involves glucose-6-phosphate translocase deficiency, which inhibits the glucose-6-phosphate transport to the endoplasmic reticulum.

The disease was first described in 1929, by a German physician, Edgar Otto Conrad von Gierke. Its prevalence amounts to approx. 1/100 000 and its transmission is autosomal recessive.

The first symptom of the disease is usually a major hepatomegaly in the very first weeks of life, which may be accompanied by hypoglycaemia – the cause of convulsions - and an increased concentration of lactates, leading to acidosis. Subsequent symptoms include kidney enlargement, growth inhibition in infants, obesity, hyperlipoproteinemia, muscle weakness, osteopenia, and platelet dysfunction. Renal complications may involve glomerular hyperfiltration, albuminuria, hyperuricaemia, hypercalciuria, nephrocalcinosis, lithiasis and end-stage renal disease [1,2]. Osteopenia may be the cause of fractures [3], hyperlipoproteinemia raises the risk of acute pancreatitis [4], and platelet dysfunction is responsible for predisposition to ecchymoses. Subtype Ib may be also connected with temporary neutropenia, increased susceptibility to infections [5], inflammations with ulceration of the oral and intestinal mucous membrane

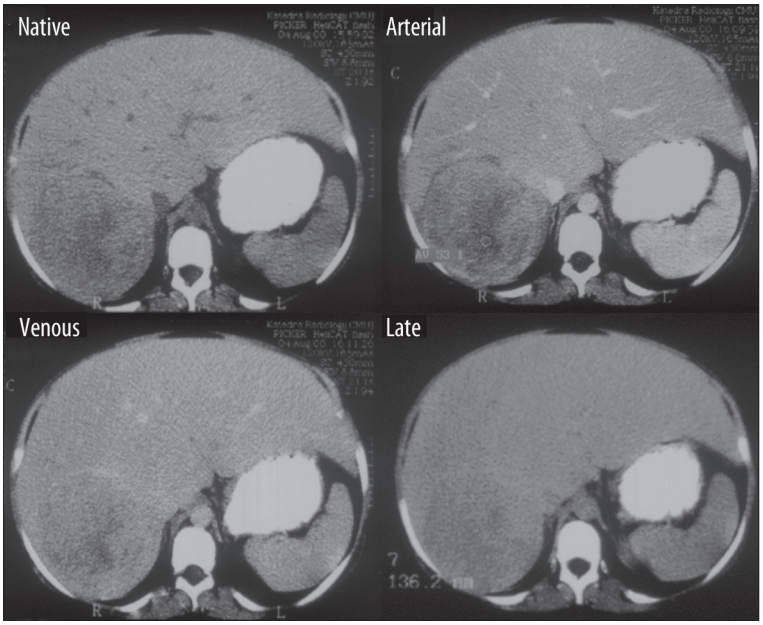

Figure 1. Patient E-J, CT performed in August 2000, axial slices before and after contrast media administration: in arterial, venous and late phases – tumor in the right liver lobe.

[6–8], and arthritis [9]. An important late complication, observed at the age of 20–30, is the formation of hepatic adenomas; in some cases, such lesions undergo malignant transformations to hepatocellular carcinomas [10].

A definite verification of glycogenosis type I bases on biochemical studies of glucose-6-phosphatase activity in the tissue sample collected during liver biopsy.

Treatment of glycogenosis type I bases first of all on prevention of the episodes of hypoglycemia by the introduction of a special diet, including cornmeal (which is slowly digested and absorbed in the GI track), night feeding through a NG tube or complete parenteral feeding [11]. Liver transplantation is recommended as a definite treatment [12–14].

Case Study

Patient E-J with a diagnosed and verified glycogenosis type I and a slowly enlarging (for the last 10 years) liver tumour, was subjected (in August 2000, at the age of 19) to a multiphase CT of the abdominal cavity with a single-row-detector spiral CT scanner (Figure 1), before and after i.v. non-ionic contrast administration, in the dose of 1 ml/kg. The examination revealed a significant liver enlargement and the presence of an extensive oval structure, 100×95×80 mm in size, within segment 6 and 7. The structure was quite sharply delineated and irregularly hypodense after intravenous contrast enhancement in the arterial and venous phase, with a hypodense central part and an isodense superficial part. In the late phase, nearly the whole structure was isodense, apart from minor fluid collections and scarce calcifications. Moreover, in the remaining liver parenchyma, there were a few roundish foci, 6–20 mm in diameter, quite sharply delineated, revealing contrast enhancement, but hypodense (in all phases), as opposed to the adjacent parenchymal structures of the liver. Afterwards, the patient was systematically followed up with USG.

In February 2006, due to the diagnosed significant progression of the lesions found on USG, the patient was subjected to a follow-up multiphase CT of the abdomen with a 10-detector row CT scanner (Figures 2, 3) – before and after intravenous non-ionic contrast administration, in the dose of 1 ml/kg.

The examination revealed enlargement of the tumour (to the size of 126×102×101 mm) within the right lobe, with a very non-homogeneous structure of the lesion, regions of degeneration, calcifications and minor changes within the fat tissue structure, in the arterial phase with a strong peripheral and central band-like contrast enhancement. Moreover, liver parenchyma, especially in the right hepatic lobe, revealed multiple roundish and oval lesions, isodense or moderately hypodense, after intravenous contrast enhancement in the arterial phase hyperdense, in the venous and late phase hypodense or isodense. These included minor lesions of homogeneous attenuation and contrast enhancement, as well as larger lesions, of non-homogeneous structure, with hypodense unenhanced regions, as in the foci of degeneration. Due to CT image suggestive of malignant transformation of the hepatocellular adenomas into hepatocellular carcinomas, especially in case of the largest lesion, the MRI examinations (Figures 4, 5) of the abdominal cavity were performed with the use of a 1.5T MRI scanner, in the following sequences: SSFSE T2, FSPGRE T1, FSPGRE T1+FatSAT and MRCP, unenhanced with breath-hold acquisition and dynamic FSPGRE T1 after i.v. administration of the contrast medium in the dose of 0.2 ml/kg. The examination revealed multiple (especially within the right lobe) solid, homogeneous, hypervascularised nodules with a rapid wash-out of the contrast medium in the dynamic CT. Furthermore, the image of the right lobe showed nodular lesions of an altered signal morphology – non-homogeneous, with irregular hypointense regions in T1-weighted sequences and slightly hypointense in T2-weighted sequences, which may be suggestive of degenerative lesions. The examination revealed a hypointense 'pseudocapsule' and an abnormal pattern of

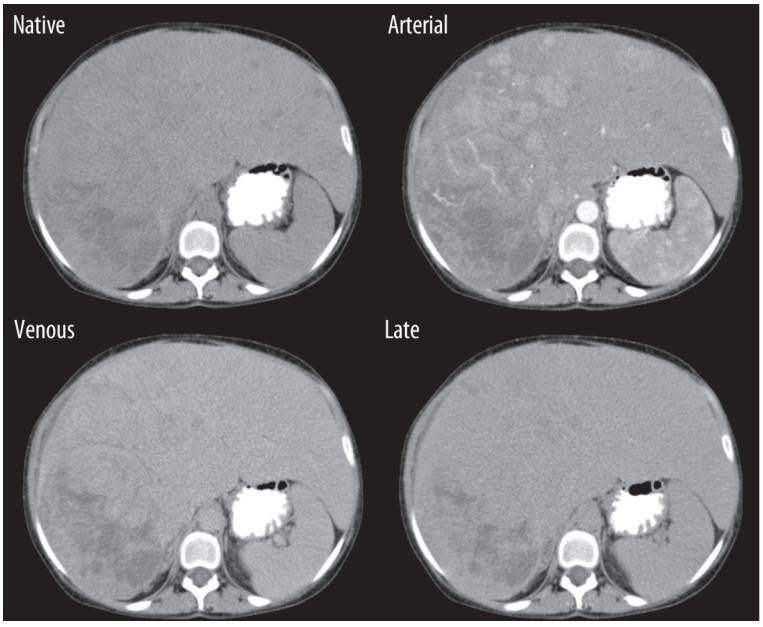

Figure 2. Patient E-J, CT performed in February 2006, axial slices before and after contrast media administration: in arterial, venous and late phases – progression of tumor in the right liver lobe, numerous smaller foci.

Figure 3. Patient E-J, CT performed in February 2006, coronal reconstruction in arterial phase - numerous foci in liver.

contrast enhancement (the solid part of the lesion retained the contrast in the late phase) within the largest lesions (110×120×90 mm and 70×40 mm). In order to exclude hepatocellular carcinomas, the patient was referred for biopsy of the above mentioned suspicious nodular lesions. FNB repeated several times revealed no malignant transformation. In the follow-up CT (of July 2006), there were no significant changes in the image of the liver, as compared to the previous examination results. The patient remains under a regular clinical follow-up/USG.

Patient T-J – brother of the above presented patient – with glycogenosis type I diagnosed in April 2006, at the age of 21, underwent a multiphase CT examination of the abdominal cavity with a 10-detector row spiral CT scanner (Figures 6, 7) – before and after the administration of the non-ionic contrast medium, in the dose of 1 ml/kg. The examination revealed liver enlargement, with parenchyma of non-homogeneously decreased attenuation, and with two quite well delineated nodules in segment 4 and 7 (19×17 mm and 22×23 mm, respectively), hypodense, after i.v. contrast enhancement in the arterial phase with a strong central enhancement, in the venous and in the late phase hypodense. After history taking, the lesions were classified as adenomas. Further follow-up was indicated. The patient remains under a regular clinical follow-up/USG

Discussion

The presented in this article focal lesions of the liver with features of adenoma in patients with glycogenosis type I are found (according to the literature) in 22–75% of adolescent and mature patients [13,15].

In CT examinations [16,17], adenomas are generally well-delineated, and slightly hypodense, due to the presence of intracellular lipids and the products of lesion of blood cells and necrotic foci. However, sometimes adenomas include hyperdense regions corresponding to a recent haemorrhage and glycogen accumulation. Larger lesions reveal non-homogeneous structure, due to haemorrhages and necrotic foci. Calcifications within lesions are rare. Most of the time, after intravenous contrast administration in the arterial phase, there is visible moderate enhancement of the tumour tissue, which is however less intense than the focal nodular hypertrophy and does not include a central scar. In the venous phase, adenomas may be hypo-, iso-, and hyperdense in comparison to the surrounding parenchyma. In approx. 25% cases, there are present thin capsules of the tumour, mostly hypodense in the arterial phase, in comparison to the surrounding parenchyma, and hyperdense in the venous phase.

In the MRI examination [17], adenomas are generally hyperintense in T1-weighted sequences (due to the presence of lipids and haemorrhages) and iso- or hyperintense in T2-weighted sequences. After i.v. contrast medium

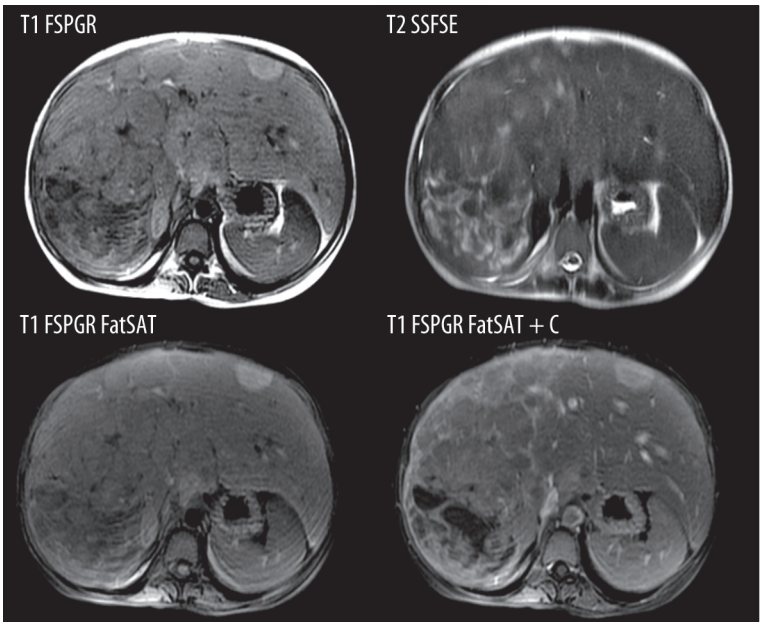

Figure 4. Patient E-J, MR performed in February 2006, axial slices in sequences: T1-weigted, T2-weigted, T1-weigted with fat supression, T1-weigted with fat supression after contrast media administration – large tumor of the right liver lobe, numerous smaller foci.

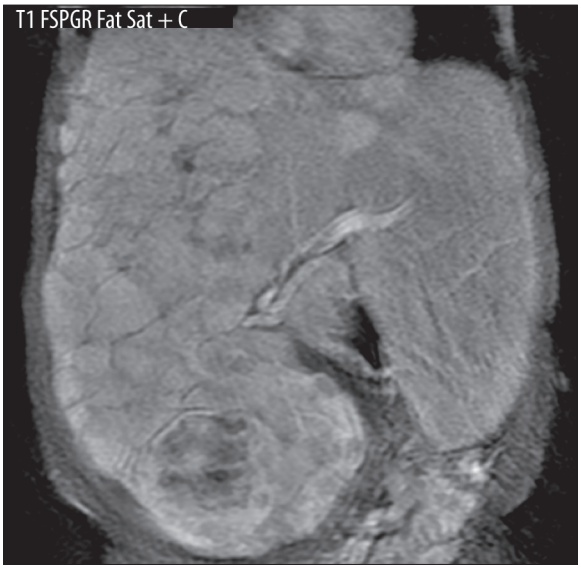

Figure 5. Patient E-J, MR performed in February 2006, coronal slice in T1-weigted sequence with fat supression after contrast media administration – large tumor of the right liver lobe, numerous smaller foci.

administration, the lesion is clearly hyperintense in comparison to the surrounding parenchyma, but may be also iso- or hypointense. The presence of lipids may be confirmed with reduction of signal intensity in out-of-phase images, as compared to the in-phase images. In approx. 30% of cases, we may observe a low-signal capsule around the lesion.

In the general population, hepatocellular adenomas are mostly connected with oral contraceptive or androgenic therapies. However, depending on the genotypic/fenotypic features, it is possible to distinguish four subtypes of such tumours [18], connected with different degrees of risk of malignant transformation. Hepatocellular adenomas diagnosed in the general population tend to be singular and large, and potentially surrounded with a capsule [16,17]. Adenomas in glycogenosis type I, on the other hand, are numerous, small (in most of the cases), and not surrounded by capsules – in both above presented cases there were multifocal lesions, mostly small [19].

An interesting, extraordinary feature of the glycogenosis-type-I adenomas, is the presence of Mallory bodies in histopathological examination. The bodies are accompanied by neutrophilic infiltrations and lamellar fibrosis. Although not present in adenomas of the general population, Mallory bodies are frequently found in hepatocellular carcinomas, irrespective of their aetiology [10].

Life-threatening complications of hepatocellular adenomas involve: bleeding and malignant transformation into hepatocellular (risk of 10%) [13,20]. In the imaging studies, features suggestive of malignant transformation involve: rapid enlargement of the lesion, non-homogeneous structure, including the necrotic foci [19] – lesions with such features were found in CT and MRI images of the presented patient.

According to the European Study on Glycogen Storage Disease Type I (ESGSD I) [21] guidelines, patients with focal lesions of the liver, diagnosed in the course of glycogenosis type I, should undergo USG examinations and measurements of AFP and CEA levels every 3 months. In case of rapidly enlarging foci, or changes in their image features, with a poor delineation of the borderlines – CT or MRI examinations are indicated. However, according to some authors, the determination of CEA and AFP is not a reliable marker of the malignant transformation in some of the adenomas found in the course of glycogenosis type I [19]. Moreover, even in the presence of a suspicious CT or MRI image, confirmation of malignant proliferation with histopathological biopsy may be difficult, due to unclear borderlines between the normal liver tissue, the tissue of the adenoma and of the carcinoma [22].

The recommended treatment option in patients with multiple hepatocellular adenomas in glycogenosis type

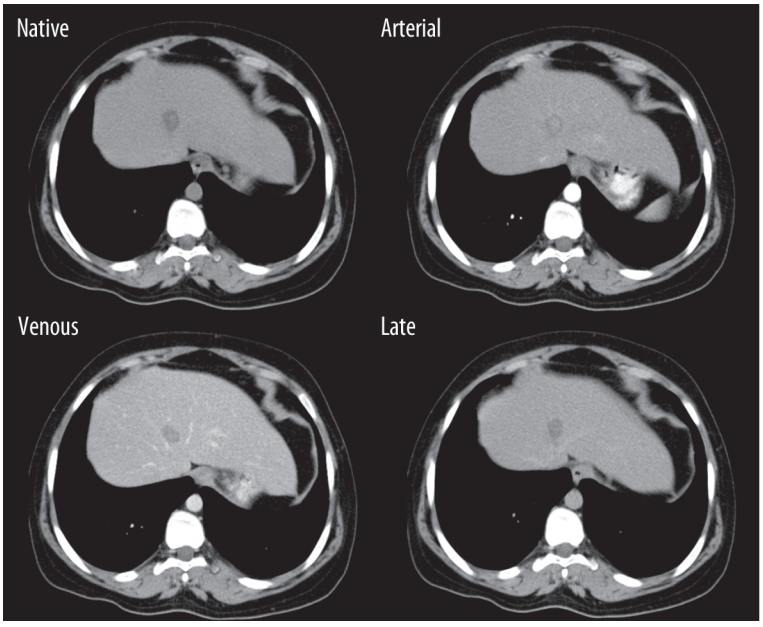

Figure 6. Patient T-J, CT performed in April 2006, axial slices before and after contrast media administration: in arterial, venous and late phases – lesion in liver segment 4.

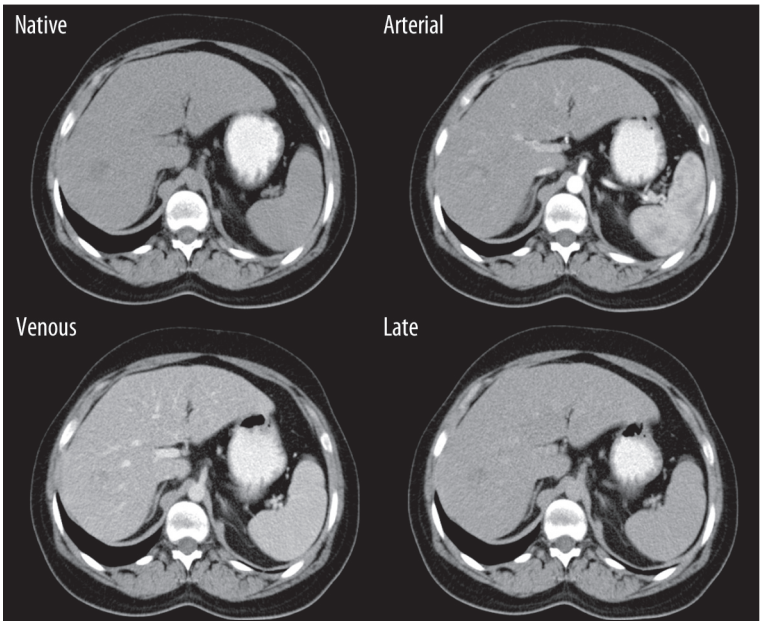

Figure 7. Patient T-J, CT performed in April 2006, axial slices before and after contrast media administration: in arterial, venous and late phases – lesion in liver segment 7.

I should be liver transplantation [12–14]. However, there are attempts to treat such lesions with the use of a selective surgical resection [23] or embolisation [24,25]. The literature includes also cases of spontaneous regression of adenomas in patients undergoing an intensive dietary treatment [10]. As the prognosis of patients with malignant transformation is very poor, aggressive treatment options are recommended (liver transplantation, surgical resection, embolisation) in every case of suspicious lesion found on imaging (even with normal AFP and CEA levels and no malignancy confirmed by biopsy) [19].

Conclusions

Patients with glycogenosis type I develop multiple hepatocellular adenomas in the course of the disease.

These patients must be screened periodically: they should have their tumour marker levels determined and should undergo imaging studies, due to the possibility of malignant transformation of the adenoma into the hepatocellular carcinoma.

Malignant transformation suspected on the basis of imaging examination results may be difficult to verify cytologically/histopathologically.

Surgical resection, or, possibly, embolisation, is suggested in every case of lesion suspicious in imaging.

Liver transplantation is recommended as a definite treatment.

References:

1. Reitsma-Bierens WC: Renal complications in glycogen storage disease type I. Eur J Pediatr, 1993; 152(Suppl.1) S60–62
2. Restaino I, Kaplan BS, Stanley C, Baker L: Nephrolithiasis, hypocitraturia, and a distal renal tubular acidification defect in type 1 glycogen storage disease. J Pediatr, 1993; 122: 392–96
3. Lee PJ, Patel JV, Fewtrel M et al: Bone mineralisation in type 1 glycogen storage disease. Eur J Pediatr, 1995; 154: 483–87
4. Kikuchi M, Hasegawa K, Handa I et al: Chronic pancreatitis in a child with glycogen storage disease type 1. Europ J Pediatr, 1991; 150: 852–53
5. Seger R, Steinmann B, Tiefenauer L et al: Glycogenosis Ib: neutrophil microbicidal defects due to impaired hexose monophosphate shunt. Pediatr Res, 1984; 18: 297–99
6. Roe TF, Coates TD, Thomas DW et al: Brief report: treatment of chronic inflammatory bowel disease in glycogen storage disease type Ib with colony-stimulating factors. N Engl J Med, 1992; 326: 1666–69
7. Visser G, Rake JP, Fernandes J et al: Neutropenia, neutrophil dysfunction, and inflammatory bowel disease in glycogen storage disease type Ib: results of the European Study on Glycogen Storage Disease type I. J Pediatr, 2000; 137: 187–91
8. Jurczak A, Plichta P, Kęsek B, Chomyszyn-Gajewska M: The picture of oral status in 14-years old child with glycogenosis Ib type - the case report. Porad Stomatol, 2003; 3: 27–30
9. Kołcun-Penkowska T: Chronic arthritis in a boy with glycogen storage disease type Ib. Rocz Med., 2004; 12: 109–14
10. Bianchi L: Glycogen storage disease I and hepatocellular tumours. Eur J Pediatr, 1993; 152(Suppl.1): S63–70
11. Gruszczyńska B, Pronicka E: Use of mais flour intreatment of glycogenosis typ I. Prz Pediatr, 1992; 22: 133–38
12. Lerut JP, Ciccarelli O, Sempoux C et al: Glycogenosis storage type I diseases and evolutive adenomatosis: an indication for liver transplantation. Transpl Int, 2003; 16: 879–84
13. Lee PJ: Glycogen storage disease type I: pathophysiology of liver adenomas. Eur J Pediatr, 2002; 161(Suppl.1): S46–49
14. Labrune P: Glycogen storage disease type I: indications for liver and/or kidney transplantation. Eur J Pediatr, 2002; 161(Suppl.1): S53–55
15. Di Rocco M, Calevo MG, Taro M et al: Hepatocellular adenoma and metabolic balance in patients with type Ia glycogen storage disease. Mol Genet Metab, 2008; 93: 398–402
16. Prokop M, Van der Molen A: Wątroba. W: Prokop M, Galanski M, Van der Molen A, Schaefer C, (eds.), Spiralna i wielorzędowa tomografia komputerowa człowieka. Medipage, Warszawa, 2007; 430–31
17. Heiken J, Menias C, Elsayes K: Liver. In: Lee J, Sagel S, Stanley R, Heiken J (eds.), Computer Body Tomography with MRI Correlation. Lippincott Williams&Wilkins, Philadelphia, 2006; 854–58
18. Bioulac-Sage P, Laumonier H, Laurent C et al: Hepatocellular adenoma: what is new in 2008. Hepatol Int, 2008; 2: 316–21
19. Franco LM, Krishnamurthy V, Bali D et al: Hepatocellular carcinoma in glycogen storage disease type Ia: a case series. J Inherit Metab Dis, 2005; 28: 153–62
20. Conti JA, Kemeny N: Type Ia glycogenosis associated with hepatocellular carcinoma. Cancer, 1992; 69: 1320–22
21. Rake JP, Visser G, Labrune P et al: Glycogen storage disease type I: diagnosis, management, clinical course and outcome. Results of the European Study on Glycogen Storage Disease Type I (ESGSD I). Eur J Pediatr, 2002; 161(Suppl.1): S20–34
22. Kudo M: Hepatocellular adenoma in type Ia glycogen storage disease. J Gastroenterol, 2001; 36: 65–66
23. Reddy SK, Kishnani PS, Sullivan JA et al: Resection of hepatocellular adenoma in patients with glycogen storage disease type Ia. J Hepatol, 2007; 47: 658–63
24. Yoshikawa M, Fukui K, Kuriyama S et al: Hepatic adenomas treated with percutaneous ethanol injection in a patient with glycogen storage disease type Ia. J Gastroenterol, 2001; 36: 52–61
25. Endoh A, Inoue N, Katoh T et al: A case of glycogen storage disease IA with multiple hepatic tumors managed by transcatheter arterial embolization and an acarbose diet. J Pediatr Gastroenterol Nutr, 2001; 33: 333–36