Signature: © Pol J Radiol, 2009; 74(3): 66-68

Polish Journal of Radiology
www.PolRadiol.com

CASE REPORT

Received: 2009.04.02
Accepted: 2009.04.20

Intestinal malrotation diagnosed with ultrasound in an 11-year-old female with malnutrition – a case report

Dominik Swieton[1], Maciej Piskunowicz[2], Wojciech Kosiak[1], Andrzej Golebiewski[3]

[1] Department of Pediatric Nephrology, Medical University of Gdańsk, Gdańsk, Poland
[2] Department of Radiology. Medical University of Gdańsk, Gdańsk, Poland
[3] Department of Pediatric Surgery and Urology. Medical University of Gdańsk, Gdańsk, Poland

Author's address: Maciej Piskunowicz, Department of Radiology, Medical University of Gdańsk, Poland, e-mail: mpiskunowicz@wp.pl

Summary

Intestinal malrotation is usually diagnosed in the first year of life; however; the symptoms can intensify only at an older age, causing diagnostic problems. The patients may suffer from different complaints and have a diagnosis completely unrelated to existing intestinal malrotation.

We present a case of an 11-year-old female with malnutrition and acute renal failure incidents who had the intestinal malrotation diagnosed with ultrasound examination. The final diagnosis was confirmed with upper and lower gastrointestinal series and later during surgery.

Key words: ultrasound • inestinal malrotation • malnutrition

PDF file: http://www.polradiol.com/fulltxt.php?ICID=893730

Case Report

We present a history of a patient with malnutrition and recurrent acute renal failure incidents caused by late-diagnosed intestinal malrotation.

An 11-year-old female was admitted to the Pediatric Nephrology Department because of the third incident of acute renal failure. All the three episodes of the kidney function impairment were preceded by abdominal pain, vomiting and following dehydration.

On admission to hospital, the patient was in a severe general condition, with signs of dehydration. In laboratory studies, deceleration of kidney function was found (eGFR 30 ml/min/1,73 m^2 according to Schwartz formula). There was a positive anamnesis of malnutrition and recurrent abdominal pain so far diagnosed as a result of frequent cystitis incidents. Intensive fluid and electrolytes supplementation was adequate treatment to improve the general condition with normalization of the laboratory tests. In the first abdominal ultrasound examination, there were no significant abnormalities found except hepatomegaly and hyperechoic kidneys.

During the third incident of acute renal failure, the performed ultrasound revealed distended duodenum. Therefore, ultrasound examination after intensive oral fluid intake was performed, using GE Logiq 500 equipment with a linear probe of 8,2–11,0 MHz and with a convex probe of 3–5,5MHz (GE Medical Systems, Waukesha, WI, USA).

The results of ultrasound examination suggested the presence of intestinal malrotation as well in B mode as in Doppler modality. In B mode, the distended duodenum was marked (Figure 1), with twisting of the jejunum loops around the mesenteric artery (Figure 2). In a longitudinal scan, we noticed a couple of intestinal loops crossing the midline between the aorta and superior mesenteric artery (SMA) (Figure 3). We also noticed thickening of the muscular layer of the pylorus, confirmed during surgery, most probably caused by difficulties in food passage. The "whirlpool sign" was found in Color Doppler examination (Figure 4) – superior mesenteric vein (SMV) was located to the left from SMA.

The final diagnosis was confirmed by upper and lower gastrointestinal series (Figures 5–6). The patient was transferred to the Department of Pediatric Surgery for an elec-

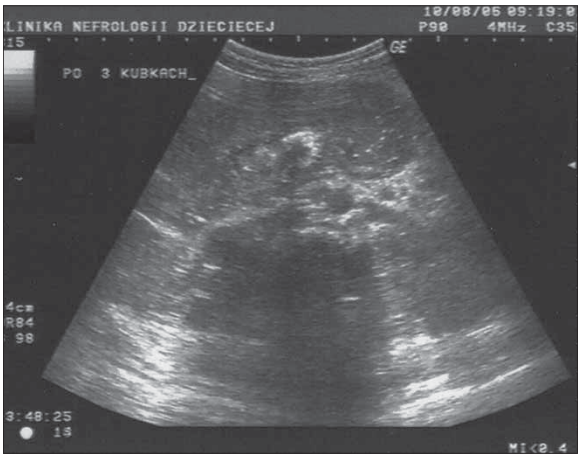

Figure 1. Transverse scan of the abdomen presenting distended loops of the duodenum and jejunum.

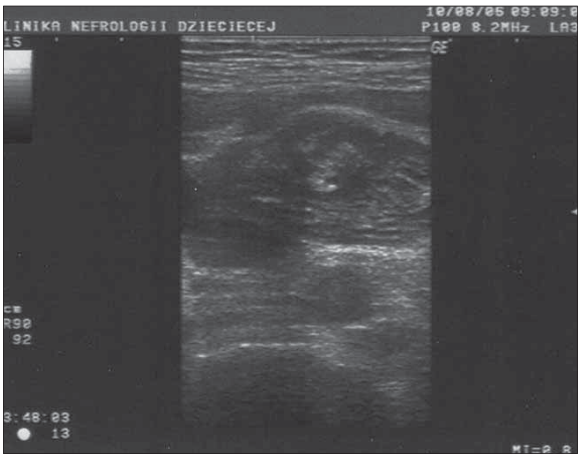

Figure 2. Transverse scan of the abdomen showing twisted loops of the small intestine around superior mesenteric artery.

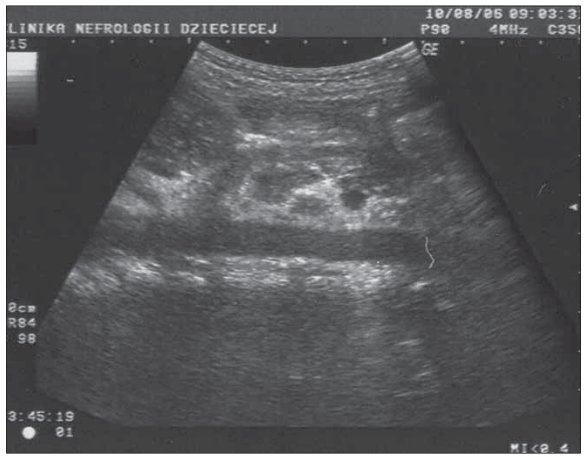

Figure 3. Longitudinal section through superior mesenteric artery shows the truncated superior mesenteric artery sign.

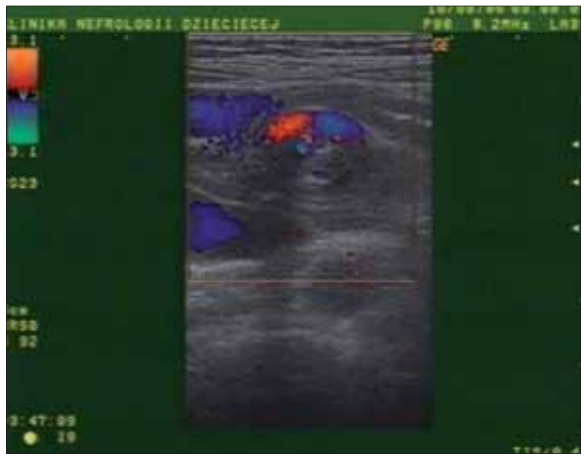

Figure 4. Malposition of the mesenteric vessels presenting as "whirlpool sign" in color Doppler.

tive surgery. Laparoscopy revealed the ''classical'' form of malrotation, consisting of complete failure of rotation of both the proximal and distal loops. The duodenojejunal flexure was located to the right of the spine, the entire small bowel residing in the right abdomen, the cecum and colon in the left abdomen. Rotation of the small bowel around the narrowed pedicle of the superior mesenteric artery and signs of chronic volvulus – duodenal dilatation and thickening of duodenal and pyloric wall was also present.

Finally, the patient underwent the classical Ladd procedure, which entailed counterclockwise detorsion the midgut volvulus. There were no major intraoperative complications or cardiopulmonary, cerebrovascular, or thrombotic problems. The patient was discharged at day 6 after the surgery. Postoperatively, the vomiting and abdominal pain incidents disappeared and there was no kidney function deterioration anymore (eGFR 101 ml/min/1,73 m^2 according to Schwartz formula) while the significant weight gain from 25 kg (<3 cc) to 32 kg (10 cc) during a 4-month period was observed.

Discussion

Intestinal malrotation is usually defined as intestinal nonrotation or incomplete rotation around the superior mesenteric artery (SMA) [1] with incidence ranging from 1 in 6000 to 1 in 200 [2] live births. The term "malrotation" encompass a wide variety of anatomy, ages and clinical presentation. In most of the cases, it is associated with other anomalies like duodenal atresia, jejunoileal atresia, Hirschsprung disease, gastroesophageal reflux, persistent cloaca, anorectal malformations (imperforate anus), and extrahepatic anomalies.

The symptoms of intestinal malrotation can vary from gastroesophageal reflux, vomiting, pancreatitis, malabsorbtion, abdominal pain, to acute or chronic midgut volvulus. Intestinal malrotation is usually diagnosed in the first year of life (75–86%) [3] but rarely the symptoms can intensify only in an older age, causing diagnostic problems [4].

There are different radiologic methods helpful in establishing the final diagnosis like upper and lower gastrointestional series, ultrasonography or computer tomography (CT) [5]. Upper and lower gastrointestional series have been the gold standard so far, however, nowadays they are very often replaced by ultrasound or CT [6].

In children, ultrasound study is a very useful method and often a method of choice in diagnosing congenital intesti-

Figure 5. Upper gastrointestinal series shows contrast agent-filled duodenum and jejunal loops that remain right-sided.

Figure 6. Late images of upper gastrointestinal series presenting translocation of the right colon to the middle and left body line with the cecum located in the left lower quadrant of the abdomen.

nal abnormalities. If there is any suspicion of the GI tract anomaly then intensive oral fluid intake before ultrasound study should be necessary. However, it is most important to be aware of this anomaly. In B mode, we can observe distention of the duodenum and small intestine, malposition of the cecum. In a typical intestinal malrotation, the intestinal loops are twisted around the SMA. It is important to estimate the relationship between the SMA and SMV, which are usually inverted to each other, visible in Color Doppler option as "whirlpool sign"[7]. We also noticed thickening of the muscular layer of the pylorus caused by difficulties in food passage, which is rarely mentioned in literature.

When intestinal malrotation is suspected during ultrasound examination, further radiological studies should be performed. Intestinal malrotation can cause very intensive vomiting and malnutrition reflecting also in kidney function as it was in our case [8].

References:

1. Mehall J, Chandler J, Mechall R et al: Management of typical and atypical intestinal malrotation. J Pediatr Surg., 2002; 37(8): 1169–72
2. Donnellan W, Kimura K: Malrotation, internal hernias, congenital bands. In: Donnelan W, Burrington JD, Kimura K (eds.), Abdominal surgery of infancy and childhood. New York: Harwood Academic Publishers, 1996; 43: 1–27
3. Stewart DR, Colodny AL, Dagget WC: Malrotation of the bowel in infants and children: A 15 year review. Surgery, 1976; 79: 716–20
4. Ruiz-Tartas A, Arizaga-Rovalino P, Fernandez-Lobato R et al: Intestinal malrotation in an adult. Rev Esp Enferm Dig, 1994; 86: 701–2
5. Pickhardt PJ, Bhalla S: Intestinal malrotation in adolescents and adults: spectrum of clinical and imaging features. AJR Am J Roentgenol, 2002; 179(6): 1429–35
6. Kapfer SA, Rappold JF: Intestinal malrotation – not just the pediatric surgeon's problem. J Am Coll Surg, 2004: 199(4): 628–35
7. Orzech N, Navarro OM, Langer JC: Is ultrasonography a good screening test for intestinal malrotation? J Pediatr Surg. 2006; 41(5): 1005–9
8. Koshida R, Sakazume S, Maruyama H et al: A case of pseudo-Bartter's syndrome due to intestinal malrotation. Acta Paediatr Jpn, 1994; 36: 107–11