Signature: © Pol J Radiol, 2009; 74(3): 56-59

Polish Journal of Radiology
www.PolRadiol.com

REVIEW ARTICLE

Received: 2009.07.30
Accepted: 2009.08.12

Perianal fistulas – diagnostic imaging techniques and their applications

Tomasz Adamczyk[1], Ewa Kluczewska[1,2], Dariusz Waniczek[3], Paweł Bożek[1,2], Ewa Kozińska-Marek[1]

[1] Autonomous Health Administration Unit VOXEL, Medical Diagnostic Centre, Specialist Hospital No. 1, Bytom, Poland
[2] Department and Laboratory of Clinical Radiology and Radiodiagnostics, Medical Univeristy of Silesia in Katowice, Zabrze, Poland
[3] Department and Clinical Department of General Surgery and Gastroenterology of the Medical University of Silesia in Katowice, Bytom, Poland

Author's address: Tomasz Adamczyk, Autonomous Health Administration Unit VOXEL, Medical Diagnostic Centre, Specialist Hospital No. 1, Bytom, Poland, e-mail: t.adamczyk@voxel.pl

Summary

The application of imaging techniques in the diagnostic work-up of perianal fistulas is fundamental for an adequate description of the pathological lesion with an exact course of the fistular canal, together with its external and internal orifice which, that together with determined concomitant pathologies enables a right choice of a proper therapeutical method that most often involves a surgical intervention. The effectiveness of the treatment is in each case connected mainly with a minimised risk of recurrences and faecal incontinence in postoperative patients. The rate of these complications correlates primarily with unavailable comprehensive and precise imaging diagnostic tools and with different rates of precision of every radiological method. Our work summarises the currently available data on that subject

Key words: **perianal fistulas • diagnostic imaging techniques**

PDF file: http://www.polradiol.com/fulltxt.php?ICID=893719

Perianal fistulas constitute a heterogenic group of pathological lesions within the terminal part of the GI tract and within the perigenital region They are jointly termed as 'anorectal malformations' [1]. A significant role in their pathophysiology and formation is played by the location of the lesion and the number of perianal glands in that region, as well as the direction of infection spreading along the anatomical planes [2,3]. As it was established by Parks, ⅔ of the anal glands in the anal pecten communicate with the intrasphincteric space, which makes this area the most susceptible to infections, abscesses and fistular lesions [2]. However, not every perianal abscess is of glandular origin – cryptogenic. The portals of entry for the infection may also include: anal fissure, postoperative wounds, anal injury, colitis ulcerosa, and Leśniowski-Crohn disease. The connection between the presence of the aforementioned pathologies and the development of anorectal sepsis has been known for ages. Purulent lesions of that region may disseminate in many planes, which determines the course and the final location of the infection. The classification of the abscesses is based on their anatomical location (perianal, perirectal, intrasphincteric, ischiorectal, supraelevatory). The lesions that spread indirectly to the perirectal space, starting at the posterior, medial gland, and then penetrating the external sphincter muscle of anus, lead to the formation of a horseshoe-shaped fistula. According to the results of the cultures of abscesses, the anaerobic enteric bacteria and bacteroids are found in as much as 98% of the abscesses. In the case of fistulas this is only 85%. Difficulties in regression and spontaneous healing of the anorectal malformations may be due to frequent concomitant systemic pathologies (Leśniowski-Crohn disease, actinomycosis, neoplastic disease), plugging within the skin (inhibited outflow), persisting infections, or the presence of anaerobic bacteria (bacteroids, eterococci). Immunosuppressive and HIV-infected patients are at an increased risk of complications. The next, important factor seems to be a progressive epithelisation of the glands, skin, rectum or the anal transitional zone. Similarly, a small external or internal orifice of the fistula may result in an occlusion of its lumen and a delayed healing process [2–4]. Abscesses may also form as a consequence of differ-

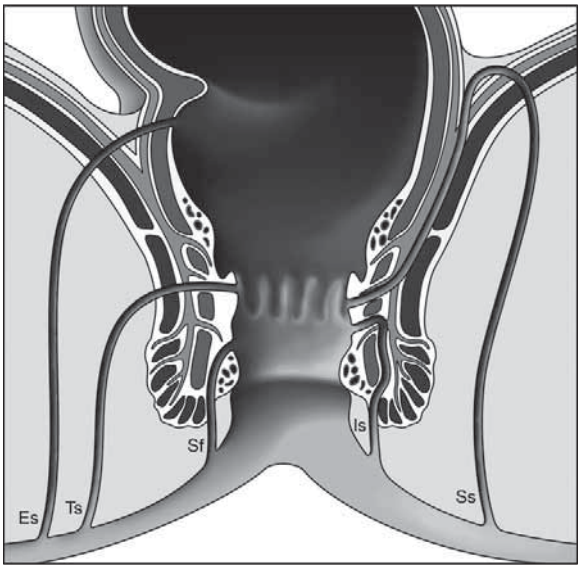

Figure 1. Perianal fistulas – location. Es – extrasphincteric fistula, Ts – transsphincteric fistula, Is – intersphincteric fistula, Ss – suprasphincteric fistula, Sf – superficial fistula.

ent ongoing disease processes within the peritoneal cavity (appendicitis, diverticulits, periostitis of the sciatic, pubic, and sacral bone, tuberculosis). Half of the purulent processes develop into chronic abscesses, i.e. the fissures.

Perianal Fistulas – Classification, Structure, Treatment

The perianal fistulas were classified into four main types, on the basis of the Park's classification, i.e. depending on the location of the fistular canal in relation to the external sphincter muscle of anus: intrasphincteric, transsphincteric, suprasphincteric and extrasphincteric. An additional group is formed by those fistulas that are placed superficially – subcutaneously [1,2,5] (Figure 1).

The perianal fistula is a canal filled with granulation tissue and surrounded with a hard fibrous tissue. Other subtypes of fistulas, present in the nomenclature, are connected with the course of the fistula and the presence of concomitant, additional fistular canals that determine the method of their treatment (simple, complex, multiple, recurrent). The treatment methods include classical operational procedures: fistulotomy, fistulotomy with marsupialisation, fistulectomy, insertion of a seton, advancement flap repair. Moreover, the surgeons use different tissue glues and 'plugs' inserted into the fistular canal. However, the choice of the treatment method depends on the type of the fistula, its location in relation to the sphincters and personal experiences of a surgeon who always thinks of the basic postoperative complications, such as transient or permanent faecal incontinence and fistula recurrence. Special indications concern fistula formed in the process of the Leśniowski-Crohn disease. A complete remission of the disease (that enables full recovery from the fistula) is extremely rare in here. Extensive surgical procedures are contraindicated. If the fistula is asymptomatic – no purulent effusion – it does not require treatment. A simple fistula, located at the end of the anus, can be treated in one way only: by an incision. The healing process lasts for 6 months. A complex fistula is treated by insertion of the seton which enables the purulent drainage and prevents the infection process from spreading to other body organs (antibiotic therapy). Sometimes it is possible to implement the advancement flap repair method. However, an active inflammation of the rectal mucous membrane is an absolute contraindication [1,3,6–10]. When trying to heal the fistula, the clinicians often use infiximab – in a conservative treatment regimen, or as a therapy combined with the surgical procedure. Rectovaginal fistula, with its two subtypes (high and low), is rarely diagnosed in women. Most frequently this is a congenital defect, but also a result of diverse injuries and infections. It may as well appear in the course of the Leśniowski-Crohn disease, colitis ulcerosa, as a result of a neoplastic disease or postradiation injury [11,12]. Positive results of the surgical treatment are here observed in 60–80% of cases [7]. The effectiveness of the commonly used treatment methods depends on many factors. Sangwan et al. showed a rate of recurrence of 6.5% in patients subjected to the procedure due to a simple fistula. Treatment failure was (in most of the cases) a consequence of the surgeon's inability to find the internal orifice of the fistula. Other reasons included undiagnosed additional canals, inappropriate evaluation of the course of the fistula canal, horseshoe-shaped fistula and a premature wound closure after fistulotomy [13].

Perianal Fissures – Diagnostic Work-up

A preliminary diagnostic work-up of a simple fistula is based first of all on history-taking, a detailed physical examination, analysis of characteristic signs and symptoms that, according to some authors, could lead to a correct diagnosis in as much as 48% of cases [4]. Chief complaints of the patients include: periodic pains and purulent, sometimes bloody, perianal discharge. In most of the cases there is a history of abscess drainage in that region. There are three basic radiological techniques of pathological lesion imaging that enable an evaluation of the range of expansion, type of tissue involved, presence of additional inflammatory or purulent foci, location of internal and external orifices of the fistula and the course of the main canal and potential additional branches, in the case of a complex fistula. These are: contrast fistulography, intrarectal ultrasonography and MRI. Each of these methods is connected with some benefits, but also with limitations, and they are all used interchangeably in diagnostically unclear cases and, first of all, in defining the range of the surgical treatment. The least frequently used method – fistulography - is actually useful in visualising the main fistular canal only, and the sensitivity of this method, according to different authors, ranges from 24–50%. Additional branches, frequently filled with granulation tissue, cannot be penetrated by the contrast medium used in this examination [2,14–19].

A basic, relatively easily available and cheap method used for visualization of the mentioned pathologies is nowadays a simple intrarectal ultrasonography and contrast ultrasonography that is becoming more popular and precise (3% hydrogen peroxide). However, in many cases, this method cannot detect lesions that are situated high in the tract (suprasphincteric), subcutaneous lesions, horseshoe-shaped lesions or smaller additional branches. According to many authors, it can be used for a rough evaluation only, when

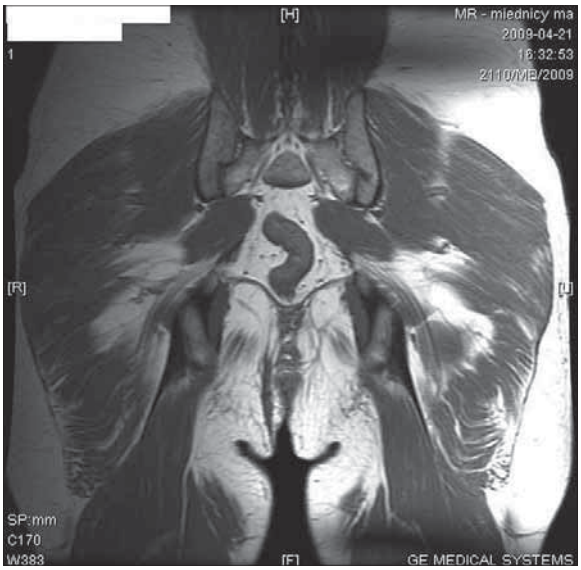

Figure 2. MRI method. T1-weighted images in the frontal plane. A simple superficial fistula, with an orifice in the gluteal cleft, on the right.

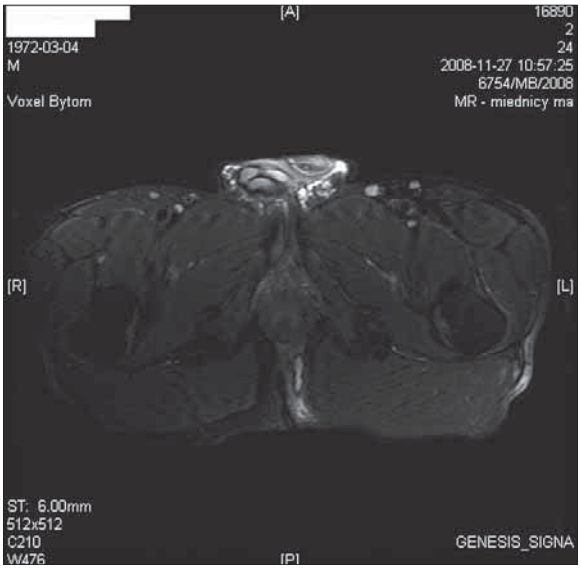

Figure 3. MRI method. T2-weighted images with FAT sat, in the transverse plane. The perianal fissure canal with its orifice in the gluteal cleft, on the left.

establishing the postoperative state of the sphincters, and before lesser procedures, such as the incision or the drainage [2,3,17,18,20,21].

Most of the doubts are resolved by means of the MRI method. Not only can the MRI visualise the course of simple and complex fistula, together with additional canals, but also the state of the surrounding soft tissues, in respect of concomitant inflammatory processes or the presence of abscesses. It is also the most useful method of defining the range of the surgical reconstructive intervention [20]. According to some authors, the surgical procedure based on a proper diagnostic work-up, with the use of the MRI, may reduce the recurrence rate three times. It was also estimated that this rate is statistically higher in the

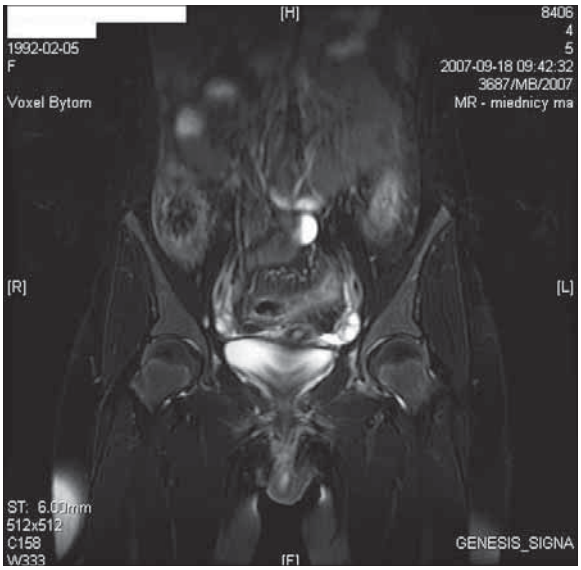

Figure 4. MRI method. T2-weighted images with FAT sat, in the frontal plane. The perianal fissure canal ended blindly within the labium, on the left. A large oedema surrounding soft tissues.

group of patients with a diagnosis based on the endosonographic examination only, as compared to the group of patients diagnosed with the use of the MRI [23]. Maier et al. revealed a statistically higher effectiveness of the diagnostic work-up of the perianal fistulas and abscesses, applying the MRI, as compared to the endosonography (the sensitivity of 84% vs. 60%, respectively), in a group of 39 patients. False positive results were shown in 6 cases (15%) diagnosed with the MRI and in 10 cases diagnosed with endosonography (26%) [20]. Beets-Tan et al. evaluated the usefulness of the diagnostic method by comparing the MRI results obtained before the surgical procedure with an intraoperative image, and showed that the sensitivity and specificity of the study method in revealing the fistular canals amounts to 100 and 86%, respectively, in evaluating the horseshoe-shaped fistula – 100 and 100%, and in evaluating the internal orifices – 96 and 90%, respectively [17]. The MRI study proceeds with the use of a spin-echo (SE), turbo spin-echo (TSE), and gradient echo (GRE) sequences – T1- and T2-weighted images, and STIR (short tau inversion – recovery) sequence, in transverse, frontal, and sagittal planes, with an application of an external coil, placed at the level of the iliac joints. The contrast medium based on gadolinium can be administered into the fistular lumen, in case of an external orifice. The subsequent use of the sequences with fat sat is helpful in a detailed analysis of the fistular canals, filled with a highly hypertensive contrast medium, compared to a hypotensive background. Many authors underscore the significance and possible applications of the STIR sequence, the sensitivity of which may exceed sensitivities of other standard sequences using the contrast medium [2,4,13,16,17,19,20,24,25]. A derivative method, characterised by a high resolution of the image and considerable precision, is the MRI using an endorectal coil. Unfortunately, a small range of a homogenous magnetic field, limited to regions in the vicinity of the endorectal coil, narrows down the applications of this method (Figures 2–4).

New possibilities and large expectations are connected with the subtraction MR-fistulography. However its availability is still minimal. According to some papers, this diagnostic tool reveals a sensitivity and specificity of approx. 89%, when evaluated with the use of the intraoperative material [26]. The visualisation of the lesions is possible thanks to pathological contrast enhancement within the inflamed, fibrated walls of the fistulas or abscesses, after intravenous contrast administration. It also enables a more precise differentiation of the anatomical structures within the bottom of the lesser pelvis. The study does not require a preparation of the intestines. Thanks to the application of the volumetric sequences of high resolution, the images obtained in the course of the examination can be subjected to multiplantar reconstructions and analysed in a 3D form. Moreover, the time of the study is shorter which undoubtedly enhances the comfort of the patient and minimises the risk of movement artefacts [26–28].

Conclusions

Radiological imaging techniques used in the diagnostic work-up of the anorectal malformations constitute a useful tool applied to describe the lesions in detail, their type, location and expansion range, especially from the point of view of a successful surgical intervention that would minimise the number of recurrences. An increasing availability of the state-of-the-art, advanced diagnostic methods, and first of all the MRI, indicates that a comprehensive diagnostic work-up will soon embrace every patient with a suspected perianal fistula, planned for surgery.

References:

1. Holschneider A, Hutson J, Pena A et al: Preliminary report on the International Conference for the Development of Standards for the Treatment of Anorectal Malformations. J Pediatr Surg, 2005; 40: 1521–26
2. Shorthouse AJ: Anal fistula. J R Soc Med, 1994; 87: 491–93
3. Kubota A, Kawahara H, Okuyama H et al.: Laparoscopically assisted anorectoplasty using perineal ultrasonographic guide. J Pediatr Surg, 2005; 40: 1535–38
4. Inceoglu R, Gencosmanoglu R: Fistulotomy and drainage of deep postanal space abscess in the treatment of posterior horseshoe fistula. BMC Surgery, 2003; 3: 10
5. Parks AG, Gordon PH, Hardcastle JD: A classification on fistula – in – ano. Br J Surg, 1976; 63: 1–12
6. Pakarinen MP, Goyal A, Koivusalo A et al: Functional outcome in correction of perineal fistula in boys with anoplasty versus posterior sagittal anorectoplasty. Pediatr Surg Int, 2006; 22: 961–65
7. Walfisch A, Zilberstein T, Walfisch S: Rectovaginal septal repair: case presentations and introduction of a modified reconstruction technique. Tech Coloproctol, 2005; 8: 192–94
8. Quah HM, Tang CL, Eu KW et al: Meta-analysis of randomized clinical trials comparing drainage alone vs primary sphincter-cutting procedures for anorectal abscess and fistula. Int J Colorectal Dis, 2005; 21: 602–9
9. Gustafsson UM, Graf W: Randomized clinical trial of local gentamicin-collagen treatment in advancement flap repair for anal fistula. Br J Surg, 2006; 93(10): 1202–7
10. Christoforidis D, Pieh MC, Madoff RD et al: Treatment of transsphincteric anal fistulas by endorectal advancement flap or collagen fistula plug: a comparative study. Dis Colon Rectum, 2009; 52(1): 18–22
11. Penninckx F, Moneghini D, D'Hoore A et al: Succes and failure after repair of rectovaginal fistula in Crohn's disease: analysis of prognostic factors. Colorectal Dis, 2001; 3: 406–11
12. Kumaran SS, Palanivelu C, Kavalakat AJ et al: Laparoscopic repair of high rectovaginal fistula: Is it technically feasible? BMC Surgery, 2005; 5: 20
13. Sangwan YP, Rosen L, Riether RD et al: Is simple fistula – in – ano simple? Dis Colon Rectum, 1994; 37: 885–89
14. Toyonaga T, Tanaka Y, Song IF et al: Microbiological analysis and endoanal ultrasonography for diagnosis of anal fistula in acute anorectal sepsis. International J Col Dis, 2006; 22: 209–13
15. Felt-Bersma RJ, Cazemier M: Endosonography in anorectal disease: an overview. Scand J Gastroenterol Suppl, 2006; 243: 165–74
16. Schaefer AO, Baumann T, Langer M: MRI for the detecton of anorectal fistulas. RoFo, 2006; 178: 1095–104
17. Beets-Tan RG, Beets GL, van der Hoop AG et al: Preoperative MRI of anal fistulas: Does it really help the surgeon? Radiology, 2001; 218: 75–84
18. Kruskal JB, Kane RA, Morrin MM: Peroxide-enhanced anal endosonography: technique, image interpretation and clinical aplications. Radiographics, 2001; 21: 173–89
19. Lunnis PJ, Armstrong P, Barker PG et al: Magnetic resonance imaging of ananl fistulae. Lancet, 1992; 340: 394–96
20. Maier AG, Funovics MA, Kreuzer SH et al: Evaluation of perianal sepsis: Comparison of anal endosonography and magnetic resonance imaging. J Magn Reson Imaging, 2001; 14: 254–60
21. Sudoł-Szopińska I, Jakubowski W, Szczepkowski M: Contrast-enhanced endosonography for the diagnosis of anal and anovaginal fistulas. J Clin Ultrasound, 2002; 30: 145–50
22. Buchanan GN, Williams AB, Bartram CI et al: Potential clinical implications of direction of a trans-sphincteric anal fistula track. Colorectal Disease, 2003; 5: 381–84
23. Buchanan GN, Halligan S, Williams A: Effect of MRI on clinical outcome of recurrent fistula-in-ano. Lancet, 2002; 360: 1661–62
24. Gould SW, Martin S, Agarwal T et al: Image-guided surgery for anal fistula in a 0,5 T interventional MRI unit. J Magn Reson Imaging, 2002; 16: 267–76
25. Hussain SM, Stoker J, Zwamborn AW et al: Endoanal MRI of the anal sphincter complex: correlation with cross-sectional anatomy and histology. J Anat, 1996; 189: 677–82
26. Schaefer O, Lohrmann C, Kreisel W et al: Differentiation of perianal fistulas with digital subtraction magnetic resonance fistulography. Inflamm Bowel Dis, 2005; 11: 383–87
27. Schaefer O, Lohrmann C, Langer M: Assessment of anal fistulas with high-resolution subtraction MR-fistulography: Comparison with surgical findings. J Magn Reson Imaging, 2004; 19: 91–98
28. Schaefer O, Lohrmann C, Langer M: Digital Subtraction MR fistulography: new diagnostic tool for the detection of fistula – in – ano. AJR, 2003; 181: 1611–13