**Signature:** © Pol J Radiol, 2009; 74(2): 48-52

Polish Journal of Radiology
www.PolRadiol.com

CASE REPORT

**Received:** 2008.11.28
**Accepted:** 2009.04.14

# Primary renal lymphoma – case report

Witold Krupski[1], Joanna Kruk-Bachonko[1], Artur Pohl[2], Krzysztof Michalak[2]

[1] II Zakład Radiologii Lekarskiej Uniwersytetu Medycznego w Lublinie, Lublin, Poland
[2] Oddział Chirurgii Ogólnej i Urazowej SPZOZ Krasnystaw, Krasnystaw, Poland

Author's address: Witold Krupski, Staszica 16 Str., 20-081 Lublin, Poland, e-mail: krupskiw@wp.pl

## Summary

Background: Primary renal lymphoma is a very rare and controversial disease entity. Diagnostic criteria and therapeutic procedure are not obvious. However, a few cases have been reported in the world literature. Pathological symptoms and radiological manifestation are not typical. Correct diagnosis is established thanks to renal biopsy. Even though curative algorithm is not clear, the fact is that early diagnosis and treatment have a big influence on prognosis as to life.

Case Report: We report the case of 81 year old women which was diagnosed due to nonspecific symptoms. Laboratory investigation reveals hypercalcaemia, high C-reactive protein, and urinary tract infection with leucocyturia, erythrocyturia, bacteriuria. Ultrasonography of the abdomen exposes hypo-echoic area in the inferior pole of the left kidney. CT scanning discloses hypodensive and poorly enhancing masses in this region. The diagnosis of primary renal lymphoma, diffuse large B-cell type was established, thanks to histological examination of biopsy material. After surgical intervention patient started polychemotherapy.

Conclusions: Although primary renal lymphoma is an uncommon disease it should be included in the differential diagnosis for renal masses. That procedure could accelerate correct diagnosis and treatment, which in the future could make better prognosis as to life.

Key words: primary renal lymphoma • renal lymphoma • renal tumor • computer tomography

PDF file: http://www.polradiol.com/fulltxt.php?ICID=887308

Primary Renal Lymphoma is a very rare pathology. There is no doubt that in kidney there can exist secondary renal lymphoma. The possibility of existence of primary renal lymphoma is controverted by some authors as normally kidney does not have lymphatic tissue [1–4]. However, in world literature describes the cases of PRL and etiopathogenesis hypothesis [3–5]. The most common type is a diffuse large B-cell type, less frequently non-Burkitt lymphoma and anaplastic T-cell lymphoma. Primary renal lymphoma is very malignant tumor and therapeutic algorithm has not been established yet. The longest survival time has been observed in patients after total nephrotomy combined with polychemotherapy.

In our article we describe the case of primary renal lymphoma with infiltration renal capsule and peritoneum, as well as we make a review of literature.

## Case Report

In October 2007, an 81-year-old woman was admitted to internal diseases department in District Hospital in Krasnystaw, due to nonspecific symptoms. The main aliments were: weakness, loss of appetite, weight loss – 7 kg in last 2 months, fever for 2 weeks. She had also high arterial blood pressure. In medical history it was found: diabetes type 2, cholecystolithiasis and status after left mastectomy due to mastocarcinoma. Laboratory test revealed: hyperglycemia, hypocalcaemia and increasing level CRP protein. Urine analysis showed leucocyturia, erythrocyturia, bacteriuria, candida-infection and Escherichia-Coli infection. Serum chemistry panel such as: bilirubin, creatinine, diastase, lipase, protein, albumin, sodium, potassium, morphology were correct.

Abdominal USG demonstrated enlargement of the inferior pole of left kidney, with oval, hypoechoic area (Figure 1).

Computer Tomography revealed the enlargement of the inferior pole of left kidney, oval hypodense area, about size: 6.6×7.4 cm (Figure 2), which showed lower attenuation than normal kidney (Figure 3), even in delayed section. Left kidney pyelocalycal system was deformed, while inferior calyx

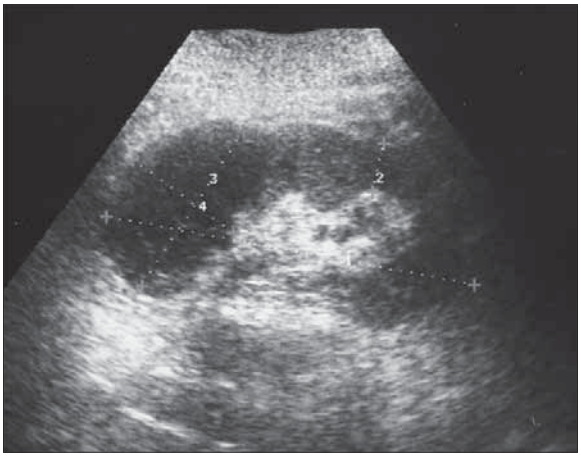

**Figure 1.** USG image. Oval hypoechogenic area in enlargement lower pole of left kidney.

**Figure 2.** Axial CT scan. Enlargement lower pole of left kidney, present homogenous mass and no-differentiation between renal hilus and renal parenchyma. Streak tissue within surrounding adipose tissue and minimal thickening Gerota's fascia.

complex was totally clasped. Adipose capsule of the kidney in inferior pole area had higher density, small multiple masses and thickening Gerota's fascia, which could point at infiltration of this pathological process to neighboring tissue (Figures 3–5). We also demonstrated a tissue streak within surrounding adipose tissue, which suggested a possibility of peritoneum infiltration (Figure 5) The degree of enlargement of the inferior pole in left kidney was well-seen in MPR – multiplanar reconstrution and VRT – volume rendering techinque (Figures 6,7). A big cyst was found in the liver.

Patient had the operation – left nephrotomy. Macroscopic inspection showed a big tumor and infiltration surrounding tissue including peritoneum in ascending colon area. Histological examination showed a diffuse, large B-cell lymphoma (REAL classification). The immune-phenotype was CD 20+, bcl 2+, CD 43–, Ki67, which suggested anaplastic variant of lymphoma. Infiltration of tumor was observed in vascular peduncle too. After operation the patient was treated with polychemotherapy.

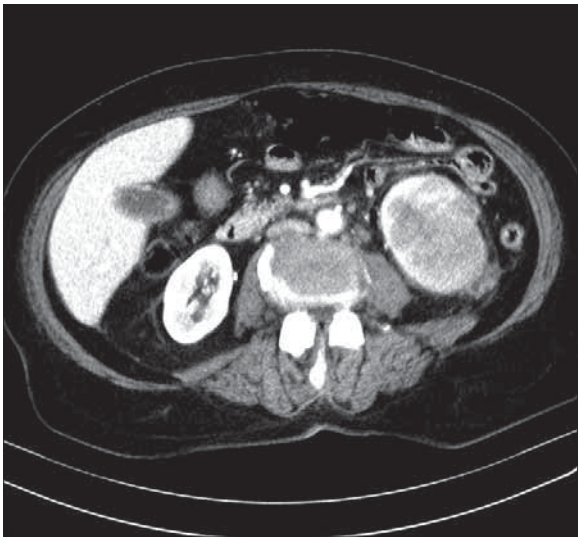

**Figure 3.** Axial CT scan after intravenous contrast. Pathological mass in a lower pole of left kidney shows lower enhancement than in renal parenchyma.

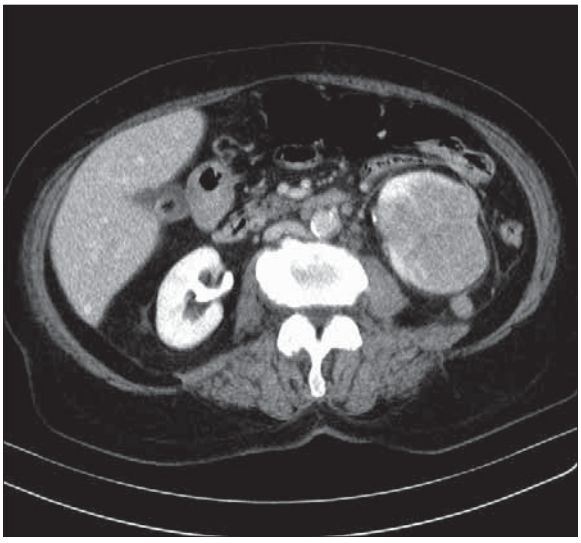

**Figure 4.** Axial CT scan after intravenous contrast – delayed view. Low-enhancement of pathological mass in lower pole of left kidney, is still present on slices.

## Discussion

Primary Renal Lymphoma, just the opposite to Secondary Renal Lymphoma is very rare. Renal manifestation in Non-Hodkin Lymphoma is described in literature from 34% to 62% [2,3,6–8]. According to Nephrology Dialisis Transplantation primary type constitutes 1% cases of renal lymphoma [1,3,4,6,7,9].

PRL is mainly detected in over 60 year old person. In our case the person was in 9$^{th}$ decade of life. However, PRL can occur at any age. We can find this lymphoma in the children group too [10,11]. Lymphoma does not have higher frequency of prevalence, depending on human race and sex, but we can see PRL more often in male population [6]. Special group are patients with immune deficiency. PRL, generally non-Burkitt and immunoblastic type, occurs more often in such cases than

**Figure 5.** Axial CT scan after intravenous contrast. Low-enhancement tissue area within renal adipose tissue and thicken Gerota's fascia. Linear tissue streak inside peritoneal adipose tissue.

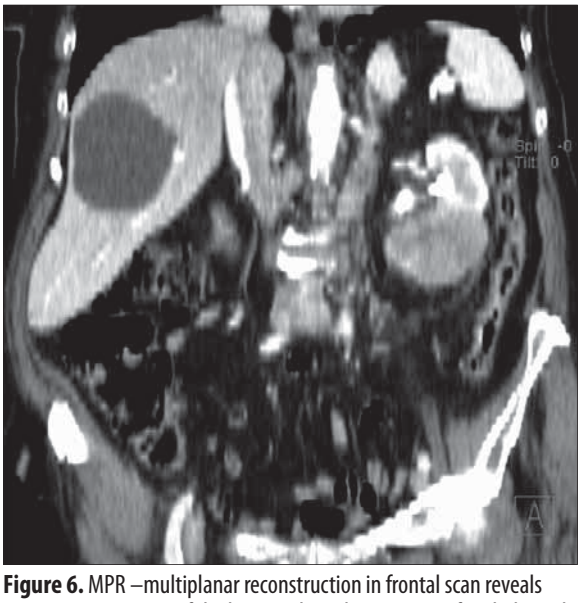

**Figure 6.** MPR – multiplanar reconstruction in frontal scan reveals expansion of the lower pole and immensity of pathological tissue mass. Liver cyst.

in patients with normal immune system [6]. Etiopathogenesis of PRL has not been established yet. Normally, kidney does not contain lymphoid tissue, that is way some authors call into question a possibility of PRL's existence [3–6]. Freemen at al. make a hypothesis that precursor is a specific pathological proliferative response of lymphoid tissue which is collected on kidney during preexisting inflammatory process [3,12,14]. As a confirmation of this hypothesis we have a recent report of relationship between Helicobacter Pylori infection of the stomach and gastric lymphoma, Hashimoto inflammation and thyroid lymphoma, chronic sialadenitis and lymphoma in this organ [3,4,13]. Another hypotheses have been proposed, e.g. that because renal capsule is rich in lymphatics, the tumor is able to penetrate the renal parenchyma or that lymphoma of nodes of kidney sinus can infiltrate into the kidney parenchyma [3,10].

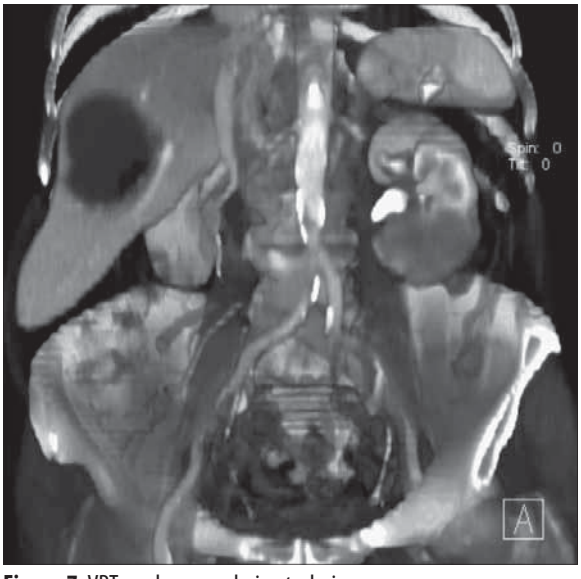

**Figure 7.** VRT – volume rendering technique.

Malbrain et al devised diagnostic criteria of PRL:
- Renal failure as the initial presentation.
- Rapid improvement of renal function after therapy.
- Bilateral enlargement of the kidneys without the obstruction of urinary tract.
- Absence of lymphoma in another localization.
- Diagnosis made by renal biopsy.
- Absence of a leukaemic blood picture [1,9,15,16].

In our case we found only hypercalcaemia, other criteria were fulfilled. Patients with PRL have nonspecific symptoms like: chronic fatigue, gradual onset of fever, hyperidrosis, sick, weight loss, paleness, emaciation, abdominal pain, lumbago, hypertension [1,4,9]. We can often identify high serum creatinine, blood urea nitrogen, lactic dehydrogenase levels and hematuria, pyuria, leucocyturia. However these changes may not appear, like in our case [3,5,6]. Some patients have acute or chronic renal failure [17,18].

In diagnostics and evaluation of stadium of lymphoma the numerous diagnostic studies are conducted such as: urography, ultrasonography, CT and MRI scanning, nuclear medicine. However final diagnosis is established by biopsy.

**Renal biopsy** is suggested to diagnosis of PRL [6,8,9]. As renal tumor occurs more often there is a higher probability to transplant carcinoma cells among needle canal. Therefore histopathological examination evaluates the organ and neighboring tissues which are excised, sometimes conducting an intra-operative histopathological examination. Biopsy is recommended in patients with established lymphoma and with focal lesions [1,4,8,19–22]. In the most cases of renal lymphoma (about 80%), like in our case, diffuse large B- cell lymphoma with diffuse growth pattern is diagnosed [8,9]. Another type of lymphoma are non-Burkit's lymphoma, follicular-small lymphocytic and plasmacytoid which occur in 20% cases [8,9].There are some reports about primary anaplastic T-cell lymphoma (T-ALCL) (about 3%) [5].

**Ultrasonography** often demonstrates non-specific images. It can occur single or multiple hypoechoic masses, it some-

times looks like a simple or complicated cyst. If lymphoma involves perirenal area, there will be a characteristic hypoechoic halo. Usually the kidney is enlarged with heterogeneous low-echogenicity and blurred cortex-medulla diversity.USG is used in evaluation of hydronephrosis due to obstruction of renal hilus and urinary tract by lymphomatic mass. Frequently renal lymphoma is invisible owing to a small size [2,6,23,24,25].

**Urography** is used for the assessment of secretory renal function, urinary retention or hydronephrosis and pyelocalyceal anatom**.** Big renal masses can distort pyelocalyceal system [6,26].

Renal Lymphoma is a hypovascular tumor, that is why the diagnostic value of **angiography** is low with high rate of false-negative diagnoses [6,24].

**Nuclear Medicine** especially with Gallium-67 citrate, has high sensitivity. But it is important to know that this radioisotope can be accumulated in lymphomatous tissues and also in inflammatory masses [6,25]. When imaging and establishing the stage of lymphoma it is recommended to use technetium-99m ($^{99}$Tc) – labeled antibody (LL2). Sensitivity testing with LL2 and Gallium-67 citrate is approximately 80%, however in patient with high-grade lymphoma there is a higher degree of sensitivity [6,25]. 18F-fluorodeoxyglucose (FDG) positron emission tomography (PET) has high, but not absolute specificity for lymphoma. This radioisotope can be also accumulated by healthy patients. None the less, nonpathological accumulation caused usually by inflammatory process, can be quickly corrected [6,27].

**Computer Tomography (CT)** with intravenous contrast has a very high degree of confidence. If enhancement cannot be used due to renal failure or allergy to contrast, the MRI investigation will be suggested. For patients with pathological mass suspicion CT is recommended. It enables staging with perirenal space assess and evaluation of treatment [6,7,24,28]. According to Ambos et al. [26] we can classify pathological lymphomatous mass into four different types:

1. Solitary nodule, with the size up to 15 cm, which can cause enlargement and deformation of kidney. Typical tumor is hypovascular and low-enhanced by contrast. For differentiation we should include isolated renal metastasis.
2. Multiple nodules-multifocal changes, size from one to three cm., with low-enhancement. Changes are typically visible in renal cortex and give a lobulated view. Usually they are bilateral, however we can meet also unilateral. This pattern appears in approximately 60% cases.
3. Diffuse infiltrative. Mostly bilateral. Establishing the diagnosis is frequently difficult owing to nephromegaly and because disease usually has miniature symptoms in spite of renal failure.
4. Kidney engulfed by contiguous retroperitoneal disease. Generally it is manifested as oval, retroperitoneal mass which infiltrates vascular and renal hilus, urinary retention. Rarely this type looks like hypodense retroperitoneal masses without evident renal infiltration.

The most frequent type are multiple nodules, over 50% cases. The rest of patterns occur together approximately 20%.

In our case we diagnose PRL type 1 ac. Ambos et al.

Moreover we can see another nonspecific changes like: spontaneous hemorrhage, necrosis, heterogeneous attenuation, cystic transformation and calcifications. Often this changes are the results of previous treatment [6].

It is very important to give contrast, which depending on enhancement phases allows to assess renal structures. Lymphoma masses have low attenuation but have higher density than fluid. Whereas, as opposed to primary renal cancer, lymphomatous infiltration is homogenous and does not have as much enhancement. It can be also heterogeneous with low density, and then is similar to a complicated cyst [6,8,24].

**MRI imaging** of renal lymphoma, which is similar to CT imaging, allows to estimate the size of lymphoma, tumor kidney signal intensity on T1- and T2-weighted images, as well as to depict localization and grading. Usually lymphoma has low-signal in T1-weighted images. Dynamic and conventional T1-weighted CT-scanning after paramagnetic contrast injection shows a diminutive enhanced signal of intensity of lesion. Untreated tumor can be enhanced but not as much as normal renal parenchyma. In T2-weighted images, PRL is either isointense or moderately hyperintense, rarely hypointense [6,24,29,30].

PRL is highly aggressive behavior entity. Optimal therapeutic algorithm has not been established yet. Intensive chemotherapy following radical nephrotomy seems to be the treatment of choice. It could be followed by radiotherapy. Polychemotherapy should be applied as soon as it is possible from the moment of diagnosis, which gives a chance to avoid dissemination of primary process [9,10].

The prognoses are poor, because lymphoma has very quick dissemination and high malignancy. Up to 75% patients die during the year after the operation, but long-term survivors have been reported occasionally after surgical resection and combined chemotherapy in unilateral lymphoma. In bilateral cases prognoses are serious and the only treatment is chemotherapy [1,4,26].

## Conclusions

Primary renal lymphoma, despite very rare occurrence, should be included in the differential diagnosis for renal masses, especially tumor with low-enhancement in CT. We think, that CT with contrast is the examination of choice in diagnostic PRL. It allows identification, differentiation and staging. We should remember about high malignancy of PRL, which causes that each delay in radical treatment deteriorates prognosis that are generally poor. Comprehensive treatment of patient with PRL, including co-operation with many specialists, could improve the prognosis.

## References:


1. Cupisti A, Riccioni R, Carulli G et al: Bilateral primary renal lymphoma treated by surgery and chemotherapy. Nephrol Dial Transplant, 2004; 19: 1629–33
2. Ozaltin F, Yal B, Orhan D et al: An unusual cause of acute renal failure: renal lymphoma. Pediatric Nephrology, 2004; 19: 912–14
3. Okuno SH, Hoyer JD, Ristow K et al: Primary Renal Non- Hodgkin's Lymphoma. An Unusual Extranodal Site. Cancer 1995; 75: 2258–61
4. Stallone G, Infante B, Manno C et al: Primary renal Lymphoma does exist. Case report and review of the literature. JNEPHROL, 2000; 13: 367–72
5. Venizelos ID, Rombis V, Tulupidis S et al: Primary Anaplastic Large Cell Lymphoma of the Kidney. Leukemia and Lymphoma, 2003; 44: 353–55
6. Shirkhoda A: Kidney, Lymphoma, *http://www.emedicine.com/radio/TOPIC373.HTM* (accessed 03.07.2008)
7. Yunus SA, Usmani SZ, Ahmad S et al: Renal involvement in non-Hodkin's lymphoma: the Shaukat khanum experience. *http://www.ncbi.nlm.nih.gov/pubmed/17696740* (accessed 10.07.2008)
8. Bruce A, Urban MD, Elliot K et al: Renal lymphoma: CT patterns with Emphasis on Helical CT. RadioGraphics, 2000; 20: 197–212
9. a Omer H, Hussein MR: Instructive Case. Primary renal lymphoma. Nephrology, 2007; 12: 314–15
10. Chepuri NB, Strouse PJ, Yanik GA: CT of renal lymphoma in children. *http://www.ncbi.nlm.nih.gov/pubmed/12540447* (accessed 10.07.2008)
11. Buyukpamukçu M, Varan A, Aydin B et al: Renal involvement of non-Hodgkin's lymphoma and its prognostic effect in childhood. Nephron Clin Pract, 2005; 100: 86–91
12. Dunay PN: Linfosarcoma y linfosarcomatosis des los rinones: paort T Rev Med Trop Parasitol Clin Lab, 1940; 6: 213
13. Parsonnet J, Hansen S, Rodriguez L et al: *Helicobacter pylori* infection and gastric lymphoma. N Engl J Med, 1994; 330: 1267–71
14. C Freeman, JM Berg, SJ Cutler: Occurrence and prognosis of extranodal lymphomas. Cancer, 1972; 29: 252–60
15. Malbrain ML, Lambrecht GL, Daelemans R et al: Acute renal failure due to bilateral lymphomatous infiltrates. Primary extranodal non-Hodgin's lymphoma (p-EN-NHL) of the kidneys: does it really exist? Clinical Nephrology, 1994; 42: 163–69
16. Sieniawska M, Bialasik D, Jedrzejowski A et al: Bilateral primary renal Burkitt lymphoma in a child presenting with acute renal failure. Nephrol Dial Transplant, 1997; 12: 1490–92
17. Baldus M, Klooker R, Kress S et al: Primary bilateral renal centrocytic non Hodkin's lymphoma as a cause of renal failure. Nephron, 1996; 73: 86–90
18. Van Gelder T, Michelis J, Mulder A et al: Renal insufficiency due to bilateral primary renal lymphoma. Nephron, 1992, 60: 108–10
19. Hunter S, Samir A, Eisner B et al: Diagnosis of renal lymphoma by percutaneous image guided biopsy: experience with 11 cases. J Urol, 2006; 176: 1952–56
20. Ravinsky E, Morales C: Diagnosis of lymphoma by image-guided needle biopsies: fine needle aspiration biopsy, core biopsy or both? Acta Cytol, 2005; 49: 51–57
21. Qiu L, Unger PD, Dillon RW et al: Low- grade mucosa- associated lymphoid tissue lymphoma involving the kidney: Report of 3 cases and revive of the literature. Arch Pathol Lab Med, 2006; 130: 86–89
22. Truong LD, Caraway N, Laurica R et al: Renal Lymphoma. The diagnostic and therapeutic roles of fine- needle aspiration. Am J Clin Pathol, 2000; 115: 18–31
23. Shirkhoda A, Staab EV, Mittelstaedt CA: Renal lymphoma imaged by ultrasound and gallium -67. Radiology, 1980; 137: 175–80
24. Sheth S, Ali S, Fishman E: Imaging of Renal lymphoma: patterns of Disease with Pathologic Correlation. RadioGraphics, 2006; 26: 1151–68
25. Becker AM, Bowers DC, Marggraf LR et al: Primary renal lymphoma presenting with hypertension. Pediatric Bllod Center, 2007; 48: 711–13
26. Zafar S, Jafri H, Bree RL et al: CT of renal and Perirenal Non-Hodin Lymphoma. AJR, 1982; 138: 1101–5
27. Castellucci P, Zinnaci P, Pourdehnad M et al: 18F –FDG PET in malignant lymphoma: significance of positive findings. Eur J Nucl Med Mol Imaging, 2005; 32: 749–56
28. El-sharkawy MS, Siddiqui N, Aleem A et al: Renal involvement in lymphoma; prevalence and various patterns of involvement on abdominal CT. Int Urol Nephrol, 2007; 39: 929–33
29. Semelka RC, Kelekis NL, Burdeny DA et al: Renal Lymphoma: Demonstration by MR Imaging. AJR, 1996; 166: 823–27
30. Iselin CE, Leder RA, Lacey J et al: Renal lymphoma in an azotemic patient-usefulness of magnetic resonance imaging. Scand J Urol Nephrol, 1999; 33: 129–30