Signature: © Pol J Radiol, 2009; 74(2): 35-38

Polish Journal of Radiology
www.PolRadiol.com

ORIGINAL ARTICLE

Received: 2008.09.29
Accepted: 2009.03.13

An estimation of the goiters by means of ultrasonography and scintigraphy (SPECT) using ^{99m}Tc

Marcin Gierach[1], Joanna Gierach[1], Stanisław Pilecki[1], Małgorzata Pujanek[1], Roman Junik[1], Władysław Lasek[2]

[1] Laboratory of Nuclear Medicine of The Department of Endocrinology and Diabetology, Nicolaus Copernicus University in Toruń, Collegium Medicum in Bydgoszcz, Bydgoszcz, Poland
[2] Department and Institute of Imaging Diagnostics, Nicolaus Copernicus University in Toruń, Collegium Medicum in Bydgoszcz, Bydgoszcz, Poland

Author's address: Marcin Gierach, The Department of Endocrinology and Diabetology of The Ludwik Rydygier Collegium Medicum in Bydgoszcz, University of Nicolaus Copernicus in Toruń. ul. M. Skłodowskiej-Curie 9, 85-094 Bydgoszcz, Poland, e-mail: marcin_gierach@wp.pl

Summary

Background: The thyroid is the large, single and usually asymmetric endocrine gland consisting of two lateral lobes joined by the isthmus. A thyroid volume over 18 ml in females and 25 ml in males is called goiter. Among the methods evaluating the volume of the thyroid we can submit ultrasonography (US) and scintigraphy (SPECT). The aim of the study was to estimate the volume of goiters by means of US and ^{99m}Tc-SPECT.

Material/Methods: A group of 80 patients were examined. Patients were divided into two groups. Group A contained 50 patients (43 females, 7 males) with goiter, where the volume of the thyroid was compared with the use of US and ^{99m}Tc-SPECT. Group B contained 30 patients (23 females, 7 males) with a normal volume of the thyroid gland as shown by US and ^{99m}Tc-SPECT.

US of the thyroid gland was made by means of the ALOKA SSD 500 device, with a linear head of 7.5 MHz. ^{99m}Tc-SPECT was made by means of a one head gammacamera Diacam with a low energy high resolution collimator (LEHR).

Results: In both groups similar results were obtained. In the group A, the average volume of the goiter was 29.83 ml in US and 33.27 ml in SPECT ($p<0.001$). In the control group B the average volume of the thyroid gland was 16 ml and 18.18 ml ($p<0.001$), respectively

Conclusions: The thyroid volume estimated by ^{99m}Tc-SPECT was significantly higher than that by US, in both investigated and control groups, and in females and males.

Key words: goiter • US • SPECT • ^{99m}Tc

PDF file: http://www.polradiol.com/fulltxt.php?ICID=887302

Background

The thyroid is the large, single and usually asymmetric endocrine gland consisting of two lateral lobes joined by the isthmus [1]. The thyroid mass in adults is about 15–30 g and it is higher in women as compared to men. The average lobe is 4–5 cm high, 2–3 cm wide and 1,5–2 cm thick. The normal thyroid volume not to exceed in females is 18 ml and in males – 25 ml. Enlargement of the thyroid is called goiter. Among the methods evaluating the volume of the thyroid we can submit ultrasonography (US) and scintigraphy (SPECT). The US method is characterized by a perfect distribution (1 mm). This method is cheap and not invasive [2,3]. Scintigraphy is a method estimating morphology and, in an indirect way, a thyroid function. Scintigraphy enables an evaluation of the location of thyroid tissue, the size and shape of thyroid. This method also enables an estimation of the content of a radioisotope in the thyroid. In the radioisotope diagnostic the main three radiotracers such as ^{99m}Tc, ^{123}I and ^{131}I are used. Nowadays technetium (^{99m}Tc – generator radioisotope) is the

Table 1. Comparison of thyroid volume using US and SPECT ^{99m}Tc.

	Sex	N	US				SPECT 99mTc				Differences of mean measurements	p
			Mean volume (ml)	SD	Min	Max	Mean volume (ml)	SD	Min	Max		
Studied group	F+M	50	29.83	10.63	18.36	59.56	33.27	10.52	19.84	59.76	3.44	<0.001
	F	43	29.35	10.92	18.36	59.56	32.61	10.31	19.84	59.05	3.27	<0.001
	M	7	32.83	8.05	26.61	47.05	37.34	10.89	29.26	59.76	4.52	<0.01
Control group	F+M	30	16.00	4.06	8.62	23.75	18.18	3.58	11.24	24.56	2.17	<0.001
	F	23	14.42	3.17	8.62	17.5	16.51	2.14	11.24	17.95	2.09	<0.001
	M	7	21.21	1.56	19.5	23.75	23.66	0.80	22.54	24.56	2.45	<0.001

most popular of those radiotracers. It is not a specific radiotracer for the thyroid due to its accumulating also in salivary glands, facial mucous membrane and stomach, and in the choroid plexus of brain ventricles. Technetium is mainly excreted by the urinary system. Technetium (pertechnetium) (^{99m}Tc) has profitable physical characteristics. Its half-life is about 6 hours and its gamma radiation energy is 140.5 keV.

Single photon emission computed tomography (SPECT) enables the presentation of every organ in three dimensions. The estimation of a thyroid volume is done by recording a series of pictures (by 360° rotation of a one head gammacamera) and next the pictures are reconstructed by using the computer program [4].

Aim

The aim of the study was to evaluate the volume of a goiter by means of ultrasonography and SPECT using ^{99m}Tc.

Material and Methods

A group of 80 patients was studied. Patients were admitted to the Endocrynological Out-patient Clinic and to the Department of Endocrinology and Diabetology of Collegium Medicum in Bydgoszcz. Patients were divided into two groups. Group A contained 50 patients (43 females, 7 males) with goiter, where the volume of the thyroid was compared with the use of US and ^{99m}Tc-SPECT. Group B contained 30 patients (23 females, 7 males) with a normal volume of the thyroid gland as shown by US and ^{99m}Tc-SPECT. The group B was the control group. All the patients underwent a thyroid examination by US and SPECT using ^{99m}Tc. Ultrasonography of the thyroid gland was made by means of the ALOKA SSD 500 device, with a linear head of 7.5 MHz. Volume of every thyroid lobe was calculated by means of Gutekunst's formula: V=0.5 × length × width × thickness [5]. The obtained results were added to give the volume of the thyroid gland. The volume of the thyroid isthmus was not taken into consideration. ^{99m}Tc-SPECT was made by means of a one head gammacamera Diacam with a low energy high resolution collimator (LEHR).

Technical parameters of the equipment: rectangular crystal, matrix 128×128, zoom 1.00; spectrum of detector: 31×41 mm, axis of detector: 51 cm, number of photo printers: 59, capability of object's shape evaluation, FWHM of detector <3.8cm. SPECT acquisition was carried by elliptical course (360 degrees). 64 frames each for 30 second were made. The study lasted 32 minutes [6].

Results

The volume of thyroid estimated by means of the scintigraphy method with ^{99m}Tc (SPECT) was larger as compared to that by the ultrasonography method in both the studied and control groups. Similar observations were made on all of the groups of the men and women studied. Differences of the volume measurements were statistically significant (Table 1).

The groups, studied and control, were divided into subgroups depending on age: 20–39 years, 40–59, 60–79 and >80 years. In the studied subgroups 40–59 and 69–79 a significantly higher volume values of thyroid in scintigraphy with ^{99m}Tc (SPECT) as compared to US was observed. In the subgroups 20-39 and >80 there were not any significant statistical differences (Figure 1). In the control group, in the subgroups 20–39, 40–59 and 60–79 there were significantly higher thyroid volume values using ^{99m}Tc (SPECT) as compared to US. However, there were no statistically significant differences in the control subgroup >80 (Figure 2). The studied groups of patients were divided into 2 subgroups as regards the goiter size. In the subgroup 1 (thyroid volume to 40 ml) there were significantly higher values of the thyroid volume in scintigraphy using ^{99m}Tc (SPECT) as compared to ultrasonography. However, in the second subgroup (thyroid volume between 40 and 100 ml) there were not any statistically significant differences in the thyroid volume in scintigraphy using ^{99m}Tc (SPECT) and ultrasonography (Figure 3).

Discussion

Nowadays, there are some methods which are able to estimate the size of a thyroid, such as conventional radiology methods, ultrasonography, radioisotope methods – planar scintigraphy and SPECT, transmission computed tomography (CT), nuclear magnetic resonance (NMR) and positron emission tomography (PET). There are a lot of tests estimat-

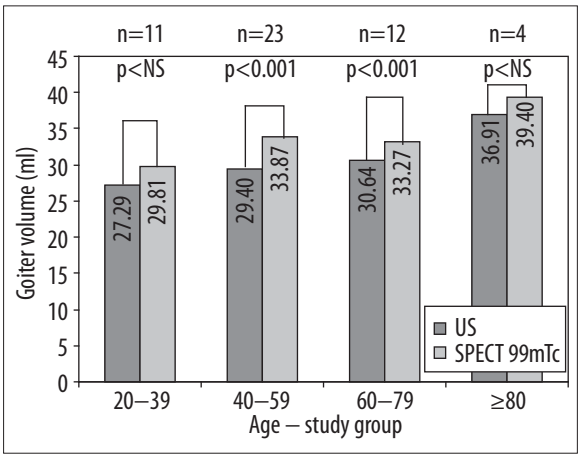

Figure 1. Comparison of thyroid volume using US and SPECT ^{99m}Tc depending on patient age (studied group).

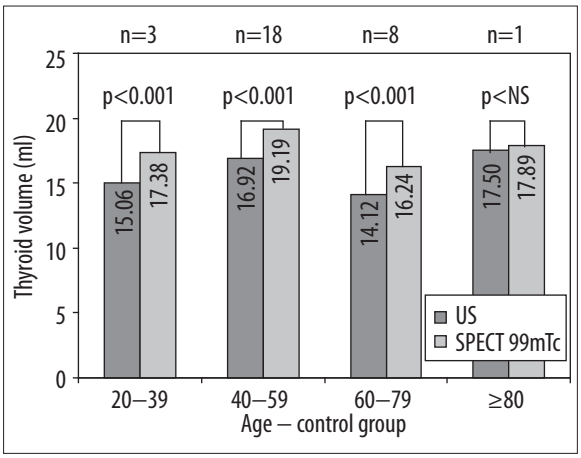

Figure 2. Comparison of thyroid volume using US and SPECT ^{99m}Tc depending on patient age (control group).

ing the thyroid volume using methods mentioned above. Researchers try to compare all these methods. The most often used method of estimating a thyroid volume in US ultrasonography. This method is more popular, cheap and not invasive than the others [2,7–9]. The ultrasonography method can be used in all patients, however, in some cases other methods, like scintigraphy, are more precise.

In some reports there are a lot of studies concerning the usefulness of scintigraphy, especially SPECT, in estimating thyroid size. Pant and co-authors [10] said that SPECT was the best method to state the thyroid volume.

In our study, in both groups, analyzed and control, the volume of thyroid was higher in scintigraphy by means of ^{99m}Tc (SPECT) as compared to ultrasonography. Difference of the mean measurement of the thyroid volume between US and SPECT was 3.44 ml (29.83 vs 33.27; $p<0.001$), however, in the control group it was 2.18 ml (16.0 vs 18.18; $p<0.001$). The differences of mean measurements had statistical significance both for the whole group and separately for women as well as men. There are many reports in which the thyroid volume is compared using two methods US and SPECT. Isselt and co-authors [11] estimated the thyroid volume using planar scintigraphy, ultrasonography and SPECT. They compared thyroid

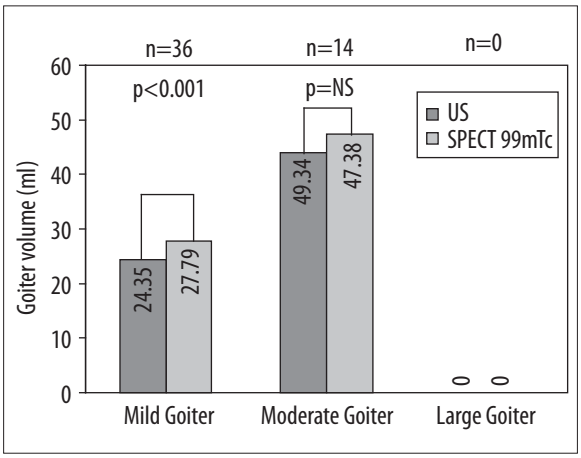

Figure 3. Comparison of thyroid volume using US and SPECT ^{99m}Tc depending on thyroid size.

volumes using methods mentioned above and magnetic resonance which was a standard, as they claimed of estimating the size of thyroid. Twenty five patients with Graves' disease were included in the study. The mean value of the goiter size using MRI was 33.9 ml. In SPECT and US, the mean value of the thyroid size was lower and was 29.6 and 26.1 ml, respectively. Inaccurate size of thyroid using US was also observed in the earlier studies [8,12]. Reinartz and co-authors [7] compared US method to MRI as well. They affirmed the lower values of the thyroid volume in ultrasonography at 80%. In this study the thyroid size values using US with the ellipse method as compared to values using planimetric MRI differed about 22.7%, regardless of the thyroid size.

In our study the significantly higher values of the thyroid volume in ^{99m}Tc (SPECT) as compared to US were obtained in the group of patients with a smaller sized goither (volume to 40 ml). However, in the group of patients with a larger goiter the differences in the thyroid volume in US and ^{99m}Tc (SPECT) were not statistically significant. In the previous studies, in which the thyroid volume was estimated by means of the various picture imaging method the largest differences were observed in the small size goiters. Isselt and co-authors [11] compared methods of thyroid imaging such as MRI, SPECT and US and said that the biggest differences in the thyroid volume measurements had been in the group of patients with the thyroid volume <15 ml and they had been decreasing according to an increase of the thyroid volume. The results of our study and Isselt's study can be a result of the limited resolution of scintigraphy. The small resolution and the small thyroid volume can influence the higher values of thyroid size in SPECT as compared to ultrasonography.

In all the groups, according to age, the thyroid volume was larger in SPECT as compared to US. However, in patients who are 60 and above in the studied group, and in patients who are 80 and above in the control group, this difference between SPECT an US was not statistically significant.

Conclusions

The thyroid volume estimated by ^{99m}Tc-SPECT was significantly higher than that by US, in both investigated and control groups, and in females and males.

References:

1. Ahidjo A, Tahir A, Tukor MA: Ultrasound determination of thyroid gland volume among adult Nigerians. Internet J Radiol, 2006; 4(2): 12–16
2. Ozgen A, Erol C, Kaya A et al: Interobserver and intraobserver variations in sonographic measurement of thyroid volume in children. Eur J Endocrinol, 1999; 140: 328–31
3. Nygaard B, Faber J, Veje A et al: Thyroid volume and function after ^{131}I treatment of diffuse non-toxic goitre. Clin Endocrinol, 1997; 46: 493–96
4. Murase K, Tanada S, Yasuhara Y et al: SPECT volume measurement using an automatic threshold selection method combined with a V filter. Eur J Nucl Med, 1989; 54: 21–25
5. Gutekunst R, Smolarek H, Hasenpusch U et al: Goiter epidemiology: thyroid volume, iodine excretion, thyreoglobulin and thyreotropin in Germany and Sweden. Acta Endocrinol, 1986; 112: 494–501
6. Chen JJ, LaFrance ND, Allo MD et al: Single photon emission computed tomography of the thyroid. J Clin Endocrinol Metab, 1988; 66(6): 1240–46
7. Reinartz P, Sabri O, Zimny M et al: Thyroid volume measurement in patients prior to radioiodine therapy: comparison between three-dimensional magnetic resonance imaging and ultrasonography. Thyroid, 2002; 12(8): 713–17
8. Knudsen N, Bols B, Bulow I et al: Validation of ultrasonography of the thyroid gland for epidemiological purposes. Thyroid, 1999; 9: 1069–74
9. Hegedus L: Thyroid size determined by ultrasound. Influence of physiologial factors and non – thyroidal disease. Danish Med Bulletin, 1990; 37(3): 249–63
10. Pant GS, Kumar R, Gupta AK et al: Estimation of thyroid mass in Graves' disease by a scintigraphic method. Nucl Med Commun, 2003; 24(7): 743–48
11. Van Isselt JW, De Klerk JM, van Rijk PP et al: Comparison of methods for thyroid volume estimation in patients with Graves' disease. Eur J Nucl Med and Mol Imaging, 2003; 30(4): 525–31
12. Szebeni A, Beleznay E: New simple method for thyroid volume determination by ultrasonography. J Clin Ultrasound, 1992; 20(5): 329–37