

Langer mesomelic dysplasia in a Chinese woman (case report)

A. Baxova¹, K. Kozlowski²

¹ Department of Genetics, Second Paediatric Clinic, Charles University, Prague, Czech Republic

² Department of Medical Imaging, New Children's Hospital at Westmead, Sydney, Australia

Author's Address: K. Kozlowski, Children's Hospital at Westmead, Locked Bag 4001; Westmead NSW2145, Sydney, Australia, e-mail: kazimierz.kozlowski@bigpond.com

Summary

Background: Langer type mesomelic dysplasia is a rare form among mesomelic dysplasias.

Case Report: The first case of this bone dysplasia is reported in the Polish literature.

Conclusions: Radiographic examination is the only means by which to diagnose Langer type of mesomelic dysplasia with certainty. Correct diagnosis is not only prognostic for the course of the disease and its complications, but also excludes the necessity of further, often expensive investigations.

Key words: mesomelic • mesomelic dysplasia • Langer type

Background

We report a 31 year-old Chinese woman with Langer type of mesomelic dysplasia who was diagnosed at the age of 6 years as achondroplasia. The diagnosis of Langer type of mesomelic dysplasia is easy – if the disorder is known to the researcher – as few bone dysplasias show so little variability as Langer mesomelic dysplasia.

The exact diagnosis is important as it makes all the other investigations including the biochemical tests unnecessary. It also predicts the clinical course and prognosis of the disorder. This rare bone dysplasia with diagnostic radiographic findings has also distinctive clinical history – both parents are affected by dyschondrosteosis.

Case Report

This 31 year-old patient presented with short stature and mesomelic shortening of the extremities. Her height was 107.5 cm, weight 33.3 kg and upper/lower segment ratio 68.5:38 cm. There were mandibular hypoplasia, finger contractures and mild pes cavus deformity.

Discussion

Langer type of Mesomelic Dysplasia is caused by homozygosity of deleted or mutant SHOX genes in X and Y chromosomes [1–3]. The radiographic findings are diagnostic in older children and adults. Diagnostic difficulties may occur in the first few years of life. Therefore exclusion or confirmation of dyschondrosteosis in parents – caused by deleted or mutant one SHOX gene in X or Y chromosome – may be vital, for confirmation or exclusion of the diagnosis in early childhood [3,4]. The mother was not alive at patient's presentation. The father was affected by dyschondrosteosis.

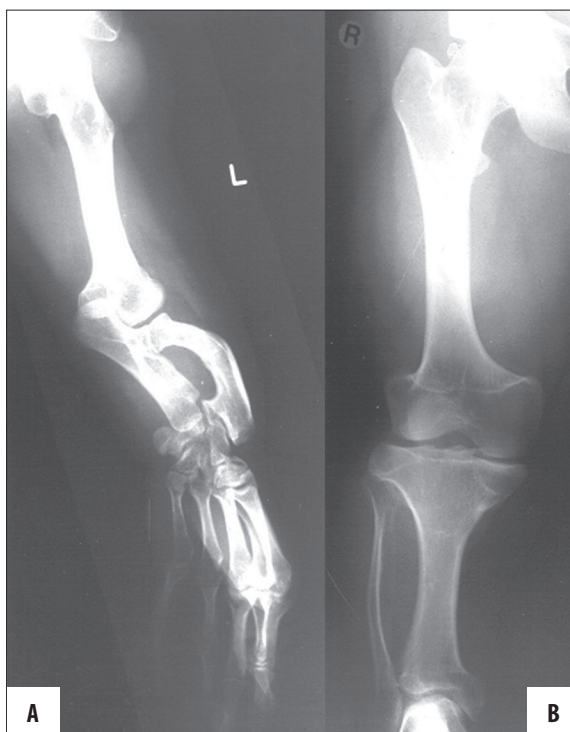


Figure 1. (A) Severe shortening of the forearm with marked hypoplastic/dysplastic ulna and radius. Widened ends of the shortened humerus. (B) Severe shortening of the leg with hypoplastic/dysplastic tibia and fibula. The fibula is thin and bowed laterally. The ends of tibia and distal femur are widened. The femur is shortened with prominent trochanters.

The **differential diagnosis** of the Langer type of Mesomelic Dysplasia is with other types of Mesomelic dysplasias [5]. Confusion is unlikely as the radiographic

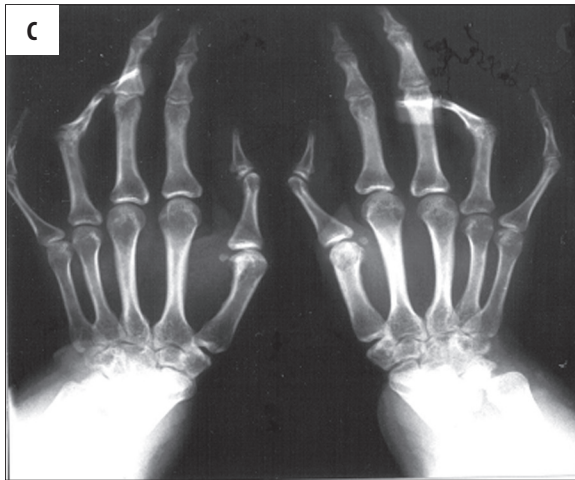


Figure 1. (C) The hands are relatively little affected. Hypoplastic/dysplastic carpal bones. Slender tubular bones. Contractures of the interphalangeal joints.

appearances of Langer mesomelic dysplasia – severe mesomelic dysplasia, mandibular hypoplasia, interphalangeal joint contractures – are incomparable (Figure 1A–C). The three severe forms of mesomelic dysplasia – Young [6], Kantaputra [7] and Vseticka [8] types – with marked mesomelic involvement, present with different appearances of

the forearm and leg bones. The Nivergelt type is characterized by rhomboid shape of the tibia, the Kantaputra type is associated with carpal/tarsal synostosis and the Vseticka form shows bowed femora. Cystic hygroma and pulmonary hypoplasia are distinctive extraskeletal associations of Vseticka type. All the other forms of mesomelic dysplasias show only mild-moderate involvement of the forearm and leg bones. Additionally the pattern of bony changes is quite different from that of the severe forms.

References:

1. Castriota-Scanderbeg, Dallapiccola B: *Abnormal Skeletal Phenotypes*. Springer Berlin, 2005; 305–7
2. Langer LO Jr: Mesomelic dwarfism of the hypoplastic ulna, fibula, mandible type. *Radiology*, 1967; 89: 654–60
3. Spranger JW, Brill PW, Poznanski A: *Bone Dysplasias*. Oxford University Press Inc, New York 2nd Ed. 2002; 336–42
4. Kozłowski K, Zychowicz C: Dyschondrosteosis. *Acta Radiologica*, 1971; 11: 459–62
5. Maroteaux P, Le Merrer M: *Maladies Osseuses de L'enfant*. Medicine-Sciences Flammarion Paris, 4th Ed, 2002; 82–89
6. Young LW, Wood BO: Nievergelt syndrome (mesomelic dwarfism – type Nievergelt). *Birth Defects Org Art Ser*, 1974; 5: 81–86
7. Kantaputra PN, Gorlin RJ, Langer LO Jr: Dominant mesomelic dysplasia, ankle, carpal and tarsal synostosis type. A new autosomal dominant bone disorder. *Am J Med Genet*, 1992; 44: 730–37
8. Vseticka J, Gattnarova Z, Marik I et al: *Am J Med Genet*, 2010; 152A: 815–18