Signature: © Pol J Radiol, 2011; 76(4): 7-14

Polish Journal of Radiology
www.PolRadiol.com
ORIGINAL ARTICLE

Received: 2011.01.23
Accepted: 2011.08.26

Usefulness of corregistration and post-processing of MR and interictal SPECT images for localization of epileptogenic focus in children – preliminary report

Jolanta Miśko[1,2], Elżbieta Jurkiewicz[3], Monika Bekiesińska-Figatowska[4], Anna Kamińska[5], Zbigniew Bachański[6], Sylwia Chełstowska[3], Jerzy Walecki[7]

[1] MRI Laboratory, Institute of Cardiology, Warsaw, Poland
[2] Department of Nuclear Medicine, Specialist Hospital in Międzylesie, Warsaw, Poland
[3] MRI Laboratory, Children's Memorial Health Institute, Warsaw, Poland
[4] Diagnostic Imaging Laboratory, Institute of Mother and Child, Warsaw, Poland
[5] Department of Nuclear Medicine, Children's Memorial Health Institute, Warsaw, Poland
[6] Neurology Department, Children's Memorial Health Institute, Warsaw, Poland
[7] Mossakowski Medical Research Centre, Polish Academy of Sciences, Warsaw, Poland

Author's address: Jolanta Miśko, MRI Laboratory, Institute of Cardiology, Warsaw, Poland

Summary

Background: Children with focal epilepsy unresponsive to anticonvulsant therapy may become surgical candidates. Inter-ictal SPECT (SPECT-IN) studies demonstrate an area of hypoperfusion within the seizure focus in up to 50% of patients. The goal of this study was to evaluate the usefulness of corregistration of MR and SPECT-IN images for localization of the epileptogenic focus.

Material/Methods: Brain MRI and SPECT-IN were performed in 20 children (mean age 9.5). We found multifocal (3–6 perfusion deficits in 10 patients) or diffuse perfusion deficits (lobar) in all patients. In fused MR and SPECT images we evaluated average activity in volumes-of-interest (VOIs) outlined in each gray matter region with deficits. Average VOI activity below average total brain activity with at least 15% difference to the mirror VOI in the brain cortex on the opposite side of was considered as "true" perfusion deficit (TPD).

Results: In all children from our group, MRI and SPECT-IN image fusion and evaluation of TPD allowed to verify most of multifocal or diffuse deficits: in each of 12 patients we found 1 TPD, in each of 6 patients 2 TPD and in each of 2 patients 3 TPD. In 8 patients with 2 or 3 TPD we used scalp EEG or ictal SPECT for identification of one probable location of epileptogenic focus.

Conclusions: In children with refractory focal epilepsy, image fusion of MRI and SPECT-IN with evaluation of TPD has potential clinical utility in localization of epileptogenic focus.

Key words: **epilepsy in infants • magnetic resonance imaging (MRI) • single photon emission computed tomography (SPECT)**

PDF file: http://www.polradiol.com/fulltxt.php?ICID=882138

Background

Epilepsy is one o the most frequent neurological disorders in children. As many as 25% of pediatric patients with epilepsy are not responsive to pharmacological treatment. Epilepsy in such cases is called "refractory" [1,2] and patients with this type of epilepsy are potential candidates for surgical treatment [3]. Unlike the adult patients in whom predominant cause of epilepsy is connected with hippocampal sclerosis and posttraumatic lesions, in children developmental abnormalities of grey matter are a common etiology [4].

When trying to determine the location of epileptogenic focus in case of multiple structural lesions of the CNS or lesions that are so discrete that remain undetected in MRI, the neurosurgeons have to decide on extensive operation procedures basing mainly on EEG data [5,6]. SPECT, assessing CNS perfusion, is one of the methods applied for localizing the epileptogenic focus when MRI remains equivocal. The evaluation of increased perfusion within the epileptogenic focus in ictal SPECT is of much greater diagnostic value then data obtained by interictal SPECT. However, performing such an examination during seizures is very often much more complicated in children as compared to adults, not only due to seizure provocation, but also due to the need for registering the examination during the next sedation in case of younger and non-cooperative patients. Interictal SPECT reveals areas of hypoperfusion within the epileptogenic focus in over 50% of patients [7–9].

The aim of the study was to assess whether the quantitative analysis of interictal SPECT within the brain gray matter areas on fused SPECT and MR images allows to identify the probable location of epileptogenic focus in children with refractory epilepsy. As a new reference value for determining perfusion deficits, apart from routinely used maximum value of cerebellar perfusion, we used mean value of global brain perfusion per unit volume.

In the past, there were attempts to increase the potential diagnostic value of MRI and SPECT in adult patients with epilepsy by corregistration of images and subtraction of ictal and interictal SPECT images [10].

At present, as a result of newly emerging software and more efficient computer analysis, the possibilities of medical image post-processing have developed. The use of new opportunities of post-processing in order to simplify the diagnostic process in children with refractory epilepsy constitutes an additional issue of our study.

Material and Methods

The study included a group of 20 patients (14 girls, 6 boys) aged 4–17 years (mean age 9.5 yrs.) who were treated with two antiepileptic drugs with poor seizure control and had normal MRI (no structural lesions) or abnormal but equivocal (multiple structural lesions – heterotopias, dysplasias, multifocal developmental malformations or postoperative lesions). An interictal SPECT (ECD 99m Tc) was performed in all patients in order to localize an epileptogenic focus before a potential surgery. The group characteristics is presented in Table 1.

In the studied group, 7 patients were diagnosed with cryptogenic epilepsy (CE) without any structural changes in brain MRI. In 11 patients MRI study revealed multiple lesions with features characteristic for heterotopia and cortical dysplasia (MCC – malformation of the cerebral cortex). In 2 patients with epilepsy, abnormal structure of brain tissue on MRI resulted from prior unsuccessful surgical treatment – hemispherectomy and multilobar resection. These patients due to postoperative changes in brain tissue structure were classified as a separate group with postoperative lesion (POOP).

MRI

MRI was performed in all patients, using 1.5 T scanners in axial projection (ax) in Talairach plane (parallel to line joining anterior and posterior commissures) as well as in coronal (cor) and sagittal (sag) projections. A routine examination protocol included SE/T1-weighted images (ax) (488/10/1) [TR-repetition time/TE-echotime/excitations], TSE/T2-weighted (ax, sag) (3920/102/1), T2FLAIR (ax, cor) (2500/9000/111/1) [IR-inversion time/TR/TE/excitations] end volumetric SPGR/T1 (cor), GRE/T2*-weighted (ax). Slice thickness was 1-5 mm. Matrix: 256×256 i 256×192, field of view: 220–230 mm. Additionally, diffusion-weighted imaging (DWI) was performed with following parameters: TR/TE-2300/73, field of view: 230 mm, matrix: 128×128, slice thickness: 5 mm, gap: 1 mm, b-values 0/500/1000 mm^2/s. In case of identified structural changes, SE/T1-weighted images were obtained after intravenous injection of paramagnetic contrast medium at a dose of 0.2 mmol/kg of body weight.

In structural images, the presence of developmental lesions was assessed visually. Thickness of brain cortex and potential blurring of gray matter – white matter junction was also analyzed in order to identify a cortical dysplasia. In all patients, neoplastic lesions and vascular malformations were excluded.

SPECT

SPECT was performed using 99mTc-ECD at a dose of 0.3 mCi/kg of body weight, injected intravenously to the patient in horizontal position, in a dark and quiet room. Acquisition was initiated 30–60 minutes after radiotracer administration. SPECT registration was performed using dual-detector gamma-camera (MULTISPECT, SIEMENS, GERMANY) with parallel-hole collimators LEHR (Low Energy High Resolution). The registration of SPECT was carried out until over 5 millions counts per scan were obtained. Matrix 128×128 was applied with angular sampling of 3 degrees using the so-called "step and shoot" method. Image reconstruction was achieved with Butterworth filter 0.4 for backward reconstruction using Chang's attenuation correction method.

Interictal SPECT was performed in all 20 patients. In interictal SPECT we looked for perfusion deficits in the cortical region, using standard semi-quantitative evaluation comparing the level of cortical perfusion to maximum number of counts within cerebellum (maxC) taken as area of reference. Assessing interictal SPECT, the brain standard perfusion deficits (SPD) were areas with the number of counts per single pixel of less than 50% maxC within the medial temporal lobe cortex, and of less than 70% of maxC within the rest of the cortex [11].

To analyze the number and location of SPD regions, a 3D reconstruction of interictal SPECT images was applied with a double cut-off level regarding the number of counts in the basic volume unit (voxel): 50% and 70% of maxC value. The 3D Viewer, a PMOD (Biomedical Image Quantification PMOD Technologies) software toolbar was used for reconstruction.

Table 1. Characteristics of the study group.

Patient initials)	Age/sex	diagnosis	MRI	Intrerictal SPECT Standard evaluation	EEG Location of the lesion
Patient 1 (SE)	7/F	MCC	Multiple lesions	++	Left hemisphere
Patient 2 (KZ)	4/F	CE	Normal	+	Left temporal
Patient 3 (KK)	10/F	CE	Normal	++	Left frontal
Patient 4 (SD)	11/F	POOP	Multiple lesions	++	Left hemisphere
Patient 5 (NS)	3/F	CE	Normal	+	Left parieto-occipital
Patient 6 (ZK)	7/F	CE	Normal	+	Right frontal
Patient 7 (PK)	5/M	CE	Normal	++	Left and right frontal independently
Patient 8 (SM)	7/M	POOP	Multiple lesions	++	Right hemisphere
Patient 9 (PM)	17/F	MCC	Multiple lesions	++	Equivocal
Patient 10 (GP)	15/F	MCC	Multiple lesions	+	Left hemisphere
Patient 11 (MA)	10/F	MCC	Multiple lesions	++	Right hemisphere
Patient 12 (WJ)	15/F	MCC	Multiple lesions	++	Right hemisphere
Patient 13 (BK)	14/F	CE	Normal	+	Left fronto-temporal
Patient 14 (HM)	7/M	MCC	Multiple lesions	+	Left frontal
Patient 15 (JK)	15/F	MCC	Multiple lesions	+	Right hemisphere
Patient 16 (KD)	11/F	CE	Normal	++	Left parieto-occipital
Patient 17 (CF)	2/M	MCC	Multiple lesions	++	Right frontal
Patient 18 (GP)	10/M	MCC	Multiple lesions	+	Right hemisphere
Patient 19 (JA)	11/F	MCC	Multiple lesions	+	Left hemisphere
Patient 20 (BB)	10/M	MCC	Multiple lesions	+	Right hemisphere

CE – cryptogenic epilepsy; POOP – epilepsy persisting after hemispherectomy or multilobar resection; MCC multifocal congenital cortex malformations, multiple lesions on MRI – gray master heterotopia, cortical dysplasia; + – 3–6 focal lesions in SPECT; ++ – multiple and diffuse lesions in SPECT.

In our group of children with epilepsy, two ictal SPECT were registered. Patients were waiting for the examination in a quiet, dimmed room, resting in lying position. The 99mTc-ECD tracer was administered intravenously without EEG supervision, at a dose of 0.3 mCi/ kg of body weight, approximately 10 seconds after seizure onset, and the acquisition was started 30-60 minutes after tracer injection. The ictal SPECT images were assessed for the presence of foci of increased metabolism/perfusion (>90% maxC).

MR and SPECT image analysis

For corregistered MR and SPECT image analysis, a method of image integration was applied, using image fusion tool PFUS (Flexible Image Matching and Fusion Tool) available in PMOD toolbar.

The T2 FLAIR MR images in axial projection (ax) were considered as referential structural data (Figure 1A). SPECT images obtained as a collection of transverse sections were fused with MR images using automatic integration algorithm that additionally allowed to fit the images from these two examinations considering anatomical reference marks. Thanks to the method of interpolation, SPECT images were not only fitted to anatomical mask of MRI, but also unified regarding spatial resolution and divided into the same number of transverse sections and the same thickness of each slice as in MRI (so-called "corregistered data") (Figure 1B).

Brain volume was assessed in fused MR and interictal SPECT cross-sections using VOI (Volume of Interest) Constructor – the tool available in PMOD software. The area of all interictal SPECT cross-sections was drawn manually with VOI Constructor and brain tissue borders were verified in MRI. Subsequently, the total volume of brain tissue (cm^3) was quantitatively assessed, as well as global (totB) and average (avB) number of counts per unit volume in the brain SPECT (gray matter, white matter and areas of cerebral fluid).

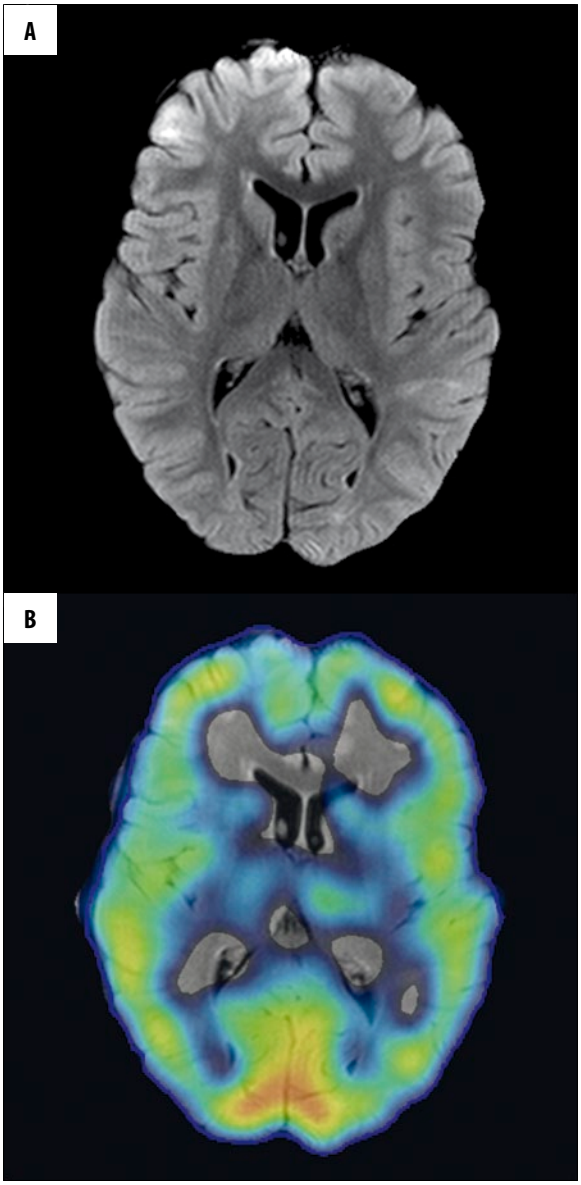

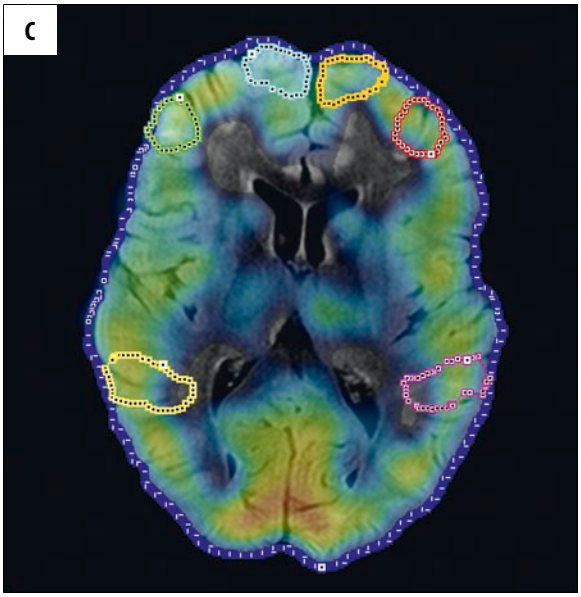

Figure 1. (**A**)– Brain MRI (transverse section in T2 FLAIR sequence) of a child with cortical and subcortical multifocal lesions. (**B**) interictal SPECT and MR image fusion of the same patient. (**C**) voxels of interest (VOIs) identified in abnormal MR areas and within corresponding regions of the opposite hemisphere. Regions were marked on the presented transverse section and transferred to adjacent cross-sections with apparent lesions on MRI and hypoperfusion on interictal SPECT.

The location of SPD changes was determined on transverse, sagittal and coronary sections obtained by fusion of MR and interictal SPECT images, using a 10-color scale for encoding interictal SPECT images to allow visualization of the cut-off levels of 50% and 70% of maxC. In each SPD region identified in interictal SPECT, a morphological verification using T2 FLAIR MR images was performed concerning the thickness of the cortex and distinction of gray matter – white matter junction. It resulted in new, anatomically modified regions of interest. Only those SPD foci/areas with perfusion deficit overlapping cortical gray matter with an area of at least 0.5 cm^3 were taken into account for the analysis (Figure 1C). Average number of counts within the anatomically verified region (avROI) was compared with avB, which was taken as a new reference value defining the boundary between normal and reduced perfusion of the brain. AvROI value in each SPD was also compared with the average number of counts in the corresponding region in the opposite cerebral hemisphere with the difference of >15% as indicating the presence of perfusion deficit.

Results

In the interictal SPECT, using the standard method of assessment, multiple SPD perfusion deficits were found in all 20 patients; ten of them had extensive (areas covering the whole lobe) or multifocal (confluent) cerebral lesions, in case of the other 10 patients the number of foci of cerebral cortex hypoperfusion varied from 3 to 6 (Table 2).

After verification of the region of interest to the area of cortical gray matter on MRI, taking avB as a cut-off level delineating border between normal perfusion and hypoperfusion and at least 15% difference in avROI as compared to the perfusion level of corresponding structure in the opposite hemisphere, we were allowed to identify "true" regions of perfusion deficit (TPD) on fused MR and interictal SPECT images.

In the group of 10 patients with extensive SPD in interictal SPECT, the aforementioned analysis of fused MR and interictal SPECT images revealed single TPD in five patients, 2 TPDs in three of them, and 3 TPDs in other two patients.

Among the other 10 patients with 3–6 SPD lesions, 7 patients showed single TPD, whereas in 3 patients two TPD were found. (Table 2).

In all 7 patients with two or three TPD lesions an additional analysis was performed based on EEG or ictal SPECT, resulting in localization of a single TPD focus. In one patient two foci, most likely epileptogenic, were identified (patient described below, from the POOP group).

Table 2. Results of neuroimaging and EEG in study group.

Patient (initials)	Diagnosis	Interictal SPECT (SPD)	Interictal SPECT (TPD) + MRI	Correlation with EEG or ictal SPECT
Patient 1 (SE) (	MCC	Multiple frontal, temporal, occipital bilaterally	1 deficit	Correlation with EEG +
Patient 2 (KZ)	CE	3 deficits	2 deficits	EEG Verification 1focus
Patient 3 (KK ()	CE	Diffuse frontal and parietal bilaterally	1 deficit	Correlation with EEG +
Patient 4 (SD)	POOP	Extensive frontal and parietal, left occipital + focuses in right hemisphere	2 deficits	Ictal SPECT 1focus
Patient 5 (NS)	CE	5 focuses	1 deficit	Correlation with EEG +
Patient 6 (ZK)	CE	4 focuses	1 deficit	Correlation with EEG +
Patient 7 (PK)	CE	Multiple in left hemisphere frontal and parietal	2 deficits	Ictal SPECT 1focus
Patient 8 (SM)	POOP	Extensive right frontal and parietal + 3 focuses in left	3 deficits	EEG Verification 2 focuses
Patient 9 (PM)	MCC	Extensive frontal and parietal bilaterally	1 deficit	Correlation with EEG +
Patient 10 (GP)	MCC	3 perfusion deficits	1 deficit	Correlation with EEG +
Patient 11 (MA)	MCC	Extensive right temporal	1 deficit	Correlation with EEG +
Patient 12 (WJ)	MCC	Extensive frontal and occipital bilaterally	1 deficit	Correlation with EEG +
Patient 13 (BK)	CE	4 deficits	1 deficit	Correlation with EEG +
Patient 14 (HM)	MCC	5 deficits	1 deficit	Correlation with EEG +
Patient 15 (JK)	MCC	4 deficits	1 deficit	Correlation with EEG +
Patient 16 (KD)	CE	Extensive frontal and parietal	3 deficits	EEG Verification 1focus
Patient 17 (CF)	MCC	Diffuse lesion – frontal, temporal and occipital	2 deficits	EEG Verification 1focus
Patient 18 (GP)	MCC	6 deficits	2 deficits	Correlation with EEG +
Patient 19 (JA)	MCC	3 deficits	2 deficits	Correlation with EEG +
Patient 20 (BB)	MCC	3 deficits	1 deficit	Correlation with EEG +

CE – cryptogenic epilepsy; POOP – postoperative epilepsy; MCC – multifocal congenital cortical malformations.

The SPECT subtraction was performed in 2 patients who underwent both ictal and interictal SPECT. Ictal/interictal SPECT subtraction images were fused with MR images using a PMOD software for medical image fusion. Superimposed images were visually analyzed and quantitatively assessed by estimating the number of counts in the region of increased metabolism/perfusion, i.e. area in which the level of perfusion compared with interictal SPECT was increased by at least 15% (when compared with the maxC value as a reference for each study).

Analysis of patients from the POOP group

In 2 patients with epilepsy and brain lesions on MRI resulting from prior unsuccessful surgery, the evaluation of the interictal SPECT only was difficult – in the whole area of resection of the cerebral tissue, a perfusion deficit of <50% maxC was found. Only the fusion of MR images and interictal SPECT allowed a precise determination of the presence of residual brain tissue in the area assessed in terms of avROI level:

1. In 1 patient after multilobar left-side resection, apart from the interictal SPECT, the ictal SPECT was also performed. MR image fusion with ictal/interictal SPECT subtraction images allowed to identify an epileptogenic focus within the residual tissue of the left temporal lobe.
2. In the second patient, after hemispherectomy, the interictal SPECT study showed three areas of perfusion deficit meeting the criteria for TPD – two areas that showed the lowest perfusion similarly (as compared to

referential average CNS perfusion) corresponded to the most probable location of the epileptogenic focus in EEG. The patient was subjected to reoperation (resection of both areas) with good outcome.

Analysis of patients from the MCC group

Using a new evaluation method in 11 patients with multifocal congenital cortical malformations (multiple structural lesions and multiple perfusion deficits in the standard SPD assessment), the location of a probable single lesion with maximum perfusion disturbance was obtained in 8 cases, while in 3 patients two structural CNS lesions with similar decrease in perfusion were identified. In these 3 patients with two lesions, the result of EEG, lateralizing the brain hemisphere or localizing particular lobe responsible for disturbed bioelectrical CNS activity, appeared to be helpful to select a single potential focus.

Analysis of patients from the CE group

In the group of 7 patients with cryptogenic epilepsy, a standard assessment of SPECT showed multiple foci of perfusion deficit (at least 4 lesions). After quantitative analysis of the intensity of perfusion deficits in fused MR and SPECT images in 4 patients, a single focus of maximum intensity was established. In case of two patients, two perfusion deficits of similar intensity were localized in CNS, whereas one patient had three lesions of comparable perfusion deficit. In two cases, the result of EEG appeared to be helpful to establish a single, most probable location of epileptogenic focus. In one case an ictal SPECT was performed and the subtraction of ictal and interictal SPECT images allowed to determine the pathological area.

Out of 20 patients qualified for the assessment after failing to respond to treatment with two antiepileptic drugs, with preliminary diagnosis of refractory epilepsy, 19 patients manifested partial improvement or full response to pharmacological treatment (one patient) due to the modification of therapy or introduction of polytherapy. This resulted in postponing the decision on surgical treatment. One patient with seizures occurring despite previously conducted surgery (Engel class IV) was re-operated considering the location of the epileptogenic focus established by corregistered interictal SPECT and MR images – with good postoperative outcome (Engel class II).

Concentrating on methods of quantitative analysis of activity in regions of interest on interictal SPECT images we tried to elaborate a procedure helpful to localize an epileptogenic focus by:

- assessing areas with perfusion/metabolism deficits defined as a reduction in activity per unit volume of cerebral gray matter below the average activity of tracer accumulation in the central nervous system in interictal SPECT study, with the difference in activity in the corresponding area of the opposite hemisphere of >15%,
- comparing the location of areas with perfusion deficits with the results of EEG and/or with the activity in ictal SPECT study in order to select a single probable epileptogenic focus from several locations in the CNS with decreased perfusion/metabolism in interictal SPECT study.

Table 3. Proposed algorithm of diagnosis in children with epilepsy.

Diagnosed epilepsy (clinically + EEG) (exclusion of idiopathic generalized epilepsy)
↓
MRI diagnostics
↓
Cryptogenic refractory epilepsy or multifocal lesions on MRI
↓
Interictal SPECT + MRI (image fusion) Quantitative evaluation of activity within ROI (TPD)
↓
>1 area of hypoperfusion in interictal SPECT fused with MRI
↓
Verification of epileptogenic focus location in EEG or ictal SPECT

Table 3 presents the suggested diagnostic scheme, basing on our study results in children with refractory epilepsy and normal or unclear MRI.

Discussion

Due to a small number of patients involved in the study (20 patients) and only one case of child referred to surgery treatment with good postoperative outcome, our results are not sufficient to draw clear conclusions regarding appropriate diagnostic procedure in children with refractory epilepsy [12]. In order to obtain as much experience as possible in the area of diagnostics and treatment in children with refractory epilepsy, the authors included patients from two leading centers of pediatric neurology. This, however, did not result in a significant increase in the number of patients in the studied group or the group referred to surgical treatment. Possible explanation includes: more effective pharmacological treatment in this group of patients, as well as the fact that clinicians are very cautious when deciding on surgery treatment. However, it has to be kept in mind that pharmacological therapy resulting in a significant reduction of the number of epileptic seizures equals improvement. Nevertheless, most of the pharmacologically treated patients still remain classified within the group with refractory epilepsy according to ILAE definition. For those patients it is necessary to elaborate algorithms of diagnostic procedure in order to precisely localize an epileptogenic focus and implement surgical treatment with minimal damage to the remaining brain tissue, as an alternative to not fully effective pharmacotherapy.

In the analysis of the time from epilepsy diagnosis to decision on surgical treatment in leading neurological centers, even in adult patients with most common pathology – mesial temporal sclerosis (MTS), requiring only to determine the lateralization, the prevailing period exceeds 20 years [13–16]. Slow but noticeable reduction of this period from an average of 22.6 yrs. in 1996–1999 to 21.1 yrs. in 2004–2008 was observed [17]. In some cases, the decision on surgical treatment is postponed due to pseudo-effectiveness of pharmacotherapy and patient being too quickly classified as efficiently controlled with antiepileptic drugs, or due to inadequate assessment of seizure incidence within the treatment period [18]. In pediatric population, about 36% of epileptic patients develop refractory epilepsy which

is more than in adult patients [19]. It has to be taken into account considering the fact that pseudo-effectiveness of pharmacological treatment within the first months of therapy is equally common as in adult population [20].

CNS pathologies characteristic for pediatric epilepsy, like heterotopia or gray matter dysplasia, require not only evaluating lateralization (as it is in MTS) but also locating the lesion before surgery to avoid damaging hemispherectomy or extensive lobectomy. Determining a precise location and size of epileptogenic focus before resection imposes additional, high requirements on the diagnostic methods in this group of patients: EEG, MRI, SPECT and PET.

The evaluation of risks and potential benefits for the patient before deciding on surgery is crucial. In the previous studies [21,22], a complete cessation of seizures was achieved in approximately 50% of epilepsy patients with annual risk of death as a result of operation of about 1.37%.

The literature concerning the use of SPECT to locate epileptogenic foci is limited and brings divergent opinions regarding the usefulness of functional examination. In 2008, Patil et al. conducted a prospective study to assess the usefulness of MRI, EEG and SPECT in the qualification of 353 children with epilepsy for surgical treatment. The authors found that 78% of children with no morphological changes or with multiple changes on MRI were scheduled for surgery basing on EEG results, whereas SPECT results did not significantly influence the decision in this group of patients [23].

However, a prospective study by Tan et al. from Mayo Clinic, conducted at the same time and assessing the impact of functional imaging on decisions about surgical treatment in patients with cryptogenic epilepsy confirmed the usefulness of SPECT in preoperative localization of lesion in as much as 31% of patients [24].

Previous studies conducted at Mayo Clinic in 2004 by Buchhalter also demonstrated the usefulness of ictal and interictal SPECT registration, as well as fusion of SPECT and morphological MR images in localizing epileptogenic focus in children [25].

Integration and post-processing of SPECT and MR images have evolved over the years due to the rapid technological progress in the methods of computer processing of medical images and significantly increased the potential for functional testing in the neurological diagnostics. Subtraction technique of ictal and interictal SPECT images and fusion of the subtraction results and MRI images is particularly advanced at Mayo Clinic, being the source of the majority of studies assessing the usefulness of this method [26,27].

The development of post-processing methods led to the situation in which the interictal SPECT was questioned by Paesschen in terms of its usefulness in the diagnostics of epilepsy, while the ictal and interictal SPECT subtraction was assessed by the same author as diagnostically useful [28].

In our opinion, the method of interictal SPECT and MR image fusion proposed in the present study is comparable to MR and 18F-FDG PET image fusion successfully used in the identification of epileptogenic foci instead of invasive EEG or intraoperative electrocorticography; area showing hypo-metabolism exceeding the size of the MRI lesion is more likely an epileptogenic focus than other morphological change in the CNS, according to Chandra [29].

In our study, ictal SPECT allowing image subtraction was achieved only in two cases. Caution in referring patients for SPECT during induced seizures was in the majority of cases a result of effectiveness or pseudo-effectiveness of pharmacological treatment and postponing the decision on surgery. However, it remains uncertain whether these patients will or will not require a re-assessment and qualification for the procedure. Hence, this preliminary assessment of interictal SPECT can be a helpful starting point for ictal SPECT evaluation.

On the other hand, it is known that so far there has been no certain diagnostic scheme used in localizing epileptogenic foci – according to Gupta [30], different centers apply completely different sets of diagnostic tests, none of which seems to be superior.

All capabilities of SPECT are still not fully recognized and explored; there is a scarcity of medical centers using integrated imaging in routine diagnostics. There are also no quantitative criteria helping to differentiate between normal and abnormal results. In pediatric patients, another difficulty is the inability to create normative SPECT databases, which are in use for adult patients. The only possibility of semi-quantitative evaluation of SPECT studies in children is to compare the activity in the region to a well-defined area or to the reference value.

The presented work is a preliminary study – the group is heterogeneous and there is no verification of the results, since only one patient in the study group underwent effective surgical treatment basing on data from our assessment.

Conclusions

The authors intend to continue the study of young patients with refractory epilepsy basing on the experience gained during the present research and new possibilities of evaluation of structural and metabolic changes in the CNS:

- 3T MRI scanner with higher spatial resolution will facilitate the identification of discrete structural changes,
- applying the experiences with SPECT imaging of CNS perfusion/metabolism to MRI, with the use of a quantitative evaluation of the first pass of paramagnetic contrast (in T1- and T2-weighted sequences with deconvolution algorithm based on signal intensity with parametric modeling) or non-contrast imaging (ASL, BOLD).

Acknowledgements

Three Institutions participated in diagnostic imaging and image fusion procedures, i.e.: Children's Memorial Health Institute – Magnetic Resonance Laboratory and Department of Nuclear Medicine, Institute of Mother and Child (IMiD) – Magnetic Resonance Laboratory and Specialist Hospital in Międzylesie (MSS) – Department of Nuclear Medicine. Research was based on a project funded

by the Ministry of Science and Higher Education (Research Project KBN: P05E 005 30 "Fusion of MRI and SPECT images as a method for localizing epileptogenic foci in children with refractory epilepsy before surgical treatment").

References:

1. Rosenow F, Luders H: Presurgical evaluation of epilepsy. Brain, 2001; 124: 1683–700
2. Camfield CS, Camfield PR, Gordon K et al: Incidence of epilepsy in childhood and adolescence: a population-based study in Nova Scotia from 1977 to 1985. Epilepsia, 1996; 37(1): 19–23
3. Engel J Jr. Surgery for seizures. N Engl J Med, 1996; 334(10): 647–52
4. Harvey AS, Cross JH, Shinnar S et al: Defining the spectrum of international practice in pediatric epilepsy surgery patients ILAE Pediatric Epilepsy Surgery Survey Taskforce. Epilepsia, 2008; 49(1): 146–55
5. Sarco DP, Burke JF, Madsen JR: Electroencephalography in epilepsy surgery planning.Childs Nerv Syst, 2006; 22(8): 760–65
6. Guerrini R, Sicca F, Parmeggiani L: Epilepsy and malformations of the cerebral cortex. Epileptic Disord, 2003; 5(Suppl.2): S9–26
7. Krausz Y, Cohen D, Konstantini S et al: Brain SPECT imaging in temporal lobe epilepsy. Neuroradiology, 1991; 33: 274–76
8. O'Brien TJ: SPECT: methodology. Adv Neurol, 2000; 83: 11–32
9. Laich E, Kuzniecky R, Mountz J, Liu HG et al: Supplementary sensorimotor area epilepsy: seizure localization, cortical propagation and subcortical activation pathways using ictal SPECT. Brain, 1997; 120: 855–64
10. Zubal IG, Spencer SS, Imam K et al: Differes in images calculated from ictal and interictaltechnetium-99m-HMPAO SPECT scans of epilepsy. J Nucl Med, 1995; 36: 684–89
11. Abdel-Dayem HM, Abu-Judeh H, Kumar M et al: SPECT brain perfusion abnormalities in mild or moderate traumatic brain injury. Clin Nucl Med, 1998;23: 309–17
12. Jurkiewicz E, Bekiesińska-Figatowska M, Miśko J et al: Neurosurgical treatment of drug-resistant epilepsy on the basis of a fusion of MRI and SPECT images – case report. Pol J Radiol, 2010; 75(3): 51–54
13. Spencer SS, Berg AT, Vickrey BG et al: Initial outcomes in the Multicenter Study of Epilepsy Surgery. Multicenter Study of Epilepsy Surgery. Neurology, 2003 23; 61(12): 1680–85
14. Gilliam F, Kuzniecky R, Meador K et al: Patient-oriented outcome assessment after temporal lobectomy for refractory epilepsy. Neurology, 1999; 53(4): 687–94
15. Wiebe S, Matijevic S, Eliasziw M: Clinically important change in quality of life in epilepsy. J Neurol Neurosurg Psychiatry, 2002; 73(2): 116–20
16. Choi H, Carlino R, Heiman G: Evaluation of duration of epilepsy prior to temporal lobe epilepsy surgery during the past two decades. Epilepsy Res, 2009; 86(2–3): 224–27
17. Choi H, Carlino R, Heiman G: Gilliam FG Evaluation of duration of epilepsy prior to temporal lobe epilepsy surgery during the past two decades. Epilepsy Res, 2009; 84: 224–27
18. Choi H, Heiman G, Pandis D et al: Seizure remission and relapse In adults with intractable epilepsy: A cohort study. Epilepsia, 2008; 49: 1440–45
19. Sillanpää M, Jalava M, Kaleva O et al: Long-term prognosis of seizures with onset in childhood. N Engl J Med, 1998; 338(24): 1715–22
20. Berg AT, Levy SR, Testa FM et al: Remission of epilepsy after two drug failures In children: a prospective study. Ann Neurol, 2009; 65: 510–19
21. Salanova V, Markand O, Worth R: Temporal lobe epilepsy surgery: outcome, complications, and late mortality rate in 215 patients. Epilepsia, 2002; 43(2): 170–74
22. Sperling MR, Feldman H, Kinman J et al: O'Connor MJ. Seizure control and mortality in epilepsy. Ann Neurol, 1999; 46(1): 45–50
23. Patil SG, Cross JH, Kling Chong W et al: Is streamlined evaluation of children for epilepsy surgery possible? Epilepsia, 2008; 49(8): 1340–47
24. Tan KM, Britton JW, Buchhalter JR et al: Influence of subtraction ictal SPECT on surgical management in focal epilepsy of indeterminate localization: a prospective study. Epilepsy Res, 2008; 82(2–3): 190–93
25. Buchhalter JR, So EL: Advances in computer-assisted single-photon emission computed tomography (SPECT) for epilepsy surgery in children. Acta Paediatr Suppl, 2004; 93(445): 32–35
26. Brinkmann BH, O'Brien TJ, Mullan BP et al: Subtraction ictal SPECT coregistered to MRI for seizure focus localization in partial epilepsy. Mayo Clin Proc, 2000; 75(6): 615–24
27. O'Brien TJ, So EL, Mullan BP et al: Subtraction ictal SPECT co-registered to MRI improves clinical usefulness of SPECT in localizing the surgical seizure focus. Neurology,1998; 50(2): 445–54
28. Van Paesschen W, Dupont P, Sunaert S et al: The use of SPECT and PET in routine clinical practice in epilepsy. Curr Opin Neurol, 2007; 20(2): 194–202
29. Chandra PS, Salamon N, Huang J et al: FDGPET/MRI coregistration and diffusion-tensor imagingdistinguish epileptogenic tubers and cortex in patients with tuberous sclerosis complex: preliminary report. Epilepsia, 2006; 47: 1543–49
30. Gupta A: Epilepsy surgery recipes galore: in quest for the epileptogenic tuber in tuberous sclerosis complex. Epileptic Dis, 2009; 11(1): 80–81