



Received: 2017.02.28
Accepted: 2017.03.14
Published: 2017.12.15

Authors' Contribution:

- A** Study Design
- B** Data Collection
- C** Statistical Analysis
- D** Data Interpretation
- E** Manuscript Preparation
- F** Literature Search
- G** Funds Collection

Top 50 Highly Cited Articles on Dual Energy Computed Tomography (DECT) in Abdominal Radiology: A Bibliometric Analysis

Bo Gong^{1ABCDEF}, Yuhao Wu^{1DE}, Michael E. O’Keeffe^{1ADE}, Ferco H. Berger^{2ADEE}, Patrick D. McLaughlin^{1AD}, Savvas Nicolaou^{1AD}, Faisal Khosa*^{1ADE}

¹ Department of Emergency and Trauma Radiology, Vancouver General Hospital, Vancouver, BC, Canada

² Department of Medical Imaging, Sunnybrook Health Sciences Centre, University of Toronto, Toronto, ON, Canada

* Dr. Khosa is the recipient of the Canadian Association of Radiologists /Canadian Radiological Foundation Leadership Scholarship (2017)

Author’s address: Faisal Khosa, Department of Emergency and Trauma Radiology, Vancouver General Hospital, 899 12th Avenue West, Vancouver, British Columbia, V5Z 1M9, Canada, e-mail: fkhosa@hotmail.com

Summary

This study aims to identify the 50 most highly cited articles on dual energy computed tomography (DECT) in abdominal radiology.

Thomson Reuters Web of Science All Databases was queried without year or language restriction. Only original research articles with a primary focus on abdominal radiology using DECT were selected. Review articles, meta-analyses, and studies without human subjects were excluded.

Fifty articles with the highest average yearly citation were identified. These articles were published between 2007 and 2017 in 12 journals, with the most in *Radiology* (12 articles). Articles had a median of 7 authors, with all first authors but one primarily affiliated to radiology departments. The United States of America produced the most articles (16), followed by Germany (13 articles), and China (7 articles). Most studies used Dual Source DECT technology (35 articles), followed by Rapid Kilovoltage Switching (14 articles), and Sequential Scanning (1 article). The top three scanned organs were the liver (24%), kidney (16%), and urinary tract (15%). The most commonly studied pathology was urinary calculi (28%), renal lesion/tumor (23%), and hepatic lesion/tumor (20%).

Our study identifies intellectual milestones in the applications of DECT in abdominal radiology. The diversity of the articles reflects on the characteristics and quality of the most influential publications related to DECT.

MeSH Keywords:

Abdomen • Bibliometrics • Tomography Scanners, X-Ray Computed

PDF file:

<http://www.polradiol.com/abstract/index/idArt/904075>

Background

Dual energy computed tomography (DECT, or dual energy CT) is an emerging technology that involves the use of CT data at two different energy levels (e.g. at 80 and 140 kV). The characteristic attenuation patterns of different materials at these different energy levels provide advantages that are not available from traditional single energy CT (SECT), such as obtaining virtual unenhanced images using material subtraction as well as the improved ability to identify

substances composed of various chemical elements [1]. The last decade saw extensive research exploring the diagnostic potential of DECT [2]. It is thus important to examine the existing literature and analyze the trends of this rapidly advancing field.

Bibliometric analysis, a quantitative analysis of research literature, provides an objective method to measure the research output of a research field, researchers, or research articles [3]. Citation analysis, in particular, is widely used

to estimate the impact of research, based on the idea that the more influential research work is, the more likely it is to be cited by fellow researchers [4]. As a result, citation analysis has been used to help benchmark performance of individual researchers and organizations, identify priority areas for providing support, and justify the return on investment in research funding [5,6]. In the clinical application of radiology techniques, bibliometric and citation analysis can reveal the emergence of novel techniques and topics, identify influential researchers and potential collaborators, and suggest future research directions [7–10]. Despite its importance, our literature search did not reveal any bibliometric analysis on the clinical application of DECT.

In this study, we performed a focused bibliometric analysis on the application of DECT in abdominal radiology, which encompasses several organ systems. The purpose was to identify the 50 most highly cited articles and to identify specific features that contribute to highly cited literature in this field.

Material and Methods

Ethical approval was not required for this study because it was a retrospective evaluation of publicly available research literature.

Literature search

To analyze the most highly cited articles on dual energy computed tomography (DECT) in abdominal radiology, a literature search was conducted on March 6th, 2017 using the Thomson Reuters Web of Science All Databases, which includes more than 12,000 academic journals. We searched without year or language restriction using the following search steps:

1. Topic=(("Dual energy" NEAR/1 "computed tomography") OR ("Dual energy" NEAR/1 "CT") OR "DECT" OR "Spectral computed tomography" OR "Spectral CT")

Returned 3,493 articles.

2. Topic=(("Abdomen" OR "Abdominal" OR "Aorta" OR "Spleen" OR "Splenic" OR "Gall bladder" OR "Adrenal" OR "Stomach" OR "Gastric" OR "Gastrointestinal" OR "Intestine\$" OR "Colon" OR "Colorectal" OR "Liver" OR "Hepatic" OR "Portal" OR "Bile" OR "Biliary" OR "Kidney" OR "Renal" OR "Bladder" OR "Urinary" OR "Pancreas" OR "Pancreati*" OR "Inferior vena cava")

Returned 6,425,915 articles.

3. Topic = ("Hemochromatosis" OR "Endovascular NEAR/2 Repair" OR "EVAR" OR "Enterography" OR "Urography" OR "Colonoscopy" OR "Gallstone\$" OR "Hemorrhage" OR "Haemorrhage")

Returned 463,892 articles.

4. "1 AND (2 OR 3)"

Returned 953 articles.

All data fields of the 953 articles returned from the literature search were downloaded from the Web of Science to a local database, including authors, title, journal, volume, issue, beginning and ending pages, publication date and year, abstract, citation count in Web of Science All Databases, etc.

These articles were then ranked by average yearly citation, which was calculated as follows: Total citation count from Web of Science All Databases/Number of years between publication and March 2017, accurate to month (1/12th of a year).

Screening

Our inclusion criteria included original research in the field of DECT in abdominal radiology. Excluded were: 1) systemic reviews, pictorial reviews and meta-analyses; 2) case reports; 3) studies that did not include human subjects, or exclusive phantom studies; 4) articles that studied the DECT technique without a primary focus on abdominal organs/conditions.

Two board certified, fellowship trained staff radiologists examined each article, in the descending order of average yearly citation, against the inclusion and exclusion criteria, until a total of 50 most highly cited articles were identified. Further data were then extracted from these 50 articles for subsequent data analysis, such as number of authors, departmental affiliation and country of the first author, study type (prospective or retrospective), sample size, DECT technology, scanned organ, and the pathology involved. Quantitative variables were summarized by range, mean, and median.

Results

Table 1 lists the 50 most highly cited articles included in the bibliometric analysis, ranked by average yearly citation. The average yearly citation range was from 5.53 to 27.43 times/year, with a mean of 9.11 and a median of 7.93 times/year.

The top 2 highly cited articles are "Dual-energy CT in patients suspected of having renal masses: can virtual nonenhanced images replace true nonenhanced images?" (2009), and "Dual energy CT characterization of urinary calculi: initial in vitro and clinical experience" (2008), published by the same first author.

Year of publication

As shown in Figure 1, these 50 articles were published from 2007 to 2017, with a peak of publication between 2010 and 2013.

Authors

The number of authors for each article ranges from 4 to 13, with a median of 7 authors. The majority of the first authors (49 out of 50) were primarily affiliated with

Table 1. The 50 most highly cited articles on DECT in abdominal radiology, ranked in descending order of average yearly citation.

Rank	Article	Total citation	Average yearly citation
1	Graser A, Johnson TR, Hecht EM, Becker CR, Leidecker C, Staehler M, Stief CG, Hildebrandt H, Godoy MC, Finn ME, Stepansky F, Reiser MF, Macari M. Dual-energy CT in patients suspected of having renal masses: Can virtual nonenhanced images replace true nonenhanced images? <i>Radiology</i> , 2009; 252(2): 433–40. [PubMed ID: 19487466]	208	27.43
2	Graser A, Johnson TR, Bader M, Staehler M, Haseke N, Nikolaou K, Reiser MF, Stief CG, Becker CR. Dual energy CT characterization of urinary calculi: Initial in vitro and clinical experience. <i>Invest Radiol</i> , 2008; 43(2): 112–19. [PubMed ID: 18197063]	211	23.23
3	Lv P, Lin XZ, Li J, Li W, Chen K. Differentiation of small hepatic hemangioma from small hepatocellular carcinoma: Recently introduced spectral CT method. <i>Radiology</i> , 2011; 259(3): 720–29. [PubMed ID: 21357524]	102	17.74
4	Zhao LQ, He W, Li JY, Chen JH, Wang KY, Tan L. Improving image quality in portal venography with spectral CT imaging. <i>Eur J Radiol</i> , 2012; 81(8): 1677–81. [PubMed ID: 21444170]	67	14.62
5	Graser A, Becker CR, Staehler M, Clevert DA, Macari M, Arndt N, Nikolaou K, Sommer W, Stief C, Reiser MF, Johnson TR. Single-phase dual-energy CT allows for characterization of renal masses as benign or malignant. <i>Invest Radiol</i> , 2010; 45(7): 399–405. [PubMed ID: 20498609]	89	13.35
6	Chandarana H, Godoy MC, Vlahos I, Graser A, Babb J, Leidecker C, Macari M. Abdominal aorta: Evaluation with dual-source dual-energy multidetector CT after endovascular repair of aneurysms – initial observations. <i>Radiology</i> , 2008; 249(2): 692–700. [PubMed ID: 18812561]	99	11.88
7	Hidas G, Eliahou R, Duvdevani M, Coulon P, Lemaitre L, Gofrit ON, Pode D, Sosna J. Determination of renal stone composition with dual-energy CT: In vivo analysis and comparison with x-ray diffraction. <i>Radiology</i> , 2010; 257(2): 394–401. [PubMed ID: 20807846]	72	11.37
8	Guimaraes LS, Fletcher JG, Harmsen WS, Yu L, Siddiki H, Melton Z, Huprich JE, Hough D, Hartman R, McCollough CH. Appropriate patient selection at abdominal dual-energy CT using 80 kV: Relationship between patient size, image noise, and image quality. <i>Radiology</i> , 2010; 257(3): 732–42. [PubMed ID: 20959540]	71	11.36
9	Zhang LJ, Peng J, Wu SY, Wang ZJ, Wu XS, Zhou CS, Ji XM, Lu GM. Liver virtual non-enhanced CT with dual-source, dual-energy CT: A preliminary study. <i>Eur Radiol</i> , 2010; 20(9): 2257–64. [PubMed ID: 20393717]	66	10.15
10	Chandarana H, Megibow AJ, Cohen BA, Srinivasan R, Kim D, Leidecker C, Macari M. Iodine quantification with dual-energy CT: Phantom study and preliminary experience with renal masses. <i>Am J Roentgenol</i> , 2011; 196(6): W693–700. [PubMed ID: 21606256]	58	10.09
11	Scheffel H, Stolzmann P, Frauenfelder T, Schertler T, Desbiolles L, Leschka S, Marincek B, Alkadhi H. Dual-energy contrast-enhanced computed tomography for the detection of urinary stone disease. <i>Invest Radiol</i> , 2007; 42(12): 823–29. [PubMed ID: 18007154]	93	10.05
12	Lv P, Lin XZ, Chen K, Gao J. Spectral CT in patients with small HCC: Investigation of image quality and diagnostic accuracy. <i>Eur Radiol</i> , 2012; 22(10): 2117–24. [PubMed ID: 22618521]	43	9.74
13	Pinho DF, Kulkarni NM, Krishnaraj A, Kalva SP, Sahani DV. Initial experience with single-source dual-energy CT abdominal angiography and comparison with single-energy CT angiography: Image quality, enhancement, diagnosis and radiation dose. <i>Eur Radiol</i> , 2013; 23(2): 351–59. [PubMed ID: 22918562]	39	9.55
14	Macari M, Spieler B, Kim D, Graser A, Megibow AJ, Babb J, Chandarana H. Dual-source dual-energy MDCT of pancreatic adenocarcinoma: Initial observations with data generated at 80 kVp and at simulated weighted-average 120 kVp. <i>Am J Roentgenol</i> , 2010; 194(1): W27–32. [PubMed ID: 20028887]	67	9.35
15	Pan Z, Pang L, Ding B, Yan C, Zhang H, Du L, Wang B, Song Q, Chen K, Yan F. Gastric cancer staging with dual energy spectral CT imaging. <i>PLoS One</i> , 2013; 8(2): e53651. [PubMed ID: 23424614]	38	9.31
16	Lin XZ, Wu ZY, Tao R, Guo Y, Li JY, Zhang J, Chen KM. Dual energy spectral CT imaging of insulinoma-Value in preoperative diagnosis compared with conventional multi-detector CT. <i>Eur J Radiol</i> , 2012; 81(10): 2487–94. [PubMed ID: 22153746]	41	9.28
17	Takahashi N, Vrtiska TJ, Kawashima A, Hartman RP, Primak AN, Fletcher JG, McCollough CH. Detectability of urinary stones on virtual nonenhanced images generated at pyelographic-phase dual-energy CT. <i>Radiology</i> , 2010; 256(1): 184–90. [PubMed ID: 20574095]	61	9.15

Table 1 continued. The 50 most highly cited articles on DECT in abdominal radiology, ranked in descending order of average yearly citation.

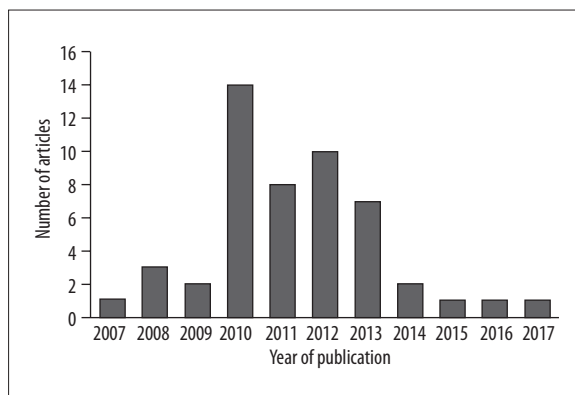
Rank	Article	Total citation	Average yearly citation
18	Brook OR, Gourtsoyianni S, Brook A, Mahadevan A, Wilcox C, Raptopoulos V. Spectral CT with metal artifacts reduction software for improvement of tumor visibility in the vicinity of gold fiducial markers. <i>Radiology</i> , 2012; 263(3): 696–705. [PubMed ID: 22416251]	43	9.05
19	Brook OR, Gourtsoyianni S, Brook A, Siewert B, Kent T, Raptopoulos V. Split-bolus spectral multidetector CT of the pancreas: Assessment of radiation dose and tumor conspicuity. <i>Radiology</i> , 2013; 269(1): 139–48. [PubMed ID: 23674791]	30	8.78
20	Apfaltrer P, Meyer M, Meier C, Henzler T, Barraza JM, Jr., Dinter DJ, Hohenberger P, Schoepf UJ, Schoenberg SO, Fink C. Contrast-enhanced dual-energy CT of gastrointestinal stromal tumors: Is iodine-related attenuation a potential indicator of tumor response? <i>Invest Radiol</i> , 2012; 47(1): 65–70. [PubMed ID: 21934517]	44	8.52
21	Manglaviti G, Tresoldi S, Guerrer CS, Di Leo G, Montanari E, Sardanelli F, Cornalba G. In vivo evaluation of the chemical composition of urinary stones using dual-energy CT. <i>Am J Roentgenol</i> , 2011; 197(1): W76–83. [PubMed ID: 21700999]	48	8.47
22	Kaza RK, Caoili EM, Cohan RH, Platt JF. Distinguishing enhancing from nonenhancing renal lesions with fast kilovoltage-switching dual-energy CT. <i>Am J Roentgenol</i> , 2011; 197(6): 1375–81. [PubMed ID: 22109292]	43	8.19
23	Ascenti G, Siragusa C, Racchiusa S, Ielo I, Privitera G, Midili F, Mazziotti S. Stone-targeted dual-energy CT: A new diagnostic approach to urinary calculosis. <i>Am J Roentgenol</i> , 2010; 195(4): 953–58. [PubMed ID: 20858824]	52	8.10
24	Ascenti G, Mileto A, Krauss B, Gaeta M, Blandino A, Scribano E, Settineri N, Mazziotti S. Distinguishing enhancing from nonenhancing renal masses with dual-source dual-energy CT: Iodine quantification versus standard enhancement measurements. <i>Eur Radiol</i> , 2013; 23(8): 2288–95. [PubMed ID: 23479222]	29	8.09
25	Thomas C, Patschan O, Ketelsen D, Tsiflikas I, Reimann A, Brodoefel H, Buchgeister M, Nagele U, Stenzl A, Claussen C, Kopp A, Heuschmid M, Schlemmer HP. Dual-energy CT for the characterization of urinary calculi: In vitro and in vivo evaluation of a low-dose scanning protocol. <i>Eur Radiol</i> , 2009; 19(6): 1553–59. [PubMed ID: 19205704]	62	8.00
26	Yamada Y, Jinzaki M, Tanami Y, Abe T, Kuribayashi S. Virtual monochromatic spectral imaging for the evaluation of hypovascular hepatic metastases: The optimal monochromatic level with fast kilovoltage switching dual-energy computed tomography. <i>Invest Radiol</i> , 2012; 47(5): 292–98. [PubMed ID: 22472797]	38	7.86
27	Altenbernd J, Heusner TA, Ringelstein A, Ladd SC, Forsting M, Antoch G. Dual-energy-CT of hypervascular liver lesions in patients with HCC: Investigation of image quality and sensitivity. <i>Eur Radiol</i> , 2011; 21(4): 738–43. [PubMed ID: 20936520]	46	7.77
27	Neville AM, Gupta RT, Miller CM, Merkle EM, Paulson EK, Boll DT. Detection of renal lesion enhancement with dual-energy multidetector CT. <i>Radiology</i> , 2011; 259(1): 173–83. [PubMed ID: 21292866]	46	7.77
29	Stolzmann P, Kozomara M, Chuck N, Muntener M, Leschka S, Scheffel H, Alkadhi H. In vivo identification of uric acid stones with dual-energy CT: Diagnostic performance evaluation in patients. <i>Abdom Imaging</i> , 2010; 35(5): 629–35. [PubMed ID: 19727931]	49	7.64
30	Klauss M, Stiller W, Pahn G, Fritz F, Kieser M, Werner J, Kauczor HU, Grenacher L. Dual-energy perfusion-CT of pancreatic adenocarcinoma. <i>Eur J Radiol</i> , 2013; 82(2): 208–14. [PubMed ID: 23062281]	31	7.59
31	De Cecco CN, Buffa V, Fedeli S, Luzietti M, Vallone A, Ruopoli R, Miele V, Rengo M, Paolantonio P, Maurizi Enrici M, Laghi A, David V. Dual energy CT (DECT) of the liver: Conventional versus virtual unenhanced images. <i>Eur Radiol</i> , 2010; 20(12): 2870–75. [PubMed ID: 20623126]	47	7.52
32	Robinson E, Babb J, Chandarana H, Macari M. Dual source dual energy MDCT: Comparison of 80 kVp and weighted average 120 kVp data for conspicuity of hypo-vascular liver metastases. <i>Invest Radiol</i> , 2010; 45(7): 413–18. [PubMed ID: 20458250]	50	7.50
33	Holmes DR, 3rd, Fletcher JG, Apel A, Huprich JE, Siddiki H, Hough DM, Schmidt B, Flohr TG, Robb R, McCollough C, Wittmer M, Eusemann C. Evaluation of non-linear blending in dual-energy computed tomography. <i>Eur J Radiol</i> , 2008; 68(3): 409–13. [PubMed ID: 18990521]	61	7.39

Table 1 continued. The 50 most highly cited articles on DECT in abdominal radiology, ranked in descending order of average yearly citation.

Rank	Article	Total citation	Average yearly citation
34	Gupta RT, Ho LM, Marin D, Boll DT, Barnhart HX, Nelson RC. Dual-energy CT for characterization of adrenal nodules: Initial experience. <i>Am J Roentgenol</i> , 2010; 194(6): 1479–83. [PubMed ID: 20489086]	49	7.26
35	Song KD, Kim CK, Park BK, Kim B. Utility of iodine overlay technique and virtual unenhanced images for the characterization of renal masses by dual-energy CT. <i>Am J Roentgenol</i> , 2011; 197(6): W1076–82. [PubMed ID: 22109322]	38	7.24
36	Sommer WH, Graser A, Becker CR, Clevert DA, Reiser MF, Nikolaou K, Johnson TR. Image quality of virtual noncontrast images derived from dual-energy CT angiography after endovascular aneurysm repair. <i>J Vasc Interv Radiol</i> , 2010; 21(3): 315–21. [PubMed ID: 20097097]	50	7.14
37	Sudarski S, Apfaltrer P, Nance JW, Jr., Schneider D, Meyer M, Schoenberg SO, Fink C, Henzler T. Optimization of keV-settings in abdominal and lower extremity dual-source dual-energy CT angiography determined with virtual monoenergetic imaging. <i>Eur J Radiol</i> , 2013; 82(10): e574–81. [PubMed ID: 23763858]	24	7.02
38	Kulkarni NM, Eisner BH, Pinho DF, Joshi MC, Kambadakone AR, Sahani DV. Determination of renal stone composition in phantom and patients using single-source dual-energy computed tomography. <i>J Comput Assist Tomogr</i> , 2013; 37(1): 37–45. [PubMed ID: 23321831]	29	6.96
39	Toepker M, Moritz T, Krauss B, Weber M, Euller G, Mang T, Wolf F, Herold CJ, Ringl H. Virtual non-contrast in second-generation, dual-energy computed tomography: Reliability of attenuation values. <i>Eur J Radiol</i> , 2012; 81(3): e398–405. [PubMed ID: 22236702]	34	6.80
40	Mileto A, Mazziotti S, Gaeta M, Bottari A, Zimbaro F, Giardina C, Ascenti G. Pancreatic dual-source dual-energy CT: Is it time to discard unenhanced imaging? <i>Clin Radiol</i> , 2012; 67(4): 334–39. [PubMed ID: 22094183]	33	6.71
41	Mileto A, Marin D, Alfaro-Cordoba M, Ramirez-Giraldo JC, Eusemann CD, Scribano E, Blandino A, Mazziotti S, Ascenti G. Iodine quantification to distinguish clear cell from papillary renal cell carcinoma at dual-energy multidetector CT: A multireader diagnostic performance study. <i>Radiology</i> , 2014; 273(3): 813–20. [PubMed ID: 25162309]	15	6.67
42	Kim KS, Lee JM, Kim SH, Kim KW, Kim SJ, Cho SH, Han JK, Choi BI. Image fusion in dual energy computed tomography for detection of hypervascular liver hepatocellular carcinoma: Phantom and preliminary studies. <i>Invest Radiol</i> , 2010; 45(3): 149–57. [PubMed ID: 20142749]	44	6.29
42	McNamara MM, Little MD, Alexander LF, Carroll LV, Beasley TM, Morgan DE. Multireader evaluation of lesion conspicuity in small pancreatic adenocarcinomas: Complimentary value of iodine material density and low keV simulated monoenergetic images using multiphasic rapid kVp-switching dual energy CT. <i>Abdom Imaging</i> , 2015; 40(5): 1230–40. [PubMed ID: 25331567]	11	6.29
44	Mangold S, Thomas C, Fenchel M, Vuust M, Krauss B, Ketelsen D, Tsifikas I, Claussen CD, Heuschmid M. Virtual nonenhanced dual-energy CT urography with tin-filter technology: Determinants of detection of urinary calculi in the renal collecting system. <i>Radiology</i> , 2012; 264(1): 119–25. [PubMed ID: 22570506]	29	6.21
45	Beeres M, Trommer J, Frellesen C, Nour-Eldin NE, Scholtz JE, Herrmann E, Vogl TJ, Wichmann JL. Evaluation of different keV-settings in dual-energy CT angiography of the aorta using advanced image-based virtual monoenergetic imaging. <i>Int J Cardiovasc Imaging</i> , 2016; 32(1): 137–44. [PubMed ID: 26232930]	7	6.00
45	Lv P, Liu J, Chai Y, Yan X, Gao J, Dong J. Automatic spectral imaging protocol selection and iterative reconstruction in abdominal CT with reduced contrast agent dose: Initial experience. <i>Eur Radiol</i> , 2017; 27(1): 374–83. [PubMed ID: 27097790]	1	6.00
47	Schabel C, Bongers M, Sedlmair M, Korn A, Grosse U, Mangold S, Claussen CD, Thomas C. Assessment of the hepatic veins in poor contrast conditions using dual energy CT: Evaluation of a novel monoenergetic extrapolation software algorithm. <i>Rofa</i> , 2014; 186(6): 591–97. [PubMed ID: 24756426]	16	5.82

Table 1 continued. The 50 most highly cited articles on DECT in abdominal radiology, ranked in descending order of average yearly citation.

Rank	Article	Total citation	Average yearly citation
48	Ascenti G, Mazziotti S, Mileto A, Racchiusa S, Donato R, Settineri N, Gaeta M. Dual-source dual-energy CT evaluation of complex cystic renal masses. <i>Am J Roentgenol</i> , 2012; 199(5): 1026–34. [PubMed ID: 23096175]	25	5.77
49	Lee SH, Lee JM, Kim KW, Klotz E, Kim SH, Lee JY, Han JK, Choi BI. Dual-energy computed tomography to assess tumor response to hepatic radiofrequency ablation: Potential diagnostic value of virtual noncontrast images and iodine maps. <i>Invest Radiol</i> , 2011; 46(2): 77–84. [PubMed ID: 20856125]	35	5.75
50	Thomas C, Heuschmid M, Schilling D, Ketelsen D, Tsiflikas I, Stenzl A, Claussen CD, Schlemmer HP. Urinary calculi composed of uric acid, cystine, and mineral salts: Differentiation with dual-energy CT at a radiation dose comparable to that of intravenous pyelography. <i>Radiology</i> , 2010; 257(2): 402–9. [PubMed ID: 20807847]	35	5.53

**Figure 1.** Distribution of the 50 most highly cited articles on DECT in abdominal radiology, by year of publication.

radiology departments, with one first author affiliated with a urology department.

Journals

These 50 articles were published in 12 journals, with 12 articles published in *Radiology*, 8 in *Investigative Radiology*, 8 in *European Radiology*, and 8 in *American Journal of Roentgenology*. Table 2 lists these 12 journals, ranked in descending order of number of articles published.

Country of origin

The country of origin was determined as the country of the primary affiliation of the first author. The 50 articles originated from 9 countries, with the most from the United

Table 2. Journals that published the 50 most highly cited articles on DECT in abdominal radiology, ranked in descending order of number of articles published.

Journal	Article count	Impact Factor (2015)
Radiology	12	6.798
Investigative Radiology	8	4.887
European Radiology	8	3.640
American Journal of Roentgenology	8	2.660
European Journal of Radiology	6	2.593
Abdominal Imaging	2	2.189
PLoS One	1	3.057
Journal of Vascular and Interventional Radiology	1	2.570
Clinical Radiology	1	2.151
International Journal of Cardiovascular Imaging	1	1.880
RöFo – Fortschritte auf dem Gebiet der Röntgenstrahlen und der bildgebenden Verfahren	1	1.672
Journal of Computer Assisted Tomography	1	1.470

Table 3. Countries of origin of the 50 most highly cited articles on DECT in abdominal radiology.

Country	Article count
United States of America	16
Germany	13
China	7
Italy	6
Korea	3
Switzerland	2
Austria	1
Israel	1
Japan	1

States of America (16 articles), Germany (13 articles), China (7 articles), and Italy (6 articles). Table 3 lists these 9 countries with the number of articles from that country.

Study design

Out of the 50 articles, 27 articles (54%) used prospective study design, and 23 articles (46%) used retrospective study design. The sample size ranged from 11 to 202, with a mean of 63.6.

DECT technology

Various technologies have been developed to acquire dual-energy CT images. In these 50 articles, most studies used the Dual Source method (35 articles, 70%), which utilizes two separate X-ray sources placed perpendicularly. Fourteen other studies (28%) used the Rapid Kilovoltage Switching method, with one single X-ray source rapidly switching between two energy levels. One study (2%) used the Sequential Scanning method, where the scans of two energy levels were achieved separately (Table 4).

Table 4. Author departmental affiliation, study design, sample size, and utilized DECT technology of the 50 most highly cited articles on DECT in abdominal radiology.

Descriptor	Type	Count (percentage)
Departmental affiliation n=50	Radiology	49 (98%)
	Other (Urology)	1 (2%)
Study design n=50	Prospective	27 (54%)
	Retrospective	23 (46%)
Sample size n=50	1–50	28 (56%)
	51–100	12 (24%)
	100–200	9 (18%)
	201–400	1 (2%)
	(min=11, max=202, median=47.5, mean=63.6)	
DECT technology n=50	Dual source	35 (70%)
	Rapid kilovoltage switching (Single source)	14 (28%)
	Sequential scanning	1 (2%)

Investigated organ and pathology

Nine articles covered more than one organ, and the most investigated organs were the liver (24%), the kidney (16%), the urinary tract (including the kidney, collecting system, ureter, and bladder, 15%), and the pancreas (12%).

Forty of the 50 articles involved a specific pathology. The most investigated pathology was urinary calculi (28%), followed by renal (23%), hepatic (20%), and pancreatic (15%) lesion/tumor (Table 5).

Discussion

In this study, we revealed interesting trends in the application of DECT in abdominal radiology, by identifying and analyzing the 50 most highly cited articles. These articles were published between 2007 and 2017, consistent with the developmental history of the DECT technology. Even though the concept of DECT in clinical diagnosis was realized in as early as 1970s, it did not gain widespread clinical use until the introduction of dual source CT in 2006 [11]. Most of these articles were published in a window period between 2010 and 2013.

We ranked the articles using average yearly citation, instead of total citation, with the intention to recognize highly cited articles that were published recently, which may not have had sufficient time to accumulate a high total citation count [12]. Our list thus includes many recent articles, including one published in January 2017 that has already been cited. This approach, however, may overlook earlier influential articles producing widely accepted findings that gradually became common knowledge in the field and were thus no longer cited (also called the “obliteration by incorporation” bias [13]). This impact, however, should be quite limited in our study, because almost all DECT articles were published in the past decade. In fact, our analysis shows an overlap of 43 articles (86% consistency) when comparing the top 50 lists ranked either by average yearly citation or by total citation. A complete list of the top 50

Table 5. Organs and pathology investigated in the 50 most highly cited articles on DECT in abdominal radiology.

	Descriptor	Count (percentage)
Organ n=68 <i>Nine articles covered more than one organ/anatomic structure</i>	Liver	16 (24%)
	Kidney	11 (16%)
	Urinary tract (kidney, collecting system, ureter, bladder)	10 (15%)
	Pancreas	8 (12%)
	Vascular system	
	Abdominal aorta	7 (10%)
	Portal vein	3 (4%)
	Iliac arteries	2 (3%)
	Superior mesenteric artery	1 (1%)
	Lymph nodes	2 (3%)
	Muscle	2 (3%)
	Adrenal glands	1 (1%)
	Gallbladder	1 (1%)
	Stomach	1 (1%)
	Spleen	1 (1%)
	Ileum	1 (1%)
Fat	1 (1%)	
Pathology n=40 <i>Ten articles did not involve a specific pathology</i>	Urinary calculi	11 (28%)
	Renal lesion/tumor	9 (23%)
	Hepatic lesion/tumor	8 (20%)
	Pancreatic lesion/tumor	6 (15%)
	Adrenal lesion/tumor	1 (3%)
	Gastric lesion/tumor	1 (3%)
	Hepatic cirrhosis	1 (3%)
	Procedure	
	Endoleak, following endovascular aneurysm repair (EVAR)	2 (5%)
	Metal artifact reduction, following radiation therapy	1 (3%)

most cited articles ranked by total citation is included in Supplementary Table 1.

These most highly cited articles typically have large numbers of authors, which could reflect on the highly collaborative nature of DECT research. Notably, almost all first authors were primarily affiliated with radiology departments, even though the investigated abdominal pathology was related to a number of medical and surgical specialties. This perhaps reflects the infancy of such research, i.e., still being optimized and validated, which speaks to the exciting potential this field can bring into future application in clinical scenarios.

These studies covered a wide range of organs (from the liver, kidney, urinary tract, pancreas, to the abdominal aorta, portal vein, adrenal glands, stomach and spleen, etc.) as well as abdominal pathology, demonstrating the diverse applications of DECT in abdominal radiology. Many of these articles involved the optimization and validation of unique features of DECT, such as the use of virtual unenhanced imaging, virtual monoenergetic imaging, radiation dose reduction, and metal artifact reduction, suggesting the potential widespread application of DECT in future.

Limitations

In this study, we only used one literature source, the Thomson Reuters Web of Science All Databases, because of its large collection and its comprehensive citation tracking. Not combining with searches from other major databases could theoretically limit the comprehensiveness of our search results. This concern was, however, mitigated by the fact that we only focused on the most highly cited articles. From our experience in bibliometric research, almost all highly cited articles were published in an overlapping pool of established journals that were generally indexed by most major literature search engines [7,9,10,14].

Conclusions

In conclusion, we examined the 50 most highly cited articles in the field of DECT in abdominal radiology, and identified important patterns such as investigated organ and pathology, utilized DECT technology, study design, sample size, country of origin, and publishing journal. These results reflect the exciting potential and increasing role of DECT in clinical practice, and may guide the future research in this field.

Conflict of interests

None.

Supplementary Table 1. The 50 most cited articles on DECT in abdominal radiology, ranked in descending order of total citation. Seven articles were ranked lower than 50 by average yearly citation.

Rank by total citation	Rank by yearly citation	Article	Total citation	Average yearly citation
1	2	Graser A, Johnson TR, Bader M, Staehler M, Haseke N, Nikolaou K, Reiser MF, Stief CG, Becker CR. Dual energy CT characterization of urinary calculi: Initial in vitro and clinical experience. <i>Invest Radiol</i> , 2008; 43(2): 112–19. [PubMed ID: 18197063]	211	23.23
2	1	Graser A, Johnson TR, Hecht EM, Becker CR, Leidecker C, Staehler M, Stief CG, Hildebrandt H, Godoy MC, Finn ME, Stepanyk F, Reiser MF, Macari M. Dual-energy CT in patients suspected of having renal masses: can virtual nonenhanced images replace true nonenhanced images? <i>Radiology</i> , 2009; 252(2): 433–40. [PubMed ID: 19487466]	208	27.43
3	3	Lv P, Lin XZ, Li J, Li W, Chen K. Differentiation of small hepatic hemangioma from small hepatocellular carcinoma: Recently introduced spectral CT method. <i>Radiology</i> , 2011; 259(3): 720–39. [PubMed ID: 21357524]	102	17.74
4	6	Chandarana H, Godoy MC, Vlahos I, Graser A, Babb J, Leidecker C, Macari M. Abdominal aorta: evaluation with dual-source dual-energy multidetector CT after endovascular repair of aneurysms – initial observations. <i>Radiology</i> , 2008; 249(2): 692–700. [PubMed ID: 18812561]	99	11.88
5	11	Scheffel H, Stolzmann P, Frauenfelder T, Schertler T, Desbiolles L, Leschka S, Marincek B, Alkadhi H. Dual-energy contrast-enhanced computed tomography for the detection of urinary stone disease. <i>Invest Radiol</i> , 2007; 42(12): 823–29. [PubMed ID: 18007154]	93	10.05
5	60	Chapman RW, Williams G, Bydder G, Dick R, Sherlock S, Kreel L. Computed tomography for determining liver iron content in primary haemochromatosis. <i>Br Med J</i> , 1980; 280(6212): 440–42. [PubMed ID: 7370525]	93	2.50
7	57	Mendler MH, Bouillet P, Le Sidaner A, Lavoine E, Labrousse F, Sautereau D, Pillegard B. Dual-energy CT in the diagnosis and quantification of fatty liver: limited clinical value in comparison to ultrasound scan and single-energy CT, with special reference to iron overload. <i>J Hepatol</i> , 1998; 28(5): 785–94. [PubMed ID: 9625313]	92	4.88
8	5	Graser A, Becker CR, Staehler M, Clevert DA, Macari M, Arndt N, Nikolaou K, Sommer W, Stief C, Reiser MF, Johnson TR. Single-phase dual-energy CT allows for characterization of renal masses as benign or malignant. <i>Invest Radiol</i> , 2010; 45(7): 399–405. [PubMed ID: 20498609]	89	13.35
9	59	Raptopoulos V, Karellas A, Bernstein J, Reale FR, Constantinou C, Zawacki JK. Value of dual-energy CT in differentiating focal fatty infiltration of the liver from low-density masses. <i>Am J Roentgenol</i> , 1991; 157(4): 721–25. [PubMed ID: 1892025]	73	2.87
10	7	Hidas G, Eliahou R, Duvdevani M, Coulon P, Lemaitre L, Gofrit ON, Pode D, Sosna J. Determination of renal stone composition with dual-energy CT: in vivo analysis and comparison with x-ray diffraction. <i>Radiology</i> , 2010; 257(2): 394–401. [PubMed ID: 20807846]	72	11.37
11	8	Guimaraes LS, Fletcher JG, Harmsen WS, Yu L, Siddiki H, Melton Z, Huprich JE, Hough D, Hartman R, McCollough CH. Appropriate patient selection at abdominal dual-energy CT using 80 kV: Relationship between patient size, image noise, and image quality. <i>Radiology</i> , 2010; 257(3): 732–42. [PubMed ID: 20959540]	71	11.36
12	4	Zhao LQ, He W, Li JY, Chen JH, Wang KY, Tan L. Improving image quality in portal venography with spectral CT imaging. <i>Eur J Radiol</i> , 2012; 81(8): 1677–81. [PubMed ID: 21444170]	67	14.62
12	14	Macari M, Spieler B, Kim D, Graser A, Megibow AJ, Babb J, Chandarana H. Dual-source dual-energy MDCT of pancreatic adenocarcinoma: initial observations with data generated at 80 kVp and at simulated weighted-average 120 kVp. <i>Am J Roentgenol</i> , 2010; 194(1): W27–32. [PubMed ID: 20028887]	67	9.35
14	9	Zhang LJ, Peng J, Wu SY, Wang ZJ, Wu XS, Zhou CS, Ji XM, Lu GM. Liver virtual non-enhanced CT with dual-source, dual-energy CT: A preliminary study. <i>Eur Radiol</i> , 2010; 20(9): 2257–64. [PubMed ID: 20393717]	66	10.15
15	25	Thomas C, Patschan O, Ketelsen D, Tsiflikas I, Reimann A, Brodoefel H, Buchgeister M, Nagele U, Stenzl A, Claussen C, Kopp A, Heuschmid M, Schlemmer HP. Dual-energy CT for the characterization of urinary calculi: In vitro and in vivo evaluation of a low-dose scanning protocol. <i>Eur Radiol</i> , 2009; 19(6): 1553–59. [PubMed ID: 19205704]	62	8.00

Rank by total citation	Rank by yearly citation	Article	Total citation	Average yearly citation
16	17	Takahashi N, Vrtiska TJ, Kawashima A, Hartman RP, Primak AN, Fletcher JG, McCollough CH. Detectability of urinary stones on virtual nonenhanced images generated at pyelographic-phase dual-energy CT. <i>Radiology</i> , 2010; 256(1): 184–90. [PubMed ID: 20574095]	61	9.15
16	33	Holmes DR, 3 rd , Fletcher JG, Apel A, Huprich JE, Siddiki H, Hough DM, Schmidt B, Flohr TG, Robb R, McCollough C, Wittmer M, Eusemann C. Evaluation of non-linear blending in dual-energy computed tomography. <i>Eur J Radiol</i> , 2008; 68(3): 409–13. [PubMed ID: 18990521]	61	7.39
18	10	Chandarana H, Megibow AJ, Cohen BA, Srinivasan R, Kim D, Leidecker C, Macari M. Iodine quantification with dual-energy CT: phantom study and preliminary experience with renal masses. <i>Am J Roentgenol</i> , 2011; 196(6): W693–700. [PubMed ID: 21606256]	58	10.09
19	23	Ascenti G, Siragusa C, Racchiusa S, Ielo I, Privitera G, Midili F, Mazziotti S. Stone-targeted dual-energy CT: a new diagnostic approach to urinary calculosis. <i>Am J Roentgenol</i> , 2010; 195(4): 953–58. [PubMed ID: 20858824]	52	8.10
20	32	Robinson E, Babb J, Chandarana H, Macari M. Dual source dual energy MDCT: comparison of 80 kVp and weighted average 120 kVp data for conspicuity of hypo-vascular liver metastases. <i>Invest Radiol</i> , 2010; 45(7): 413–8. [PubMed ID: 20458250]	50	7.50
20	36	Sommer WH, Graser A, Becker CR, Clevert DA, Reiser MF, Nikolaou K, Johnson TR. Image quality of virtual noncontrast images derived from dual-energy CT angiography after endovascular aneurysm repair. <i>J Vasc Interv Radiol</i> , 2010; 21(3): 315–21. [PubMed ID: 20097097]	50	7.14
22	29	Stolzmann P, Kozomara M, Chuck N, Muntener M, Leschka S, Scheffel H, Alkadhi H. In vivo identification of uric acid stones with dual-energy CT: diagnostic performance evaluation in patients. <i>Abdom Imaging</i> , 2010; 35(5): 629–35. [PubMed ID: 19727931]	49	7.64
22	34	Gupta RT, Ho LM, Marin D, Boll DT, Barnhart HX, Nelson RC. Dual-energy CT for characterization of adrenal nodules: Initial experience. <i>Am J Roentgenol</i> , 2010; 194(6): 1479–83. [PubMed ID: 20489086]	49	7.26
24	21	Manglaviti G, Tresoldi S, Guerrer CS, Di Leo G, Montanari E, Sardanelli F, Cornalba G. In vivo evaluation of the chemical composition of urinary stones using dual-energy CT. <i>Am J Roentgenol</i> , 2011; 197(1): W76–83. [PubMed ID: 21700999]	48	8.47
25	31	De Cecco CN, Buffa V, Fedeli S, Luzietti M, Vallone A, Ruopoli R, Miele V, Rengo M, Paolantonio P, Maurizi Enrici M, Laghi A, David V. Dual energy CT (DECT) of the liver: Conventional versus virtual unenhanced images. <i>Eur Radiol</i> , 2010; 20(12): 2870–75. [PubMed ID: 20623126]	47	7.52
26	27	Altenbernd J, Heusner TA, Ringelstein A, Ladd SC, Forsting M, Antoch G. Dual-energy-CT of hypervascular liver lesions in patients with HCC: investigation of image quality and sensitivity. <i>Eur Radiol</i> , 2011; 21(4): 738–43. [PubMed ID: 20936520]	46	7.77
26	27	Neville AM, Gupta RT, Miller CM, Merkle EM, Paulson EK, Boll DT. Detection of renal lesion enhancement with dual-energy multidetector CT. <i>Radiology</i> , 2011; 259(1): 173–83. [PubMed ID: 21292866]	46	7.77
28	20	Apfaltrer P, Meyer M, Meier C, Henzler T, Barraza JM, Jr., Dinter DJ, Hohenberger P, Schoepf UJ, Schoenberg SO, Fink C. Contrast-enhanced dual-energy CT of gastrointestinal stromal tumors: is iodine-related attenuation a potential indicator of tumor response? <i>Invest Radiol</i> , 2012; 47(1): 65–70. [PubMed ID: 21934517]	44	8.52
28	42	Kim KS, Lee JM, Kim SH, Kim KW, Kim SJ, Cho SH, Han JK, Choi BI. Image fusion in dual energy computed tomography for detection of hypervascular liver hepatocellular carcinoma: phantom and preliminary studies. <i>Invest Radiol</i> , 2010; 45(3): 149–57. [PubMed ID: 20142749]	44	6.29
30	12	Lv P, Lin XZ, Chen K, Gao J. Spectral CT in patients with small HCC: investigation of image quality and diagnostic accuracy. <i>Eur Radiol</i> , 2012; 22(10): 2117–24. [PubMed ID: 22618521]	43	9.74
30	18	Brook OR, Gourtsoyianni S, Brook A, Mahadevan A, Wilcox C, Raptopoulos V. Spectral CT with metal artifacts reduction software for improvement of tumor visibility in the vicinity of gold fiducial markers. <i>Radiology</i> , 2012; 263(3): 696–705. [PubMed ID: 22416251]	43	9.05
30	22	Kaza RK, Caoili EM, Cohan RH, Platt JF. Distinguishing enhancing from nonenhancing renal lesions with fast kilovoltage-switching dual-energy CT. <i>Am J Roentgenol</i> , 2011; 197(6): 1375–81. [PubMed ID: 22109292]	43	8.19

Rank by total citation	Rank by yearly citation	Article	Total citation	Average yearly citation
33	16	Lin XZ, Wu ZY, Tao R, Guo Y, Li JY, Zhang J, Chen KM. Dual energy spectral CT imaging of insulinoma-Value in preoperative diagnosis compared with conventional multi-detector CT. <i>Eur J Radiol</i> , 2012; 81(10): 2487–94. [PubMed ID: 22153746]	41	9.28
34	13	Pinho DF, Kulkarni NM, Krishnaraj A, Kalva SP, Sahani DV. Initial experience with single-source dual-energy CT abdominal angiography and comparison with single-energy CT angiography: Image quality, enhancement, diagnosis and radiation dose. <i>Eur Radiol</i> , 2013; 23(2): 351–59. [PubMed ID: 22918562]	39	9.55
35	15	Pan Z, Pang L, Ding B, Yan C, Zhang H, Du L, Wang B, Song Q, Chen K, Yan F. Gastric cancer staging with dual energy spectral CT imaging. <i>PLoS One</i> , 2013; 8(2): e53651. [PubMed ID: 23424614]	38	9.31
35	26	Yamada Y, Jinzaki M, Tanami Y, Abe T, Kuribayashi S. Virtual monochromatic spectral imaging for the evaluation of hypovascular hepatic metastases: the optimal monochromatic level with fast kilovoltage switching dual-energy computed tomography. <i>Invest Radiol</i> , 2012; 47(5): 292–98. [PubMed ID: 22472797]	38	7.86
35	35	Song KD, Kim CK, Park BK, Kim B. Utility of iodine overlay technique and virtual unenhanced images for the characterization of renal masses by dual-energy CT. <i>Am J Roentgenol</i> , 2011; 197(6): W1076–82. [PubMed ID: 22109322]	38	7.24
38	49	Lee SH, Lee JM, Kim KW, Klotz E, Kim SH, Lee JY, Han JK, Choi BI. Dual-energy computed tomography to assess tumor response to hepatic radiofrequency ablation: Potential diagnostic value of virtual noncontrast images and iodine maps. <i>Invest Radiol</i> , 2011; 46(2): 77–84. [PubMed ID: 20856125]	35	5.75
38	50	Thomas C, Heuschmid M, Schilling D, Ketelsen D, Tsiflikas I, Stenzl A, Claussen CD, Schlemmer HP. Urinary calculi composed of uric acid, cystine, and mineral salts: differentiation with dual-energy CT at a radiation dose comparable to that of intravenous pyelography. <i>Radiology</i> , 2010; 257(2): 402–9. [PubMed ID: 20807847]	35	5.53
40	39	Toepker M, Moritz T, Krauss B, Weber M, Euller G, Mang T, Wolf F, Herold CJ, Ringl H. Virtual non-contrast in second-generation, dual-energy computed tomography: Reliability of attenuation values. <i>Eur J Radiol</i> , 2012; 81(3): e398–405. [PubMed ID: 22236702]	34	6.80
41	40	Mileto A, Mazziotti S, Gaeta M, Bottari A, Zimbaro F, Giardina C, Ascenti G. Pancreatic dual-source dual-energy CT: Is it time to discard unenhanced imaging? <i>Clin Radiol</i> , 2012; 67(4): 334–39. [PubMed ID: 22094183]	33	6.71
42	30	Klauss M, Stiller W, Pahn G, Fritz F, Kieser M, Werner J, Kauczor HU, Grenacher L. Dual-energy perfusion-CT of pancreatic adenocarcinoma. <i>Eur J Radiol</i> , 2013; 82(2): 208–14. [PubMed ID: 23062281]	31	7.59
42	58	Numburi UD, Schoenhagen P, Flamm SD, Greenberg RK, Primak AN, Saba OI, Lieber ML, Halliburton SS. Feasibility of dual-energy CT in the arterial phase: Imaging after endovascular aortic repair. <i>Am J Roentgenol</i> , 2010; 195(2): 486–93. [PubMed ID: 20651209]	31	4.71
44	19	Brook OR, Gourtsoyianni S, Brook A, Siewert B, Kent T, Raptopoulos V. Split-bolus spectral multidetector CT of the pancreas: assessment of radiation dose and tumor conspicuity. <i>Radiology</i> , 2013; 269(1): 139–48. [PubMed ID: 23674791]	30	8.78
45	24	Ascenti G, Mileto A, Krauss B, Gaeta M, Blandino A, Scribano E, Settineri N, Mazziotti S. Distinguishing enhancing from nonenhancing renal masses with dual-source dual-energy CT: iodine quantification versus standard enhancement measurements. <i>Eur Radiol</i> , 2013; 23(8): 2288–95. [PubMed ID: 23479222]	29	8.09
45	38	Kulkarni NM, Eisner BH, Pinho DF, Joshi MC, Kambadakone AR, Sahani DV. Determination of renal stone composition in phantom and patients using single-source dual-energy computed tomography. <i>J Comput Assist Tomogr</i> , 2013; 37(1): 37–45. [PubMed ID: 23321831]	29	6.96
45	44	Mangold S, Thomas C, Fenchel M, Vuust M, Krauss B, Ketelsen D, Tsiflikas I, Claussen CD, Heuschmid M. Virtual nonenhanced dual-energy CT urography with tin-filter technology: determinants of detection of urinary calculi in the renal collecting system. <i>Radiology</i> , 2012; 264(1): 119–25. [PubMed ID: 22570506]	29	6.21

Rank by total citation	Rank by yearly citation	Article	Total citation	Average yearly citation
45	55	Ascenti G, Mazziotti S, Lamberto S, Bottari A, Caloggero S, Racchiusa S, Mileto A, Scribano E. Dual-energy CT for detection of endoleaks after endovascular abdominal aneurysm repair: Usefulness of colored iodine overlay. <i>Am J Roentgenol</i> , 2011; 196(6): 1408–14. [PubMed ID: 21606306]	29	5.04
49	52	Gnannt R, Fischer M, Goetti R, Karlo C, Leschka S, Alkadhi H. Dual-energy CT for characterization of the incidental adrenal mass: Preliminary observations. <i>Am J Roentgenol</i> , 2012; 198(1): 138–44. [PubMed ID: 22194489]	28	5.42
50	51	Ho LM, Marin D, Neville AM, Barnhart HX, Gupta RT, Paulson EK, Boll DT. Characterization of adrenal nodules with dual-energy CT: can virtual unenhanced attenuation values replace true unenhanced attenuation values? <i>Am J Roentgenol</i> , U; 198(4): 840–45. [PubMed ID: 22451549]	27	5.49

References:

- Lestra T, Mule S, Millet I et al: Applications of dual energy computed tomography in abdominal imaging. *Diagn Interv Imaging*, 2016; 97(6): 593–603
- Mallinson PI, Coupal TM, McLaughlin PD et al: Dual-Energy CT for the musculoskeletal system. *Radiology*, 2016; 281: 690–707
- Godin B: On the origins of bibliometrics. *Scientometrics*, 2006; 68: 109–33
- Choudhri AF, Siddiqui A, Khan NR, Cohen HL: Understanding bibliometric parameters and analysis. *Radiographics*, 2015; 35: 736–46
- Abramo G, D'Angelo CA: Evaluating research: From informed peer review to bibliometrics. *Scientometrics*, 2011; 87: 499–514
- Goodall A: The place of citations in today's academy. *International Higher Education*, 2015
- Dolan RS, Hanna TN, Warraich GJ et al: The top 100 articles in the radiology of trauma: A bibliometric analysis. *Emerg Radiol*, 2015; 22: 667–75
- O'Keeffe ME, Hanna TN, Holmes D et al: The 100 most-cited original articles in cardiac computed tomography: A bibliometric analysis. *J Cardiovasc Comput Tomogr*, 2016; 10: 414–23
- Khan MS, Ullah W, Riaz IB et al: Top 100 cited articles in cardiovascular magnetic resonance: a bibliometric analysis. *J Cardiovasc Magn Reson*, 2016; 18: 87
- Shahzeb Khan M, Fatima K, Bin Riaz I et al: The 20 most-cited articles in echocardiography literature. *Eur Heart J*, 2017; 38: 74–78
- Schoepf UJ, Colletti PM: New dimensions in imaging: The awakening of dual-energy CT. *Am J Roentgenol*, 2012; 199: S1–2
- Seglen PO: Citation rates and journal impact factors are not suitable for evaluation of research. *Acta Orthop Scand*, 1998; 69: 224–29
- Garfield E, Merton RK: Citation indexing: Its theory and application in science, technology, and humanities: Wiley New York, 1979
- Siddiqi TJ, Usman MS, Khan MS et al: The 100 most influential papers in the field of thrombolytic therapy: A bibliometric analysis. *Am J Cardiovasc Drugs*, 2017 [Epub ahead of print]