

Received: 2012.07.27  
Accepted: 2013.02.20

## Autologous blood-clot embolisation of cavernosal artery pseudoaneurysm causing delayed high-flow priapism

Yakup Yesilkaya<sup>1</sup>, Bora Peynircioglu<sup>1</sup>, Bozkurt Gulek<sup>3</sup>, Melih Topcuoglu<sup>1</sup>, Kubilay İnci<sup>2</sup>

<sup>1</sup> Department of Radiology, Hacettepe Hospital, Ankara, Turkey

<sup>2</sup> Department of Urology, Hacettepe Hospital, Ankara, Turkey

<sup>3</sup> Department of Radiology, Adana Numune Hospital, Adana, Turkey

Author's address: Yakup Yesilkaya, Hacettepe University Department of Radiology, Sıhhiye Ankara 06100, Turkey, e-mail: dryakup23@hotmail.com

### Summary

**Background:**

High-flow priapism is a rare condition characterized by a prolonged and painless erection. Since it may permanently impair erectile function, it must be managed and treated as soon as possible, in order to restore potency. The case we are presenting here was successfully treated by embolizing the penile artery using an autologous clot.

**Case Report:**

A case of delayed painless high-flow priapism that occurred after blunt straddle-type perineal trauma, that was persistent for more than 30 days is being presented. Doppler ultrasonographic examination of the cavernosal artery revealed a 1.5 cm-diameter pseudoaneurysm at the right cavernosal artery, together with a high-velocity shunt between the two cavernous arteries. Extravasation from the proximal sites of both of the cavernous arteries and a right cavernosal artery pseudoaneurysm was detected on angiography. The patient was successfully treated by embolization of the penile artery with an autologous clot in two sessions with a 3-day interval.

**Conclusions:**

This experience along with a survey of the literature made us conclude that embolization of cavernous artery by means of an autologous clot is a very effective procedure and a method of choice for treatment of high-flow priapism and for restoration of penile erectile function. What makes our case even more interesting and important, is the fact that priapism of one month's duration could well be treated by means of this method.

**Key words:**

autologous blood-clot • embolization • delayed high-flow priapism • angiography

**PDF file:**

<http://www.polradiol.com/download/index/idArt/883946>

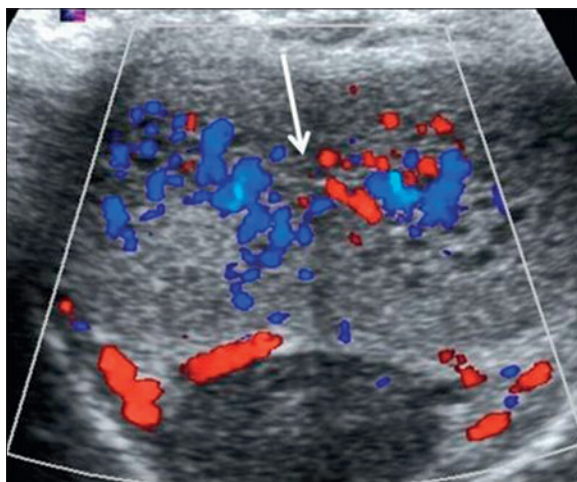
### Background

High-flow priapism is a rare condition, characterized by a prolonged and painless erection [1]. Since it may permanently impair erectile function, it must be managed and treated as soon as possible, in order to restore potency. The diagnosis of high-flow priapism can be made by duplex sonography, angiography or cavernosal blood gas determination. Duplex sonography can show the presence and the location of the fistula, and should be performed first, because it is an efficient and noninvasive method [2]. Angiography with subsequent superselective embolization may be considered as the treatment of choice for high-flow priapism. Arterial embolization may be performed with a number of agents, including microcoils, polyvinyl alcohol, N-butylcyanoacrylate, gel-foam and autologous blood clot.

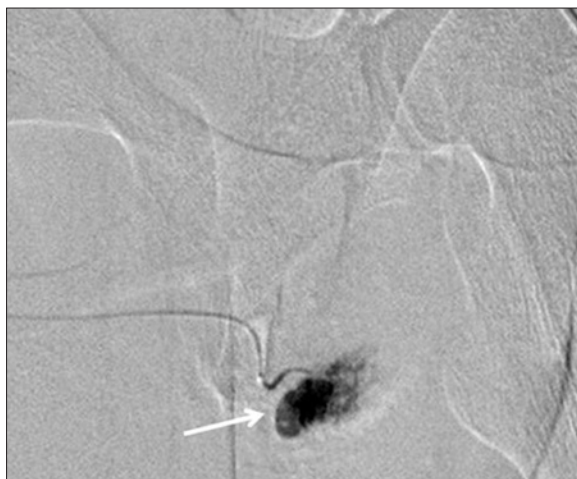
The material of choice for this embolization process is an autologous blood clot, because the spontaneous lysis of the clot allows for self-limited occlusion and restores normal blood flow after a reasonable period of time [3,4]. Herein, we present a unique case of such high-flow priapism treated with 2 sessions of autologous clot embolization.

### Case Report

A 25-year-old man was referred to our hospital with a complaint of a continuous semi-erectile state, following a straddle-type blunt trauma to the perineum one month earlier. On admission to the hospital, he showed normal general physical findings, except for a grade 4 erection at corpora cavernosa. The patient was first examined by doppler sonography, which revealed a high-velocity shunt between



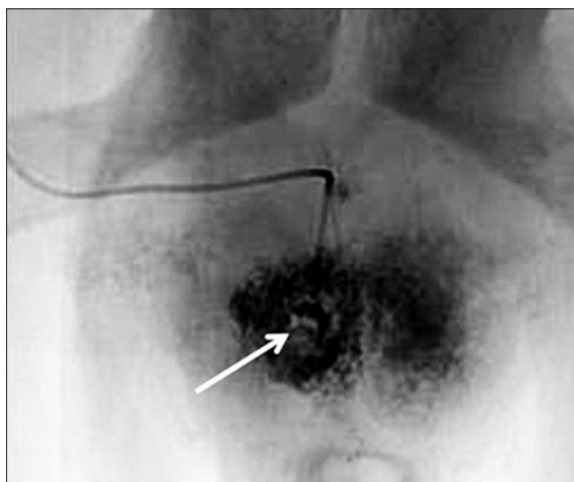
**Figure 1.** Doppler sonography, which disclosed a high-velocity shunt between the two cavernous arteries (white arrow).



**Figure 2.** Selective penile arteriography showed pseudoaneurysm at the right corpus cavernosum (white arrow).

the two cavernous arteries (Figure 1). Next, a diagnostic angiographic study was performed, and a pseudoaneurysm of the proximal right cavernosal artery was detected (Figure 2). An endovascular treatment was planned then. After the right penile artery was catheterized, blood was extracted from the patient and left to clot in the syringe. Later, this autologous clot was used to embolize the right penile artery. A slight aneurysmal filling was observed after the procedure, following forced injection of contrast; but the intervention was aborted after reduction in erection was observed. A second sequence of embolization was planned after the development of semi-erection 48 hours following the procedure. During control angiography performed two days later, a very small aneurysmal filling was detected following forced injection of contrast. At this time, additional autologous clot was administered in order to finally embolize the right penile artery and the radix penis. Post-procedural control injections showed that the right penile artery filling slowed down (Figure 3) and that the priapism diminished.

A follow-up carried out a day later showed that the priapism decreased by fifty percent. That led us to a conclusion



**Figure 3.** Post-procedural control injections showed that the right penile artery filling was very much slowed down (white arrow).

that the priapism was partially due to venous trauma. Also, injections cleared that the venous return, especially on the right side, was late, and that there was drainage by the scrotal veins. As a result, a follow-up one week later was planned to check for the benefits of the embolization procedure and to determine the impact of the trauma. The follow-up one week later showed that the patient was in a very good condition and that his priapism resolved completely. After a period of one month, the patient reported satisfactory tumescence. Two months after the second embolization procedure, the patient was interviewed according to the International Index of Erectile Function (IIEF) and obtained normal erectile functions. The patient reported no erection problems during a one-year follow-up.

## Discussion

The cause of high-flow priapism is usually a traumatic arteriocavernosal fistula which leads to a nonischemic, painless engorgement of the corpora cavernosae [1]. There is usually a lacerated cavernous artery secondary to blunt perineal or penetrating penile trauma, resulting in unregulated, continuous arterial inflow to the lacunar spaces [5]. In high-flow priapism, the fistula bypasses the helicine artery, and the arterial blood flows into the sinusoidal space [1]. Penile erection is caused by an excess of arterial inflow followed by stretching of the corporal sinuses [2]. Thus, cavernous blood in high-flow priapism is consistent with well-oxygenated arterial blood that provides preservation of erectile tissues and erectile potential [6]. This can also explain why our patient preserved his erectile potential, after priapism lasting one month. The aim of therapy in nonischemic high-flow priapism is to close the arterial fistula without jeopardizing erectile function. Treatment options are mechanical (sustained perineal compression), pharmacological (intravenous administration of alpha-adrenergic agonists or methylene blue), surgical (shunt, ligation of the internal pudendal artery), and radiological (selective transcatheter embolization) [3,7]. Although surgery is the traditional treatment method in high-flow priapism, it is more invasive, less efficacious, and associated with higher rates of erectile dysfunction than arterial embolotherapy

[8]. Selective arterial embolization for high-flow priapism, first described by Wear et al. in 1977, is the current therapy of choice for experienced staff. Higher detumescence and lower post-procedure erectile dysfunction rates associated with the procedure have been reported. The procedure may be performed by using various materials, such as autologous blood clot, gel foam, polyvinyl alcohol (PVA), coils and N-butryl cyanide (NBCA) [4,8]. Autologous blood clot is a temporary occlusive agent and permits cicatricial closure of the arterio-cavernosal fistula with subsequent rechanneling of the embolized artery [3,4,8]. Thus, selective arterial embolization of the cavernous artery with an autologous clot is the treatment of choice in high-flow priapism; and it has been reported to be successful in terms of restoring sexual function in as many as 86% of cases in a study performed by Numan et al. [4]. Additionally, Ozturk et al.

reported satisfactory results in their study comprising eight patients and eleven embolizations, nine of which were performed by the administration of autologous clot [8]. Our case involved a 25-year-old man referred to our hospital with the complaint of continuous semi-erectile state, following a saddle-type blunt trauma to the perineum, one month earlier. We treated the patient with the aforementioned embolization technique and managed to restore his potency. This experience and a survey of the literature made us conclude that the embolization of the cavernous artery by means of an autologous clot is a very effective procedure and the method of choice for the treatment of high-flow priapism and the restoration of penile erectile function. What makes our case more interesting and important is the fact that priapism of such long duration (one month) could be well treated by this method.

## References:

1. Mossadaq AR, Sasikumar R, Nazli MZM et al: High-Flow Priapism in a 12-Year-Old Boy: Treatment with Superselective Embolization. *Indian J Urol*, 2009; 25(4): 539-40
2. Spycher MA, Hauri D: The Ultrastructure of the Erectile Tissue in Priapism. *J Urol*, 1986; 135: 42
3. Ji MX, He NS, Wang P et al: Use of Selective Embolization of the Bilateral Cavernous Arteries for Posttraumatic Arterial Priapism. *J Urol*, 1994; 151: 1641
4. Numan F, Cantasdemir M, Ozbayrak M et al: Posttraumatic Nonischemic Priapism Treated with Autologous Blood Clot Embolization. *J Sex Med*, 2008; 5: 173-79
5. Feldstein VA: Posttraumatic High-Flow Priapism Evaluation with Color Doppler Sonography. *J Ultrasound Med*, 1993; 12: 589-93
6. Miller SF, Chait PG, Burrows PE et al: Posttraumatic Arterial Priapism in Children: Management with Embolization. *Radiology*, 1995; 196: 59-62
7. Steers WD, Selby JB Jr: Use of Methylene Blue and Selective Embolization of the Pudendal Artery for High-Flow Priapism Refractory to Medical and Surgical Treatments. *J Urol*, 1991; 146: 1361
8. Ozturk MH, Gumus M, Donmez H et al: Materials in embolotherapy of high-flow priapism: Results and long-term follow-up. *Diagn Interv Radiol*, 2009; 15: 215-20