

Received: 2012.08.06
Accepted: 2012.12.06

Treatment of iatrogenic IVC occlusion with implantation of a stent of a new shape dedicated to aortic aneurysms

Dominik Sieroń^{1,2}, Phillip Wiggermann¹, Daniel Knap³, Ivan Platzek¹,
Wojciech Wawrzynek², Christian Stroszczynski¹

¹ Department of Radiology, University Hospital Carl Gustav Carus, Dresden, Germany

² District Hospital of Orthopedics and Trauma Surgery, Piekary Śląskie, Poland

³ Department of Radiology and Nuclear Medicine, Medical University of Silesia, Katowice, Poland

Author's address: Dominik Sieroń, Department of Radiology, University Hospital Carl Gustav Carus, Dresden, Germany,
e-mail: dominik.sieron@gmail.com

Summary

Background:	Successful treatment of chronic occlusion of inferior vena cava (IVC) and iliocaval confluence with angioplasty and stent implantation is very rare.
Case Report:	We present a case of a 59-year-old patient with iatrogenic occlusion of IVC following L3/L4 discectomy. The wall of the ventral IVC was ruptured during the operation.
Results:	The torn wall was treated by patch angioplasty, resulting in a permanent IVC occlusion, as confirmed by angiography. Iatrogenic permanent occlusion of IVC was successfully treated with recanalization and implantation of a non-covered aortic stent.
Key words:	inferior vena cava • occlusion • stent implantation
PDF file:	http://www.polradiol.com/fulltxt.php?ICID=883772

Background

Iatrogenic occlusion of inferior vena cava (IVC) or iliocaval confluence [1] is very rare [2]. It is associated with persistent lower limb edema, high risk of deep [3] and superficial [4] vein thrombosis (DVT, SVT), as well as increased risk of potentially life-threatening pulmonary embolisms (PE) [5]. Successful recanalisation of an occluded IVC was seldom reported.

Case Report

We present a case of a 59-year-old patient with iatrogenic occlusion of IVC following L3/L4 discectomy. The wall of the ventral IVC was ruptured during the operation. The torn wall was treated by patch angioplasty, resulting in permanent IVC occlusion, as confirmed by angiography. Due to persistent lower limb edema and high risk of embolic events such as PE, DVT or SVT, recanalisation of IVC was necessary. We now report a successful recanalisation performed with a non-covered, "dog bone"-shaped stent dedicated to abdominal aortic aneurysms, and bilateral iliac stents.

Throughout the procedure patient's heart rate, blood pressure and saturation were under constant monitoring.

In the supine position and under local anaesthesia, the right common femoral vein (CFV) was accessed percutaneously and a 7F sheath was introduced. A soft, 0.035-inch wire and vertebral catheter were introduced into the external iliac vein (EIV) and common iliac vein (CIV). The occlusion was located 2 cm distally to the confluence of both CIVs. A 0.035-inch wire was carefully advanced through the occluded vessel using several x-ray projections for guidance. The vertebral catheter was then positioned in the upper IVC, followed by control phlebography, showing a 5-cm-long occlusion of the IVC (Figure 1).

Left CFV was also punctured in order to visualize the left CIV, EIV and the internal iliac vein (IIV). Simultaneous contrast injections into both sheaths were performed for phlebography. Recanalization was carried out using several PTA balloons (4–10 mm). A 7F sheath was subsequently replaced with a 14 F sheath in the right groin. Placement of the newly designed stent (20/200) was performed under fluoroscopic guidance (Figures 2 and 3).

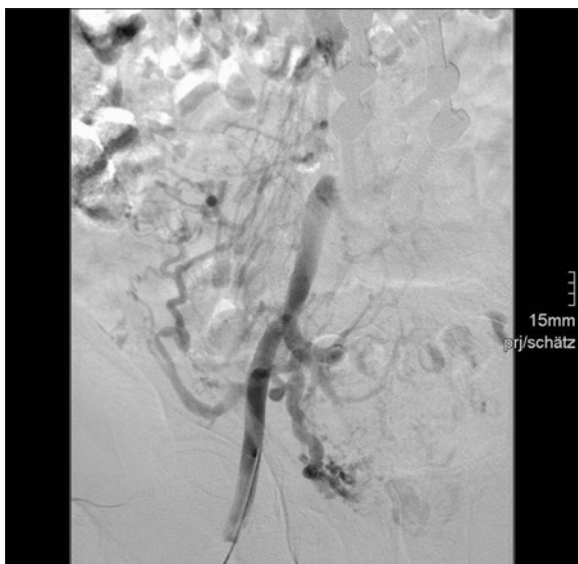

Figure 1. IVC occlusion.

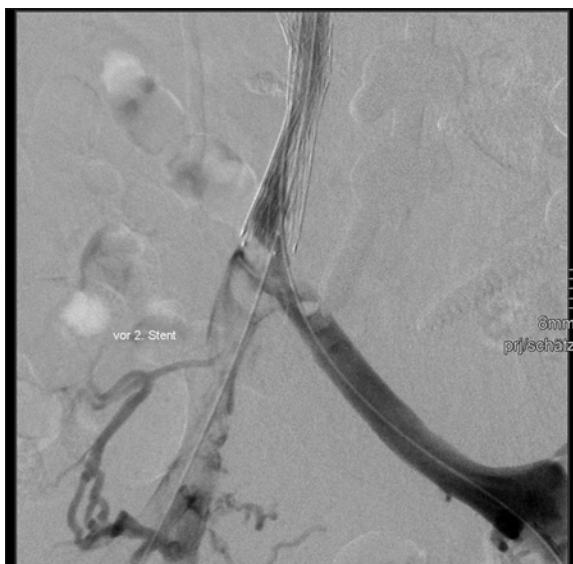

Figure 4. Reduced blood flow in iliac veins.

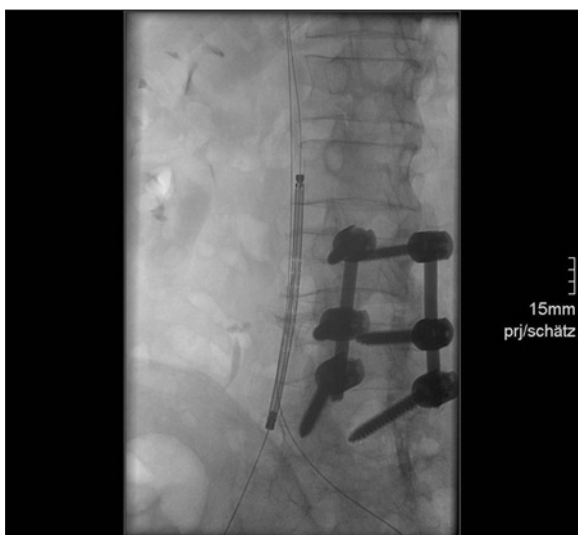

Figure 2. Placement of a stent in IVC.

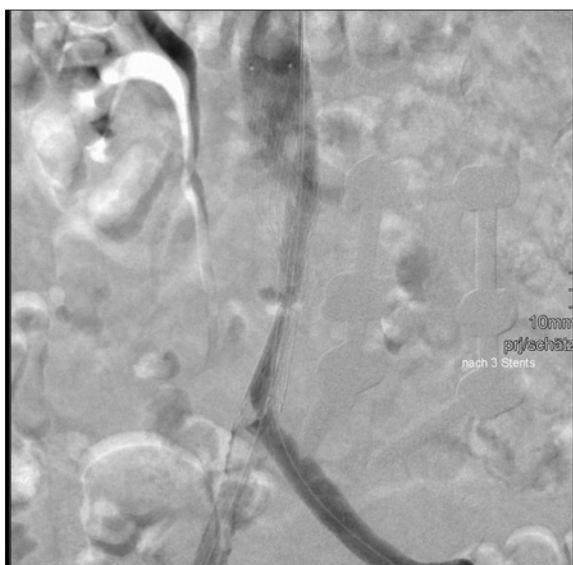


Figure 5. Control venography.

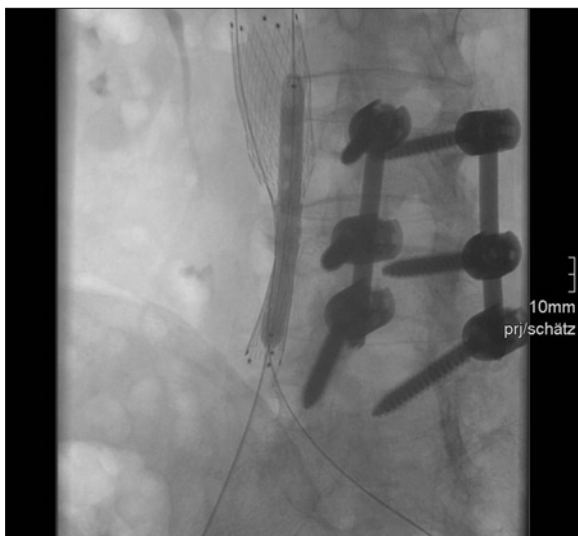

Figure 3. Balloon stent dilatation.

A control phlebography (Figure 4) showed improved perfusion of the IVC, as well as reduced flow in both CIVs. After a crossover implantation [6] of two stents (right 12/42/120, left 14/40/120) into both common iliac veins, no residual stenosis was visible and fast backflow of the contrast medium to the right atrium was demonstrated (Figure 5). Anticoagulation therapy was commenced following the intervention.

A follow-up duplex sonography after one month revealed good blood flow in the IVC and both CIVs.

Discussion

Chronic inferior vena cava occlusion is rare and in most cases related to iatrogenic complications, such as screw fixation or tumour occlusion, e.g. renal cell carcinoma [7,8]. Most iatrogenic orthopaedic complications involve the thoracic aorta, iliac arteries [9] and the IVC. A surgical

intervention in our patient with iatrogenic occlusion of the IVC after iliac screw fixation carried a high risk of complication and morbidity. Accordingly, an endoluminal intervention was chosen as an effective technique associated with lower-risk.

There are no reports on the treatment of chronic IVC occlusion with non-covered stents dedicated to abdominal aortic aneurysms. However, a long-term study by Hartung et al. shows that endovascular angioplasty of obstructions in the IVC and the iliac veins with stent implantation is a safe procedure [10].

The fundamental advantage of using stents dedicated to abdominal aortic aneurysms is their high capacity for radial expansion. Only this type of stent is able to widen a long, chronic IVC occlusion.

Conclusions

Percutaneous angioplasty using stents dedicated to aortic aneurysms is a viable option in the treatment of iatrogenic IVC occlusion. After caval and bilateral iliac-stent implantation control venography showed successful recanalization with restoration of blood flow in the previously occluded IVC and both CIVs [11].

References:

1. Veroux M, Corona D, Giuffrida G et al: A rare cause of ilio caval thrombosis in kidney transplantation. *Transplant Proc*, 2009; 41(4): 1405–6
2. Hwang SS, Park SY: Entrapped inferior vena cava between 2 lumbar vertebrae. *Comput Assist Tomogr*, 2009; 33(5): 811–13
3. Ho WK: Deep vein thrombosis – risks and diagnosis. *Aust Fam Physician*, 2010; 39(7): 468–74
4. Decousus H, Epinat M, Guillot K et al: Superficial vein thrombosis: risk factors, diagnosis, and treatment. *Curr Opin Pulm Med*, 2003; 9(5): 393–97
5. Reißig A, Haase U, Schulze E et al: Diagnosis and therapy of pulmonary embolism prior to death. *Dtsch Med Wochenschr*, 2010; 135(30): 1477–83
6. Neglén P, Darcey R, Olivier J et al: Bilateral stenting at the ilio caval confluence. *J Vasc Surg*, 2010; 51(6): 1457–66
7. Metcalfe C, Chang-Kit L, Dumitru I et al: Antegrade balloon occlusion of inferior vena cava during thrombectomy for renal cell carcinoma. *Can Urol Assoc J*, 2010; 4(4): E105–8
8. Zini L, Haulon S, Leroy X et al: Endoluminal occlusion of the inferior vena cava in renal cell carcinoma with retro- or suprahepatic caval thrombus. *BJU Int*, 2006; 97: 1216–20
9. Lopera JE, Restrepo CS, Gonzales A et al: Aortoiliac vascular injuries after misplacement of fixation screws. *J Trauma*, 2010; 69(4): 870–75
10. Hartung O, Loundou AD, Barthelemy P et al: Endovascular management of chronic disabling ilio-caval obstructive lesions: long-term results. *Eur J Vasc Endovasc Surg*, 2009; 38(1): 118–24
11. Raju S, Neglén P: Percutaneous recanalization of total occlusions of the iliac vein. *J Vasc Surg*, 2009; 50(2): 360–68