Signature: © Pol J Radiol, 2013; 78(1): 72-74
DOI: 10.12659/PJR.883771

Polish Journal of Radiology
www.PolRadiol.com
CASE REPORT

Received: 2012.02.07
Accepted: 2012.12.16

Diagnosis of aortic interruption by CT angiography

Shapour Shirani, Maryam Soleymanzadeh

[1] Department of Radiology, Tehran Heart Center, Tehran University of Medical Sciences, Tehran, Iran
[2] Cardiovascular Surgery Researcher, Department of Research, Tehran Heart Center, Tehran University of Medical Sciences, Tehran, Iran

Author's address: Shapour Shirani, Department of Radiology, Tehran Heart Center, Tehran University of Medical Sciences, North Kargar Street, Tehran Heart Center, Tehran, Iran, e-mail: sh_shirani@yahoo.com

Summary

Background: Interrupted aortic arch (IAA) is a rare congenital malformation of the aortic arch, which might be accompanied with other coexisting cardiovascular anomalies.

Case Report: Many cases with IAA are diagnosed at their neonatal and newborn period but in rare cases the diagnosis is not established until adulthood. The patients may have no clinical symptoms but the signs of heart failure will gradually appear and may cause death.

Results: The development of imaging methods such as computed tomography (CT) and magnetic resonance (MR) imaging has dramatically changed the diagnostics. Here we report a 20-year-old young man with IAA associated with sinus venosus atrial septal defect (SVD) and partial anomalous pulmonary venous connection (PAPVC) referred to our hospital.

Key words: aorta • thoracic • congenital heart disease • CT scanning

PDF file: http://www.polradiol.com/fulltxt.php?ICID=883771

Background

Interrupted aortic arch (IAA) is a congenital malformation of the aortic arch which involves 3 out of one million live births [1]. Most cases with IAA are diagnosed in early childhood or neonatal period and are corrected. However; there will be a few adult cases with undiagnosed or misdiagnosed IAA, a rare entity. The major characteristics of IAA is complete discontinuity of aortic lumen between the ascending and the descending aorta [2]. This defect is accompanied by some other congenital anomalies, such as the lack of aortopulmonary septum, which is often located between the ascending aorta and the pulmonary artery [3]. This congenital anomaly rarely occurs as an isolated lesion and is often associated with other intracardiac malformations, most commonly ventricular septal defect and patent ductus arteriosus (PDA) [4,5]. Although 90% of affected infants die of circulatory failure within the first year of life, sporadic reports have documented survival into adulthood, which is rare but possible [6]. Currently, utilization of accurate imaging systems such as CT angiography has made great progression in diagnostics and treatment of patients with such malformations [7]. Here, we report a 20-year-old male with IAA associated with sinus venosus atrial septal defect (SVD) and partial anomalous pulmonary venous connection (PAPVC).

Case Report

A 20-year-old male was admitted to our hospital with a 6-month history of exertional dyspnea and chest pain. There was not any significant finding at his physical examination except for a grade 3/6 systolic ejection murmur on the left sternal border.His blood pressure was 118/68 mmHg at discharge, and his lower and upper limbs pulses were equal. ECG performed at the time of admission revealed right axis deviation. In transthoracic echocardiography we detected the presence of VSD. Chest radiography also revealed shrinkage of aortic knob and increased diameters of pulmonary vessels. These findings were suggestive of aortic interruption accompanied by a large VSD. We decided to perform cardiac catheterization and CT angiography in order to confirm our diagnosis. CT angiography demonstrated normal aortic root, unremarkable origins of both the coronary arteries. An aortopulmonary window was seen between the ascending aorta and main pulmonary artery (Figures 1 and 2). We also noted that the aorta was interrupted distal to the origin of left subclavian

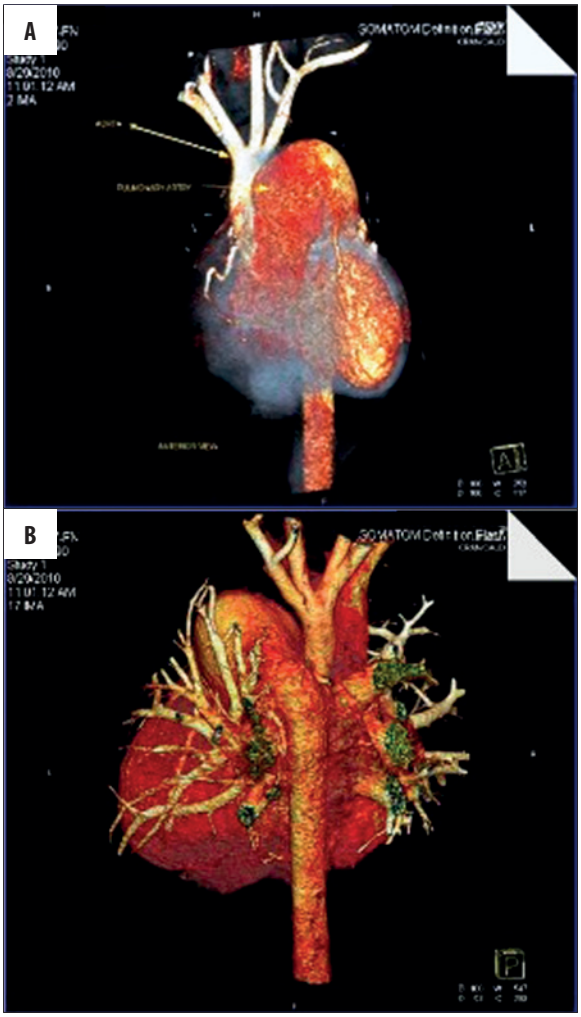

Figure 1. VRT reconstruction image of aorta shows aortic disruption immediately after the origin of left subclavian artery. The descending aorta is continuous with pulmonary artery. (**A**) anterior view, (**B**) posterior view.

artery. Therefore, we confirmed the diagnosis of interrupted aortic arch.

Discussion

The co-existence of interrupted aortic arch and AP window is a really uncommon finding. This congenital anomaly was detected in 1 per 3000 to 1 per 4000 autopsies and accounts for about 5–10% of cases among normal population [8]. It leads to death, cardiac catheterization, or surgery in the first year of life in nearly 1.3% of children with IAA due to its association with frequent cardiovascular malformations such as PDA, ventricular septal defect, atrial septal defect, subaortic stenosis, truncus arteriosus, aortopulmonary window, double outlet right ventricle, and DiGeorge syndrome. Celoria and Patton [9] classified IAA into 3 major types:

Type A: Aortic interruption between the left subclavian artery and the descending aorta.

Type B: Aortic interruption between the left subclavian artery and the left common carotid artery.

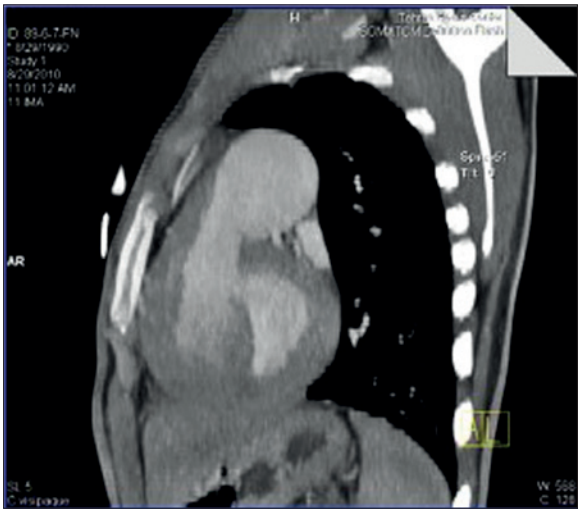

Figure 2. MIP semicoronal, long axis, two-chamber view of the ventricles. There is large, membranous VSD.

Type C: Aortic interruption between the left common carotid artery and the innominate artery.

Clinical findings in neonates born with such defects are unremarkable at first, but after some time the signs of heart failure (tachycardia, tachypnea and growth impairment) begin to appear [10] and finally the patients go through a vicious cycle of decompensated heart failure and death. There is also a significant difference between systolic blood pressures between lower and upper extremities. Presence of aortopulmonary window in such patients is attributed to incomplete cleavage of aortopulmonary septum between pulmonary artery and the aorta and it is estimated that the mentioned defect coexists in one of 10 or 20 cases of IAA. In the past, diagnostic methods were limited to some invasive procedures such as cardiac catheterization, but after introduction of safer and non-invasive methods like echocardiography, diagnosis of IAA became much easier. It is also possible to detect the presence of IAA during pregnancy in the prenatal period if there is a risk factor for congenital heart anomalies in the family or something suspicious is detected during routine prenatal workup [10]. Cardiac catheterization is now used only for determining certain details, ruling out possible differential diagnoses and measuring pulmonary artery pressure and vascular resistance. Computed tomography (CT) and magnetic resonance (MR) imaging play important roles in the evaluation of congenital cardiac malformations. MDCT has advantages over echocardiography and MR imaging in evaluating cardiac pathologies. These advantages include short scanning time, high temporal and spatial resolution, as well as compatibility with ECG gating. MDCT can clearly delineate cardiac chambers and vessels in the mediastinum and chest wall. This technique is particularly useful in young children without a need for deep sedation. Thus, MDCT revolutionized cardiac evaluation. Its role in imaging of coronary arteries and in calcium scoring is well established. It also plays a highly promising role in diagnosing many, if not all, cardiac congenital anomalies. The rarity in our case lies in the co-existence of two rare congenital cardiac anomalies i.e. Type A interrupted aortic arch and aortopulmonary window presenting at an older age.

Conclusions

CT angiography method is a useful imaging modality for morphologic evaluation of aortic interruption. Images from CT angiography can accurately and systematically demonstrate normal and pathologic morphologic features of cardiovascular structures.

References:

1. Canova CR, Carrel T, Dubach P et al: Interrupted aortic arch: fortuitous diagnosis in a 72-year-old female patient with severe aortic insufficiency. Schweiz Med Wochenschr, 1995; 125(1–2): 26–30
2. Siderys H, Graffis R, Halbrook H et al: A technique for management of inaccessible coarctation of the aorta. J Thorac Cardiovasc Surg, 1974; 67: 568–70
3. dr Quek Swee Chye. Associate Professor, Department of Paediatrics, National University of Singapore.Consultant, The Children's Medical Institute, National University Hospital. The Children's Medical Institute. Aortopulmonary window. Updated 28/02/2005
4. Wukasch DC, Cooley DA, Sandiford FM et al: Ascending aorta-abdominal aorta bypass: indications, technique, and report of 12 patients. Ann Thorac Surg, 1977; 23: 442–48
5. Robicsek F, Hess PJ, Vajtai P: Ascending-distal abdominal aorta bypass for treatment of hypoplastic aortic arch and atypical coarctation in the adult. Ann Thorac Surg, 1984; 37: 261–63
6. Steidele RJ: Samml Chir U Med Beob (Vienna) 1778; 2: 114
7. Goo HW, Park IS, Ko JK et al: CT of Congenital Heart Disease: Normal Anatomy and Typical Pathologic Conditions. Radiographics, 2003; 23 Spec No: S147–65
8. Grech V: Diagnostic and surgical trends, and epidemiology of coarctation of the aorta in a population-based study. Int J Cardiol, 1999; 68(2): 197–202
9. Celoria GC, Patton RB: Congenital absence of the aortic arch. Am Heart J, 1959; 58: 407–13
10. Carvalho JS, Moscoso G, Tekay A et al: Clinical impact of first and early second trimester fetal echocardiography on high risk pregnancies. Heart, 2004; 90: 921–26