Signature: © Pol J Radiol, 2014; 79: 305-310
DOI: 10.12659/PJR.890521

Polish Journal of Radiology
www.PolRadiol.com
ORIGINAL ARTICLE

Received: 2014.02.12
Accepted: 2014.02.24
Published: 2014.09.10

Authors' Contribution:
A Study Design
B Data Collection
C Statistical Analysis
D Data Interpretation
E Manuscript Preparation
F Literature Search
G Funds Collection

Rare Infraglottic Lesions in Magnetic Resonance Imaging

Nina Błasiak-Kołacińska[1 AE], Wioletta Pietruszewska[2 DE], Piotr Grzelak[1 D], Marek Raźniewski[1 BF], Ludomir Stefańczyk[1 D], Agata Majos[1 AC]

[1] Department of Radiology – Diagnostic Imaging, Medical University of Łódź, N. Barlicki University Hospital No. 1, Łódź, Poland
[2] Department of Otolaryngology and Oncological Laryngology, Medical University of Łódź, N. Barlicki University Hospital No. 1, Łódź, Poland

Author's address: Nina Błasiak-Kołacińska, Department of Radiology – Diagnostic Imaging, Medical University of Łódź, N. Barlicki University Hospital No. 1, Kopcińskiego 22 Str., 90-153 Łódź, Poland, e-mail: ninanb@wp.pl

Summary

Background: Primary pathological laryngeal lesions occur rarely in infraglottic space. Modern possibilities of diagnostic imaging of infraglottic space include computed tomography (CT) and magnetic resonance (MR). Diagnostic imaging was performed in potential lesions in this area: inflammatory process – cicatrical pemphigoid, benign neoplastic process – chondroma, malignant neoplastic – squamous cell carcinoma.

The aim of the paper is to present clinical and radiographical characteristics of selected lesions located in infraglottic space in MRI examination.

Material/Methods: Three patients examined at the Department of Radiology and Diagnostic Imaging of University Hospital No. 1 in Lodz (SPZOZ USK nr 1) from 2010–2011 with a pathological mass in infraglottic space. Standard imaging protocol for MRI of the neck was used in all patients: field of 1.5 T, slice thickness 3 mm, the distance between the scans 10–20%, FOV – 3 mm, sequences: T1 (TR/TE 455/9, 7 ms, T2 (TR/TE 5300/67 ms), T1 + Gd-DTPA (contrast agent Gd-DTPA at 0.2 mmol/kg).

Conclusions: 1. It is possible to determine characteristic signal pattern for rare lesions of the infraglottic space in MRI. 2. MRI is a valuable complementary modality for the diagnostics and differentiation of lesions in infraglottic space, the evaluation of their advancement and treatment planning.

MeSH Keywords: **Carcinoma, Squamous Cell • Chondroma • Magnetic Resonance Imaging • Pemphigoid, Benign Mucous Membrane**

PDF file: http://www.polradiol.com/abstract/index/idArt/890521

Background

Infraglottic space, also known as infraglottic cavity, comprises the space of approximately 1 cm from the lower surface of vocal folds to the lower edge of the cricoid cartilage. Most pathological lesions, especially laryngeal tumours, originate in the area of glottis. Tumours whose origin is primarily infraglottic occur very rarely and comprise about 1–2% of all laryngeal neoplastic lesions [1]. Benign lesions that can be found in this region include intralaryngeal cysts, papillomae and polyps which usually originate from the epithelium of the anterior part of the vestibule or vocal folds. Benign neoplastic tumours include chondroma, whereas malignant tumours include squamous cell carcinoma (SCC) and chondrosarcoma [2,3]. Other pathological lesions in this area which are not of congenital, inflammatory or traumatic origin, include Kaposi's sarcoma, angioma, Wegner's granuloma, as well as lesions associated with amyloidosis, sarcoidosis, or metastases [2,4].

Clinical evaluation of pathological processes in the infraglottic space is difficult due to bad accessibility. That is why video fiberoscopic examination is usually supplemented by diagnostic imaging with the use of such modalities as multi-slice computed tomography (CT) or magnetic resonance (MR) [4–6].

Computed tomography (CT) is the examination of choice that is performed for the evaluation of pathological laryngeal lesions. It is widely accessible, takes short time thanks

Table 1. Signal pattern MRI for subglottic leasion.

Type of change		Type MRI sequence			
		T1	T2	IN strengthening post cm	PD
Mild	Cyst	↓	↑↑↑	Lack	–
	Chondrosarcoma	→ or ↓	↑↑↑	↑↑↑ Heterogeneously	Infiltration of cartilage
	Pemfigiod stenosing laryngeal	→	→	Heterogeneously	–
Malignant	Squamous cell carcinoma	↓	↑↑	↑↑ Usually homogeneous	Infiltration of cartilage

The legend: „–" not applicable; „↓" low signal; „→" middle signal; „↑↑" increased signal; „↑↑↑" high signal.

to which it is nearly free of movement artefacts, aimed especially for patients who require immediate diagnosis (laryngeal trauma) or for uncooperative patients. Current image processing techniques of data acquired in CT enable a three-dimensional diagnostics and „virtual endoscopy" to be performed, which is highly useful in the diagnostics of the lower part of the larynx [1]. Computed tomography is also a good tool for the evaluation of the cartilaginous skeleton of the larynx, and it has higher specificity, but at the same time, lower sensitivity than MR, which is important for surgery planning and for the assessment of the prognosis of radiotherapy [7,8]. Precise differentiation of soft tissues, especially in the area of pharynx and larynx, is limited although there is a possibility for a wide adjustment of the parameters of the window in which the scan is evaluated, and the characteristics of a given structure according to the value of radiation attenuation according to the Hounsfield Scale. Diagnostic value of CT of the head and neck is also lower because of artefacts that are associated with dental restorations [5,9]

Magnetic resonance imaging (MRI) is characterised by significantly higher tissue resolution in comparison to CT, which enables faster assessment of the range of pathological lesions, and the evaluation of submucosal spread of pathological processes [1,3]. In MRI the patient is not exposed to ionising radiation, and therefore, can be used for monitoring disease development and treatment efficacy [1–3].

Diagnostic value of MRI is determined by the choice of correct sequences, imaging planes, and signal-to-noise ratio (SNR). Optimum SNR in the infraglottic space can be acquired through the use of modern cylindrical coils whose size can be individually adapted, which shortens scanning time and enhances the quality of the scans [1,4,5].

MRI scans of the head and neck are almost always acquired using spin echo and fast spin echo sequences, T1- and T2-weighted sequences, T1-weighted sequences after administrating contrast agent – gadolinium, in sagittal, coronal and axial planes. These sequences complement each other. T1-weighted images provide basic spatial information concerning the scanned area, i.e. its location and dimension, the presence of: adipose tissue infiltration, vessels, lymphadenopathy and mutual topographic relations. T1-weighted sequences are less prone to distortion resulting from movement artefacts, and exhibit better SNR [1,5].

T2-weighted images are better at visualising the contrast between pathological and normal tissues. They are also useful for evaluating the infiltration of cartilaginous skeleton, similarly to PD-weighted images. Fat-saturated T2-weighted images additionally enhance the signal of pathological tissues. However, their spatial resolution is lower in comparison to T1-weighted images. The differentiation of some lesions, such as simple cysts, is possible with the use of T2-weighted sequences, without the need for the second phase of the scan which requires the administration of contrast agent [2]. MRI signal pattern of most pathological lesions in the head and neck is highly specific for cystic and adipose lesions [5] (Table 1).

Contrast-enhanced T1-weighted scans are used for differential diagnostics of inflammatory and neoplastic lesions, especially in cases of their relapse. They provide vital information concerning the spread of the process, the infiltration of the anterior commissure, and, in particular, the conus elasticus, i.e. the border zone between squamous and columnar epithelium, which plays an important role in limiting the spread of neoplastic tumours. It is of crucial value before the decision on surgical procedure or radiotherapy is made [10].

The limitations of MRI in the diagnostics of lesions in the larynx are: relatively long scanning time, which increases the possibility of the occurrence of movement artefacts, especially in patients with advanced lesions or obstruction of the airways. Others include artefacts associated with pulsatile movements of vessels, swallowing, and, above all, patient's breathing during scanning [2,3,7,11]. The acquisition of MR scan which takes approximately 30 min. requires the cooperation and education of the patient – shallow breathing during scanning, as well as withholding cough and swallowing - in spite of the use of high magnetic field (from 1.5 to 3T), fast sequences and volume coils [1]. A huge advantage of MRI is a free choice of planes in inaccurate patient positioning, and the possibility of multiplanar imaging [1,2].

It should be underlined that computed tomography (CT) is the first step in the diagnostic algorithm in the diagnostics

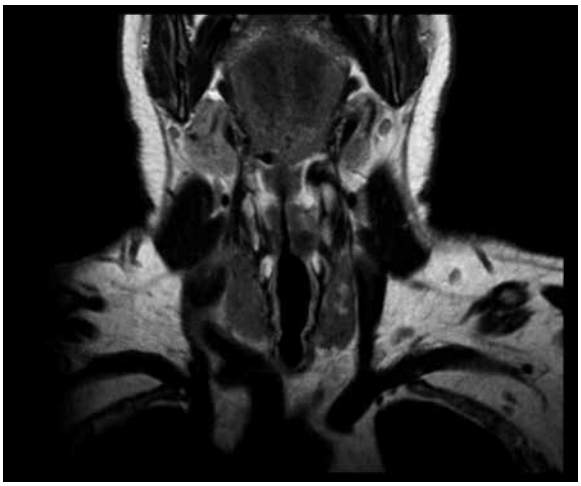

Figure 1. MR T2-weighted image in coronal plane, squamosus cell carcinoma. Infiltration of the left vocal cord and subglottis area.

of laryngeal diseases. However, in some cases, MRI should be preferred.

Positron emission tomography with the use of 2-(18-F)-fluoro 2-deoxy-D-glucose (FDG-PET) is another imaging modality used in cases of pathology in the head and neck. This modality utilises high metabolic activity of neoplastic cells. The disadvantage of this modality is its low spatial resolution. The fusion of FDG-PET with CT or MRI facilitates the localization of the searched neoplastic focal points [1,7]. FDG-PET was applied particularly in the diagnostics of metastases to lymph nodes and the relapse of the neoplastic process after radiotherapy [7].

Cases of: chondroma, squamous cell carcinoma (SCC) and cicatrical pemphigoid were observed in the analysed material, i.e. in the group of patients who were diagnosed with a pathological mass in the infraglottic space and underwent examination at the Department of Radiology and Diagnostic Imaging at the University Hospital No. 1 in Lodz from 2010 to 2011. All patients underwent MRI examinations.

Case 1. Laryngeal Squamous Cell Carcinoma in the Infraglottic Space

Case report 1

SCC of the infraglottic space was diagnosed in a 62-year-old male patient – Z. J. – with a history of smoking for 20 years who attended the Dept. of Otolaryngology in Lodz with recurring dyspnoea since a few months and hoarseness since 1.5 weeks. Acute laryngeal dyspnoea at admittance required that the patient undergo an immediate tracheostomy.

Oedema and thickening of the left vocal fold was detected during indirect laryngoscopy, together with an ulcerated defect. The infiltration of the middle part of the larynx originated in the infraglottic space (Figure 1).

The MR scan showed thickening, as well as a decrease in signal intensity of the mucous membrane in the infraglottic space and the upper part of the trachea in

Figure 2. (**A**) MR, squamosus cell carcinoma laryngis, T-1 image pre contrast Gd-DTPA admission. Infiltration of left vocal cord, plica aryepigllotica and the posterior commisure. (**B**) MR, squamosus cell carcinoma laryngis, T-1 image aftrer contrast Gd-DTPA admission. Infiltration of left vocal cord, plica aryepigllotica and the posterior commisure.

Figure 3. Patient's larynx removed.The picture shown dissected larynx cancer removed including subglottic reagion, especially in the anterior commissure.

T1-weighted images, asymmetry and stricture – of up to a maximum width of 5 mm – of rima glottidis, because of a 34×32×24mm tumour, and inhomogeneous enhancement after the administration of contrast agent (Figure 2). Lymph nodes along the jugular vessels and in the area of the angle of mandible were considerably enlarged, which was best visualised in T2-weighted images in the coronal plane. Destruction of the cricoid cartilage was not detected in the scans. In the left thyroid cartilage, in the middle part, signal hypointensity in T1- and T2-weighted images was visible in 7–8 mm, and minor thinning of the cartilage was visible without evident traits of its destruction.

On the basis of histopathological examination of the specimens (No. 11228), the diagnosis of squamous cell carcinoma, histologic grade G2 with partial keratosis, was made. The

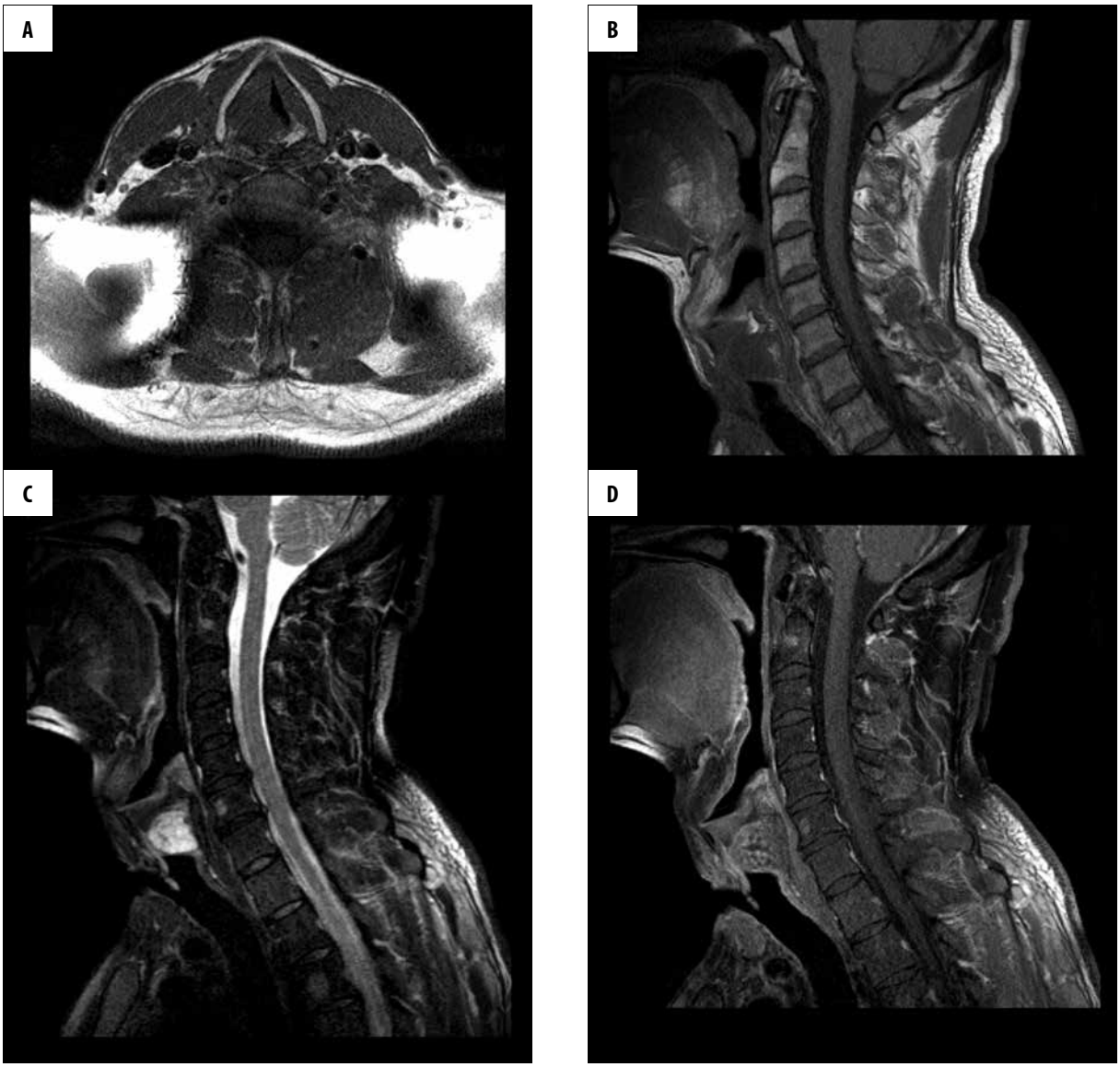

Figure 4. (**A**) Low signal of chondroma laryngis in MR, cross-seccional image, T1W MR. (**B**) MR chondroma larygnis, low signal of subglottic tumor, T1- seqence in sagittal plane. (**C**) MR chondroma laryngis,high signal of subglottic tumor,T-2 sequence in sagittal plane. High signal of subglottic tumor. (**D**) Hetreogenous enhancement of sublottic tumor, T-1 +Gd-DTPA.

patient was scheduled for a total laryngectomy and radical bilateral lymphadenectomy type III. Intraoperative examination confirmed the diagnosis of laryngeal cancer originating from infraglottic space infiltrating anterior commissure and the base of the epiglottis, ventricle of the larynx, and the left vocal fold. Extralaryngeal spread of the pathological mass was detected in the left thyroid cartilage at the level of the vocal fold and transglottic space (Figure 3). The patient was included in the cT4N0Mx group and referred for further treatment at the oncological centre.

Discussion

The described case of a laryngeal squamous cell carcinoma originating from infraglottic area in Z.J. confirms the characteristic, asymptomatic growth of this group of tumours in their early stages [10]. Data obtained from history-taking indicated that aetiology in most cases of laryngeal cancers is associated with smoking, as in the reported case, or alcohol abuse [1]. The tumour originated primarily in the infraglottic space. Infiltration of the trachea was observed but without infiltration of the cervical part of the oesophagus, which is common in this group. A long history of symptoms including recurrent dyspnoea and the following hoarseness is characteristic for the primary location of the cancer in infraglottic space. As the tumour grows concentrically in the circumferentially „closed" cricoid cartilage, it limits the flow of air through this area. Clinical data and high advancement indicate that cancers in this area develop in a mildly symptomatic manner, with symptoms occurring at the obturation of the infraglottic space and the infiltration of vocal folds, which may make it difficult to determine the primary location of the neoplasm. The MRI scan confirmed the typical morphology and signal pattern for squamous cell carcinoma: low signal intensity in T1-weighted images, high in T2-weighted images, and moderate to high, usually

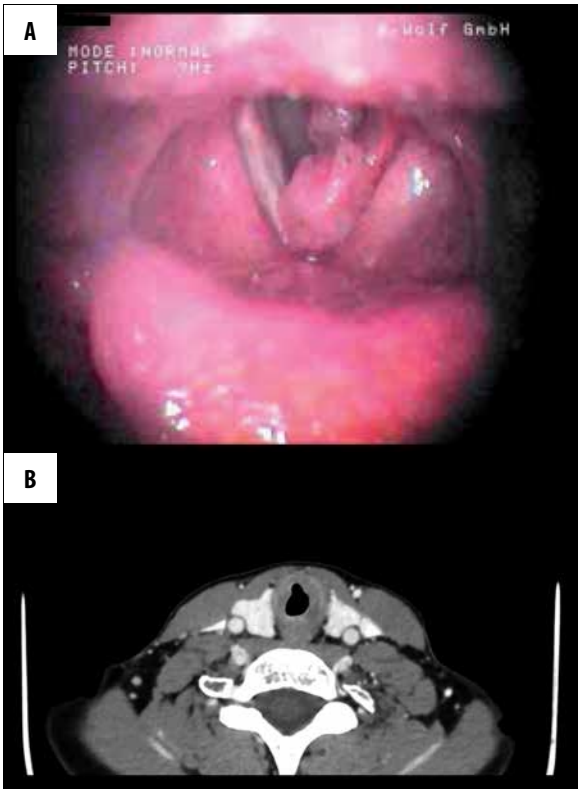

Figure 5. (**A**) Videostroboscopy research.The image of inferior of the larynx in the course of CP, cicatrcal stenosis. (**B**) CT. Thickening of the mucosa in the anterior and posterior commissures, post contrast adminission.

rather homogenous contrast enhancement. However, it turned out to be insufficient for an unambiguous assessment of the infiltration of the thyroid cartilage [8].

Case 2. Laryngeal Chondroma as an Example of a Rare Locally Malignant Lesion

Case report 2

Laryngeal chondroma was diagnosed in a 43-year-old male K. K., who had been suffering from hoarseness for 4–5 years. He was admitted to the Dept. of Laryngology with dyspnoea, because of which tracheostomy was performed and specimens for histopathological examination were collected.

A well-circumscribed mass with rather smooth, regular external shape, with diameters of 23×21×23 mm, which infiltrated the right vocal fold and shifted the vestibular fold upwards, was detected in two-phase contrast-enhanced MRI examination. The described lesion obturated infraglottic space almost entirely, leaving a thin passage of up to 4 mm in width, and narrowed rima glottidis in its posterior part (Figure 4). Moreover, the penetration of the tumour in the inferior direction, i.e. to the superior part of the trachea, was visible in the scans. The fusion of the cricoid cartilage with the tumour mass made it impossible to exclude its infiltration.

Ossifying cartilaginous tissue and hyaline connective tissue without atypical hyperplasia was visible in microscopic images of biopsy material, which enabled to diagnose the lesion as laryngeal chondroma. The patient was scheduled for surgical removal of the tumour, and following closure of tracheostomy after successful surgery. Post-operative histopathological examination of the specimens was consistent with the previous diagnosis (Examination no. 1672).

Discussion

The analysed case of the patient K. K. confirmed all clinical and radiographical features that characterise laryngeal chondroma, i.e. slow, expansive growth without the infiltration in the infraglottic space, local malignancy. In MRI, chondroma reflects typical morphology that is consistent with stroboscopic examination.

Signal pattern in MRI: hypointensive or moderate in T1-weighted sequence, hyperintensive in T2-sequence, and inhomogeneous enhancement after the administration of contrast agent, resembling the „salt and pepper" image according to the subjective view of the physician, reflected well the magnetic features of the cartilaginous matrix of the tumour, such as high water content, high protein content, presence of irregular calcification. CT may be a complementary examination in diagnostics. It often reveals the presence of irregular, amorphic calcification in the tumour that is invisible in MRI. Those features, together with smooth outline and the lack of infiltration of surrounding tissues, providde basis for differentiation with other lesions, especially SCC (Table 1) (Figure 5). However, neither of examinations enables an exact differentiation between chondroma and chondrosarcoma, and between chondroma and SCC [12,13].

Case 3: Cicatrical Pemphigoid of the Larynx

Case report 3

Cicatrical pemphigoid of the larynx was observed in a 44-year-old female patient Z B., who attended the Dept. of Laryngology because of dyspnoea that had been progressing for 3 months. A lesion constricting the infraglottic space to approximately 2 mm was detected In video fibrescopic examination.

Additionally, scabbing of the mucous membrane of the nose and data from the interview suggested a suspicion of autoimmune aetiology. Deposits of IgG, IgA and complement component C3 along the basement membrane were detected in direct immunofluorescence of the specimen collected from the normal mucosa of the nose.

Contrast-enhanced CT of the neck was performed as the first-line examination in the patient. The scans revealed thickening of laryngeal mucous membrane in the area of anterior and posterior commissure, features of infraglottic obstruction of the larynx on a distance of 35 mm, as in the video fibrescopic examination, fissured air canals in the area of anterior commissure resulting from the forming scarring, and traits of adenopathy (Figure 6).

Examination results indicated cicatrical pemphigoid as the cause of laryngeal obstruction. Treatment combining corticosteroids and cytostatics provided rapid local improvement. The patient is monitored and attends follow-up appointments

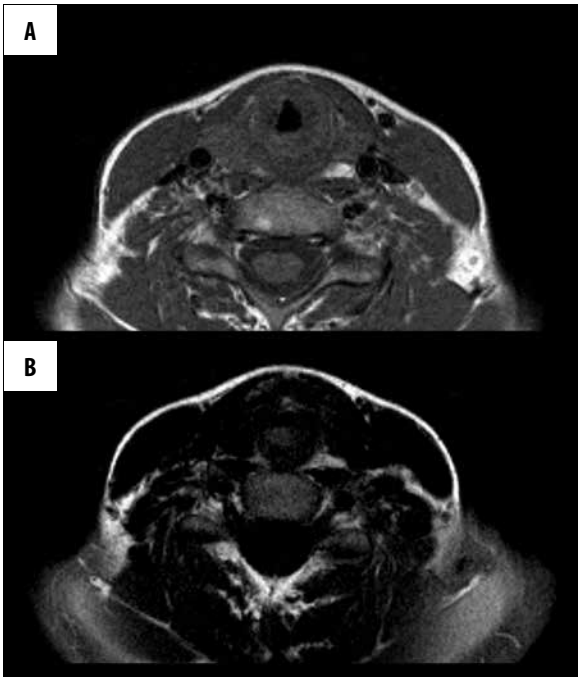

Figure 6. RM Low signal of thickened, the inflamed mucosa in the course of CP, transversal image. (**A**) T1-weighted image, MR, (**B**) T1-weighted image post cm.

each month in the clinic for laryngology and dermatology. The following MR scans revealed a slight regression of the process, (retaining) traits of infraglottic obstruction of the larynx to 6 mm on a distance of 12 mm (3mm on a distance of 35 mm at baseline), and local enhancement after administration of contrast agent, especially in the mucous membrane of the posterior commissure. The air canals and traits of lymphadenopathy were not observed, which seems to indicate that the treatment was successful (Figure 6).

Discussion

Mucous membrane pemphigoid (MMP), which is classified as one of progressive, chronic, inflammatory, autoimmune disorders, forms a clinically diverse group. It is characterised by the presence of subepithelial bullae that occur most frequently in mucous membranes, with/without the occurrence of skin lesions. As the lesions regress, scarring occurs. Lesions which are located in the mucous membrane of the larynx are moderately frequent, in comparison to lesions located elsewhere, e.g. in oral cavity, conjunctivae or pharynx [14,15].

The described case of laryngeal pemphigoid presents radiographical features of a non-specific inflammatory process, such as oedema of mucous membranes that may lead to considerable obstruction of the larynx, especially the glottis, and which requires tracheostomy in cases which may lead to asphyxiation, the possibility of regression of changes with permanent scarring of mucosa, and lack of an ambiguous signal pattern for this disease (Figure 6).

Summary

The evidence of analysed cases suggests that MR is highly useful in the diagnostics of pathological lesions in infraglottic space, as this area is difficult to examine clinically in comparison to superior parts of the larynx. CT remains the first examination in the diagnostic algorithm. However, it exhibits lower tissue resolution when compared to MRI, especially in patients with laryngeal chondroma. Because of these limitations of CT, it may seem worthwhile to extend diagnostics and include MRI, the modality that should be preferred in the differentiation between benign and malignant neoplastic lesions of the larynx, especially the infraglottic space, with the use of T1-weighted sequence, T2-weighted sequence and contrast-enhanced T1-weighted sequence, all of which complement each other.

Conclusions

1. It is possible to determine characteristic signal pattern for rare lesions of the infraglottic space in MRI.
2. MRI is a valuable complementary modality for the diagnostics and differentiation of lesions in infraglottic space, the evaluation of their advancement and treatment planning.

References:

1. Mafee FM, Valvassori GE, Becker M: Imagining of the head and neck, 2nd ed. New York, Stuttgart, Thieme, 2005; 731–843
2. Voghl TJ, Balzer J, Mack M et al: Radiodiagnostyka głowy i szyi. Czelej, 2001; 300–18 [in Polish]
3. Alberico RA, Husain SH, Sirotkin I: Imaging in head and neck oncology. Surg Oncol Clin N Am, 2004; 13(1): 13–35
4. Hermans R: Medical Radiology: Diagnostic Imagining, Head and Neck Cancer Imagin, 2nd ed. Berlin, Springer, 2012; 55–123
5. Val MR: Rezonans magnetyczny w praktyce klinicznej, Elsevier Urban & Partner, 230-34 [in Polish]
6. Becker M, Burkhardt K, Allal AS et al: Pretherapeutic and posttherapeutic laryngeal imaging. Radiologe, 2009; 49(1): 43–58
7. Rumboldt Z, Gordon L, Gordon L et al: Imaging in head and neck cancer. Curr Treat Options Oncol, 2006; 7(1): 23–34
8. Becker M: Neoplastic invasion of laryngeal cartilage: radiologic diagnosis and therapeutic implication. Eur JR, 2000; 33(3); 216–29
9. Zbären P, Becker M, Läng H: Pretherapeutic staging of hypopharyngeal carcinoma. Clinical findings, computed tomography, and magnetic resonance imaging compared with histopathologic evaluation. Arch Otolaryngol Head Neck Surg, 1997; 123(9): 908–13
10. Smee RI, Williams JR, Bridger GP: The management dilemmas of invasive infraglottic carcinoma. Clin Oncol (R Coll Radiol), 2008; 20(10): 751–56
11. Greess H, Lell M, Römer W, Bautz W: Indications and diagnostic sensitivity of CT and MRI in the otorhinolaryngology field. HNO, 2002; 50(7): 611–25
12. Gülden JW, Straehler-Pohl HJ: Chondroma of the larynx- case report and differential diagnosis in CT. Bildgebung, 1990; 57(3-4): 90–92
13. Baatenburg de Jong RJ, Van Lent S, Hogendoorn PC: Chondroma and chondrosarcoma of the larynx.Curr Opin Otolaryngol Head Neck Surg, 2004; 12(2): 98–105
14. Chan LS, Ahmed AR, Anhalt GJ et al: The first international consensus on mucous membrane pemphigoid: definition, diagnostic criteria, pathogenic factors, medical treatment, and prognostic indicators. Arch Dermatol, 2002; 138(3): 370–79
15. Freitas VA, Becker HM, Guimarães RE et al: Cicatricial pemphygoid in the upper aerodigestive tract: report of two cases. Braz J Otorhinolaryngol, 2008; 74(6): 941–44