

Received: 2013.10.04  
Accepted: 2013.11.18  
Published: 2014.03.17

Authors' Contribution:

- A** Study Design
- B** Data Collection
- C** Statistical Analysis
- D** Data Interpretation
- E** Manuscript Preparation
- F** Literature Search
- G** Funds Collection

## Occult left atrial ball-like thrombus in a patient referred for surgical removal of suspected cerebellum tumor

Olga Możeńska<sup>1</sup>Δ, Irena Kalińska<sup>1</sup>Δ, Karol Brodowski<sup>1</sup>Δ, Jerzy Walecki<sup>2</sup>Δ,  
Dariusz A. Kosior<sup>1,3</sup>Δ

<sup>1</sup> Department of Noninvasive Cardiology and Hypertension, Central Clinical Hospital of the Ministry of the Interior, Warsaw, Poland

<sup>2</sup> Department of Radiology and Diagnostic Imaging, Medical Center of Postgraduate Education, Warsaw, Poland

<sup>3</sup> Łazarski University, Warsaw, Poland

**Author's address:** Dariusz A. Kosior, Department of Noninvasive Cardiology and Hypertension, Central Clinical Hospital of the Ministry of the Interior, Wołoska Str. 137, 02-507 Warsaw, Poland, e-mail: [dariusz.kosior@cskmswia.pl](mailto:dariusz.kosior@cskmswia.pl)

### Summary

**Background:**

Atrial fibrillation and related cardio-embolic cerebrovascular accidents are two well-defined major healthcare problems worldwide. It has been approximated that 2.2 million people in America and 4.5 million in European Union have paroxysmal or persistent atrial fibrillation. And atrial fibrillation itself is an independent long-term risk factor of stroke. We present a case of patient referred to our center for surgical removal of suspected cerebellum tumor, a case that had a rather unexpected ending.

**Case Report:**

A 58-year-old male patient with a history of atrial fibrillation, congestive heart failure (NYHA II/III), stable coronary artery disease, diabetes type 2 and hyperlipidemia presented with vertigo, headaches, mainly during physical activity and increased tiredness. Performed computer tomography revealed two lesions in the cerebellum and in the left lateral chamber. The diagnosis of a proliferative disease of the cerebellum was established and patient was referred to the Neurosurgical Department. Fortunately, before the operation the echocardiography was performed, which revealed two lesions in left atrium. The decision of the Heart Team was to refer the patient for an open-heart surgery, in which two thrombi were removed. Neurosurgeons decided to withdraw from further surgery and proceed with head MRI and conservative treatment, deciding that the lesion in the cerebellum was most likely an ischemic area.

**Conclusions:**

Looking at the brain lesion should always be done from the whole patient's perspective. And using multimodality imaging may lead to appropriate diagnosis, correct course of therapeutic action and unexpected ending of a rather non-extraordinary case.

**Keywords:**

multimodality imaging • cerebellum • thrombus • atrial fibrillation

**PDF file:**

<http://www.polradiol.com/download/index/idArt/889863>

### Background

Atrial fibrillation (AF) and related cardioembolic cerebrovascular accidents are two well-defined major healthcare problems worldwide [1,2]. Approximately 2.2 million people in America and 4.5 million in the European Union suffer from paroxysmal or persistent arrhythmia [3]. Alike, the annual incidence of new or recurrent cerebrovascular accidents in for example United States amounts to app. 795 000 of which app. 87% are due to ischemia [4]. Atrial fibrillation

itself is an independent long-term risk factor of stroke [5]. The number of ischemic strokes amongst patients with nonvalvular AF is about 5% a year [6–8]. As for now, transesophageal echocardiogram (TEE) is regarded the gold standard imaging modality for detection of left atrial and/or left atrial appendage thrombi in patients with ischemic cerebrovascular accidents of suspected cardioembolic origin. This is mainly due to the ability of TEE to superiorly visualise posterior structures, such as left atrium and left atrial appendage.

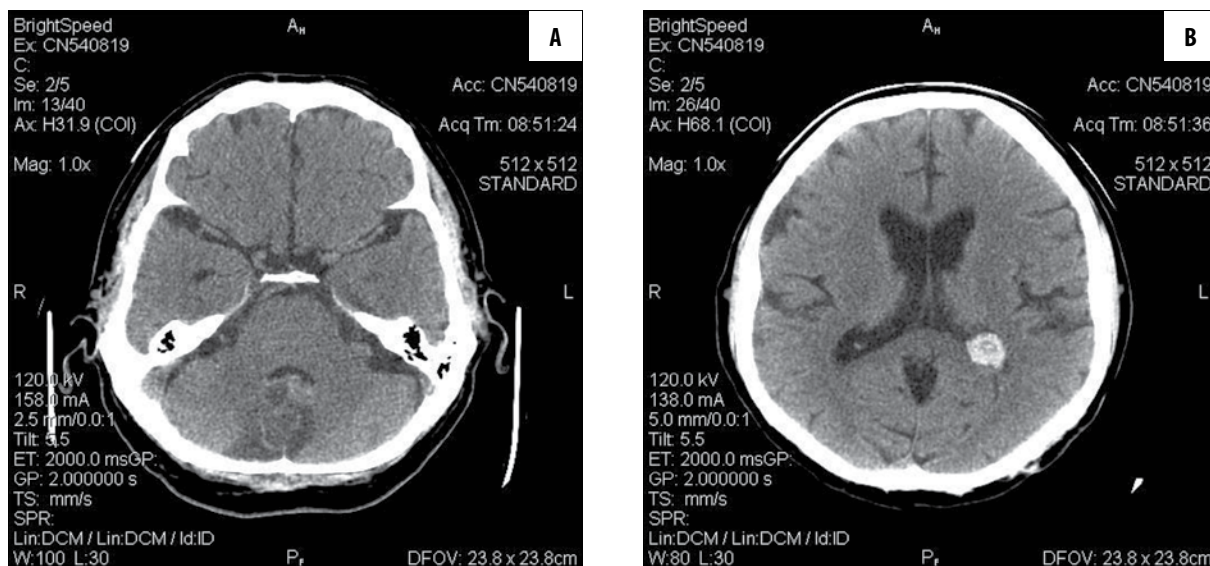


Figure 1. (A, B) Head CT without contrast.

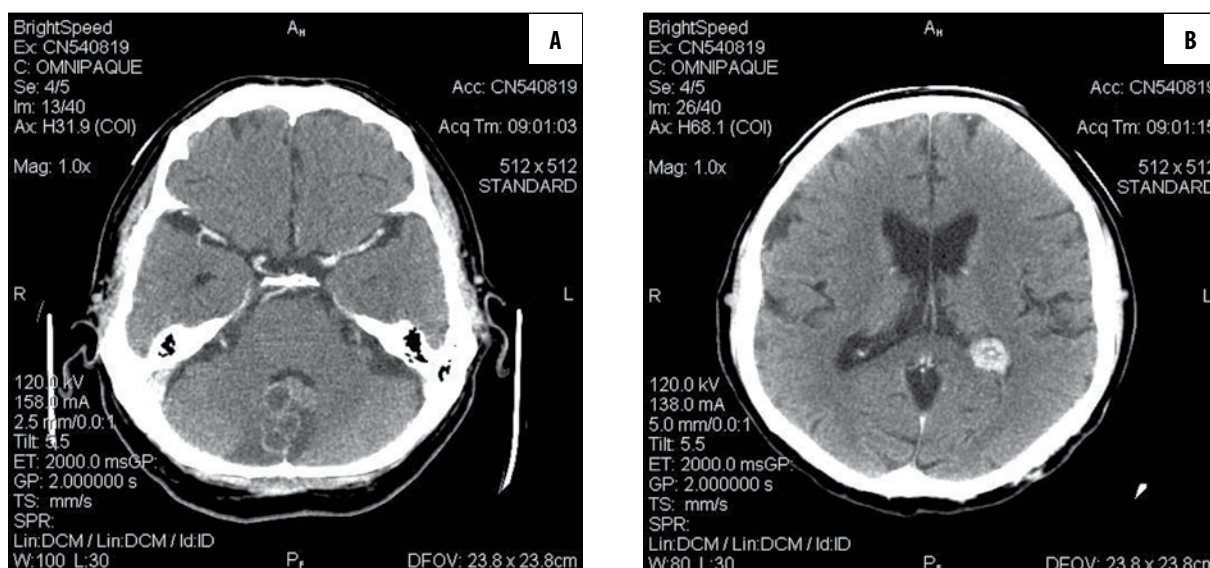


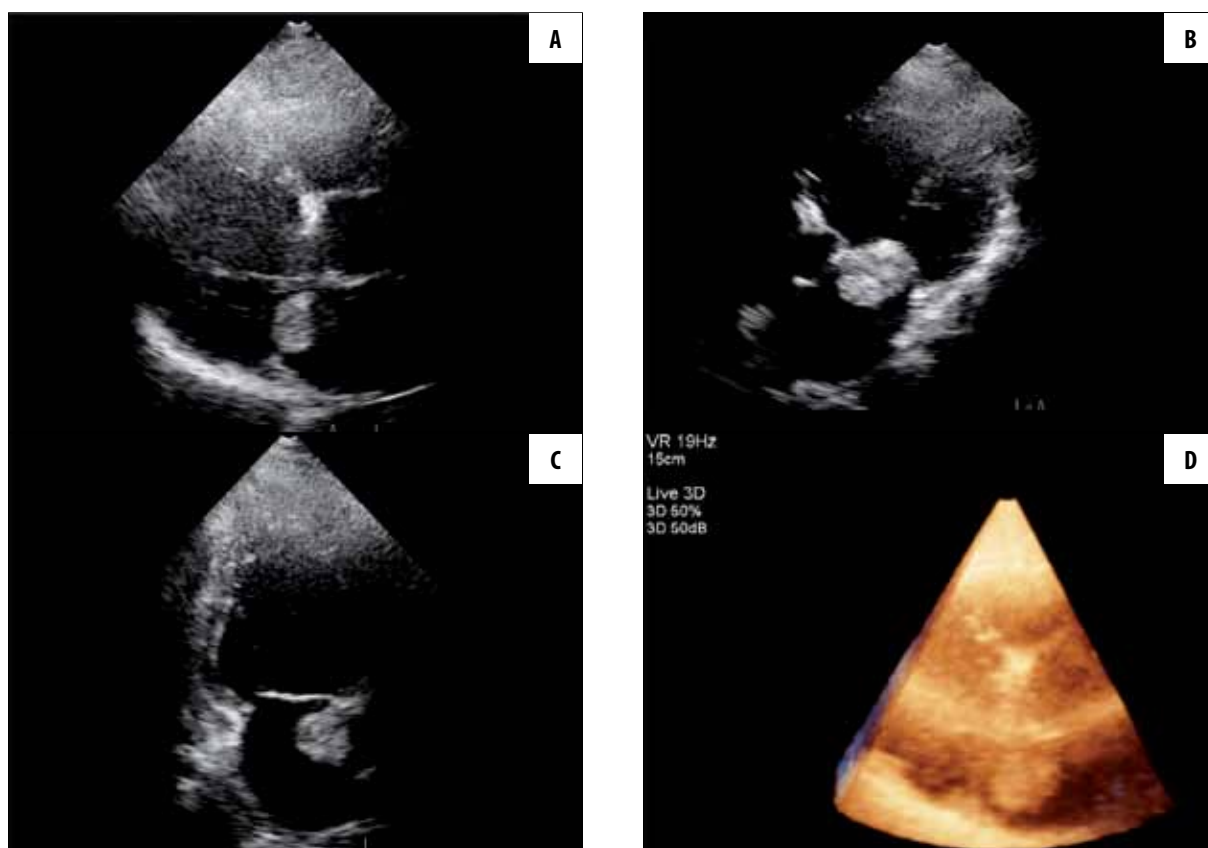
Figure 2. (A, B) Head CT with contrast.

We present a case of a 58-year-old man referred to our centre for surgical removal of suspected cerebellum tumor, a case that had a rather unexpected ending.

## Case Report

A 58-year-old male patient with a history of chronic AF, congestive heart failure (NYHA II/III), stable coronary artery disease, diabetes type 2 and hyperlipidemia presented to the Internal Disease Department with vertigo, headaches, mainly during physical activity, and increased tiredness. Later on the patient suddenly demonstrated contact deterioration, dysarthria and prolonged vertigo. Performed computed tomography (CT) revealed two lesions (Figures 1A, 1B and 2A, 2B). One was described as a cyst-like lesion  $3.1 \times 1.6$  cm in size, with septa, contrast-enhancing (requiring further studies) and the second one was described as hyperdense, located in the left lateral chamber,  $2.0 \times 1.5$  mm in size, non-enhancing, not

calcified, most likely ischemic with hemorrhagic transformation, to be differentiated with hemorrhagic tumor or metastasis. Putting together the clinical picture, laboratory data and results of imaging studies, a diagnosis of proliferative disease of the cerebellum was established and the patient was referred to our Centre to the Neurosurgical Department. Due to patient's comorbidities, neurosurgeons asked for cardiological assessment. Up till then, the patient had been thought to be adequately treated with oral anticoagulants. Echocardiography performed in our Department demonstrated two lesions: an oval mass in the left atrium free-floating into the mitral inflow tract,  $3.2 \times 2.8$  cm in size, attached to the mitral ring most likely from the anterior side of the mitral annulus as well as a second, smaller mass,  $1.1 \times 1.8$  cm in size, immobile, located near the foramen ovale (Figure 3A–3D). Both lesions had features of thrombi. Echocardiography performed 7 months earlier had revealed no heart lesions. Heart Team meeting was convened. A decision was made to refer the patient for an



**Figure 3.** (A–D) Transesophageal echocardiography.

open-heart surgery. During the operation, the right and the left atrium were opened and the surgeons removed from the left atrium: a large, 4×7 cm in size, thrombus from the mitral valve area, as well as a smaller one, 4×3 mm in size, thrombus from the area of the foramen ovale. Seeing the results of the open-heart surgery, neurosurgeons decided to withdraw from further surgery and proceed with head MRI and conservative treatment as for the time being, deciding that the lesion in the cerebellum was most likely an ischemic area.

To sum up, looking at the case backwards, we come to two main conclusions. First, more obvious one, is that head lesions are not always what they seem originally and using multimodality imaging might provide us with a final answer. The second one following from the first conclusion, adequate use of multimodality imaging lead to a final diagnosis and prevented the patient from unnecessary surgery, as well as resulted in appropriate diagnosis and adequate course of therapeutic action.

## Discussion

The D-dimer level [9], hypertension, congestive heart failure, age over 75 years, diabetes mellitus, and prior stroke or transient ischemic attack or thromboembolism score (CHADS<sub>2</sub>) [10], and brain natriuretic peptide level [11] are predictors of left atrial thrombus in patients with nonvalvular AF. What is more, these predictors simply indicate tendency to thrombogenesis. Left atrial ball thrombus is a rare condition, first recognized in autopsy in the early XIX

century. Left atrial free-floating thrombus is mostly associated with the disease of the mitral valve [12,13] but has also been acquainted in association with atrial fibrillation [14] and hypertrophic cardiomyopathy [15]. The etiology of ball thrombus formation in the lack of structural heart disease or AF is mostly unknown, but metastatic carcinoma is a diagnosis worth giving consideration to [16]. In the setting of mitral valve stenosis and AF, left atrial ball thrombus is an uncommon but recognized cause of stroke and can happen even in the presence of therapeutic anticoagulation. It is linked to higher embolic rates [17] and, even though clinical evidence is sparse, immediate surgical removal of a free-floating thrombus, often in association with mitral valve repair or replacement, is the adequate therapeutic course in most patients [18], since re-embolization on formal anticoagulation has been reported [19]. To sum up, in our case, taking a step back looking at the patient as a whole from the Heart Team's perspective, and deciding, with the use of multi-modality imaging, that the free-floating left atrial thrombus was the most 'puzzling' issue, led to what seemed an appropriate course of therapeutic action.

## Conclusions

Atrial fibrillation itself is an independent long-term risk factor of left atrial thrombus formation and stroke. We should always look at brain lesions from the perspective of 'the patient as a whole'. Using multimodality imaging may lead to appropriate diagnosis, correct course of therapeutic action and unexpected ending of a rather non-extraordinary case.

---

**References:**

---

1. Benjamin EJ, Wolf PA, D'Agostino RB et al: Impact of atrial fibrillation on the risk of death: the Framingham Heart Study. *Circulation*, 1998; 98(10): 946-52
2. Kannel WB, Wolf PA, Benjamin EJ et al: Prevalence, incidence, prognosis, and predisposing conditions for atrial fibrillation: population-based estimates. *Am J Cardiol*, 1998; 82(8A): 2N-9N
3. Feinberg WM, Cornell ES, Nightingale SD et al: Relationship between prothrombin activation fragment F1.2 and international normalized ratio in patients with atrial fibrillation. *Stroke Prevention in Atrial Fibrillation Investigators. Stroke*, 1997; 28(6): 1101-6
4. Roger VL, Go AS, Lloyd-Jones DM et al: Executive summary: heart disease and stroke statistics – 2012 update: a report from the American Heart Association. *Circulation*, 2012; 125(1): 188-97
5. Mugge A, Kuhn H, Nikutta P, Grote J et al: Assessment of left atrial appendage function by biplane transesophageal echocardiography in patients with nonrheumatic atrial fibrillation: identification of a subgroup of patients at increased embolic risk. *J Am Coll Cardiol*, 1994; 23(3): 599-607
6. Wolf PA, Dawber TR, Thomas HE Jr et al: Epidemiologic assessment of chronic atrial fibrillation and risk of stroke: the Framingham study. *Neurology*, 1978; 28(10): 973-77
7. Levy S, Maarek M, Coumel P, Guize L et al: Characterization of different subsets of atrial fibrillation in general practice in France: the ALFA study. *The College of French Cardiologists. Circulation*, 1999; 99(23): 3028-35
8. Flegel KM, Shipley MJ, Rose G: Risk of stroke in non-rheumatic atrial fibrillation. *Lancet*, 1987; 1(8532): 526-29
9. Habara S, Dote K, Kato M et al: Prediction of left atrial appendage thrombi in non-valvular atrial fibrillation. *Eur Heart J*, 2007; 28(18): 2217-22
10. Wysokinski WE, Ammash N, Sobande F et al: Predicting left atrial thrombi in atrial fibrillation. *Am Heart J*, 2010; 159(4): 665-71
11. Okada Y, Shibazaki K, Kimura K et al: Brain natriuretic peptide is a marker associated with thrombus in stroke patients with atrial fibrillation. *J Neurol Sciences*, 2011; 301(1-2): 86-89
12. Schafer RO, Evers G, Morgan P et al: Left atrial ball thrombus in combined mitral-aortic valve disease. *Eur Heart J*, 1992; 13(2): 287-88
13. Dua A, Sharma D, Siwach SB: Left atrial ball thrombus: echocardiographic features and clinical implications. *J Assoc Phys India*, 1994; 42(8): 637-38
14. Tanoue K, Sonoda M, Maeda N et al: A novel clinical course of free-floating left atrial ball thrombus without mitral stenosis treated by anticoagulants. *J Cardiol*, 2009; 54(2): 297-99
15. Gurcun U, Boga M, Ozkisacik EA et al: Left atrial free-floating ball thrombus in a case of hypertrophic cardiomyopathy. *J Thrombosis and Thrombolysis*, 2005; 20(1): 39-41
16. Mansour KA, Malone CE, Craver JM: Left atrial tumor embolization during pulmonary resection: review of literature and report of two cases. *Ann Thorac Surg*, 1988; 46(4): 455-56
17. Tsioufis CP, Stefanadis CI, Tsiamis EG et al: A free floating ball thrombus in the left atrial cavity. *J Thorac Cardiovasc Surg*, 1999; 118(6): 1120-22
18. Wrisley D, Giambartolomei A, Lee I et al: Left atrial ball thrombus: review of clinical and echocardiographic manifestations with suggestions for management. *Am Heart J*, 1991; 121(6 Pt 1): 1784-90
19. Blazer D, Degroat T, Kotler MN et al: Peripheral embolization during thrombolytic therapy for left atrial thrombus. *Am J Cardiol*, 1986; 58(6): 554-55