



Received: 2015.05.18
Accepted: 2015.07.29
Published: 2015.12.01

Authors' Contribution:

- A** Study Design
- B** Data Collection
- C** Statistical Analysis
- D** Data Interpretation
- E** Manuscript Preparation
- F** Literature Search
- G** Funds Collection

Kawasaki Disease: Diagnosis and Follow-Up by CT Coronary Angiography with the Use of 128-Slice Dual Source Dual Energy Scanner. A Case Report

Abdel-Naser Ghareep^{1A,B,C,D,E,F}, Maryam Alkuwari^{1A,C,D,F}, Francis Willington^{1B,C,D},
Wojciech Szmigielski^{2E,F}

¹ Clinical Imaging Department, Heart Hospital, Hamad Medical Corporation, Doha, Qatar

² Clinical Imaging Department, National Center for Cancer Care and Research, Hamad Medical Corporation, Doha, Qatar

Author's address: Wojciech Szmigielski, Clinical Imaging Department, National Center for Cancer Care and Research, Hamad Medical Corporation, P.O. Box 3050 Doha, Qatar, e-mail: w.szmigielski@gmail.com; wszmigielski@hamad.qa

Background:

Kawasaki Disease (KD) is a rare acute febrile illness due to multi-organ vasculitis. It most often affects children under five years of age. Coronary artery aneurysms are seen in about 25% of children with KD. Selective invasive coronary angiography was considered to be the gold standard for diagnosis and follow-up of coronary artery aneurysms, thrombosis and stenosis in patients with KD. Echocardiography is a non-invasive tool for imaging of this condition but it does have some limitations. Recently, a high-quality multislice CT coronary angiography has been advocated in the diagnosis of KD.

Case Report:

We report a case of a 5-year-old boy who was diagnosed with Kawasaki disease and followed up by CT coronary angiography, which provided required excellent imaging findings in the terms of the number, size and location of coronary aneurysms.

Conclusions:

Based on imaging results of our case it can be stated that high-quality CT coronary angiography with the use of multi-slice dual source ultra-fast scanner can be considered a better and safer non-invasive diagnostic tool, an alternative to invasive catheter selective coronary angiography in the diagnosis and long-term follow-up of patients with KD, especially when echocardiographic images are limited or technically challenging.

MeSH Keywords:

Coronary Aneurysm • Coronary Angiography • Diagnosis • Mucocutaneous Lymph Node Syndrome • Multidetector Computed Tomography • Tomography, Spiral Computed

PDF file:

<http://www.polradiol.com/abstract/index/idArt/894680>

Background

Kawasaki Disease (KD) is an acute febrile illness caused by multi-organ vasculitis, characterized by fever, desquamative skin rash, conjunctival and pharyngeal injection, swelling of the hands and feet and cervical lymphadenopathy [1,2]. Coronary artery aneurysms are seen in about 25% of children with KD, especially those under five years of age. Approximately 50% of these aneurysms may completely regress in the first few years after diagnosis. The morbidity and mortality in KD is due to coronary artery aneurysm thrombosis, coronary artery stenosis, myocardial ischemia and infarction. Although, echocardiography

can be used to assess proximal coronary arterial aneurysms, cardiac catheterization with coronary angiography is considered the gold standard [2,3]. However, the recent advances in multi-slice CT technology have made it possible to noninvasively diagnose and sequentially follow up patients with KD who have coronary artery aneurysms [4,5].

Case Report

A 5-year-old male developed high-grade fever, which responded incompletely to the antipyretic treatment. He was then noticed to have a large right submandibular

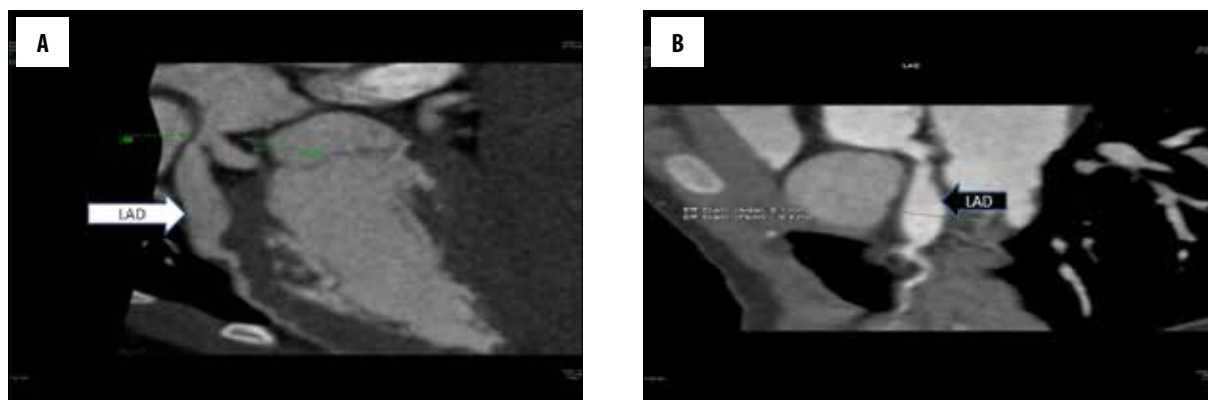


Figure 1. CT coronary angiography of a 5-year-old boy with Kawasaki disease. (A) Initial study: LAD artery aneurysm; (B) Follow-up study: stationary course of aneurysmatic dilatation of LAD artery.

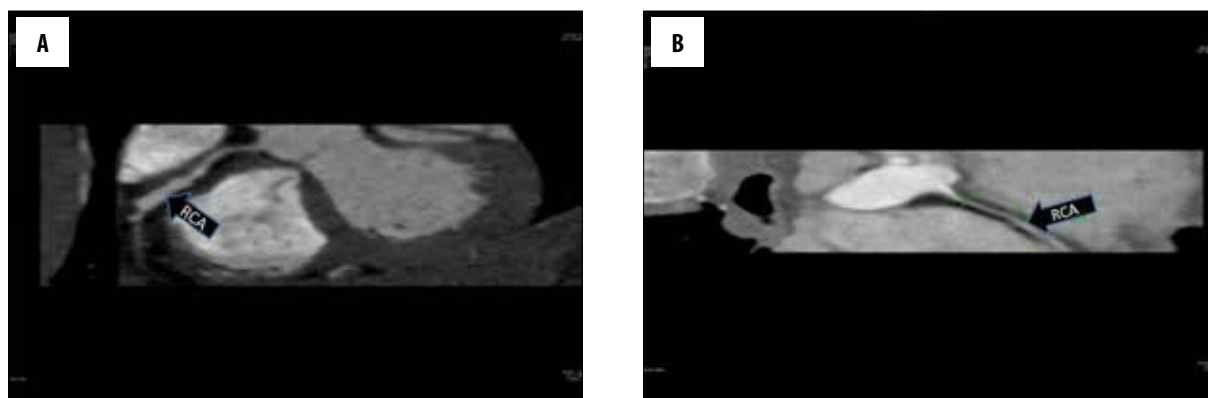


Figure 2. CT coronary angiography of a 5-year-old boy with Kawasaki disease. (A) Initial study: RCA aneurysm; (B) Follow-up study: almost complete disappearance of RCA aneurysm.

lymph node that was warm and tender with erythematous rash over it. Subsequently, he developed polymorphous rash all over the body, hands and feet edema, strawberry tongue and red cracked lips. The fever continued for nine days. On day 9 of his illness, he was diagnosed as a case of KD and he was given intravenous immunoglobuline (IVIG). After that, the fever subsided and rash started to disappear.

Serial echocardiograms were done and revealed mild right and left coronary artery dilatation with left anterior descending artery (LAD) aneurysm and mildly dilated ventricles with good contractility. Cardiac catheterization was contraindicated and not done since the coronary arteries were dilated with high inflammatory markers. Consequently, CT coronary angiography was carried out with prospective electrocardiogram gating on a 128-slice, dual source scanner (Somatom Definition Flash, Syngo CT 2011A, Erlangen, Germany). The study was performed without beta-blocker administration. After a test bolus for optimal contrast timing, a total of 50 mL (1.5 mL/kg of patient body weight) of non-ionic low-osmolar contrast agent (Visipaque 320, GEHC, Princeton, NJ) followed by 30 mL of 0.9% saline was administered with a flow rate of 6 mL/sec through a 20-gauge cannula placed within the antecubital vein with the use of a pressure injector. Breath hold time was 12 s and heart rate during scan acquisition was 80 beats/min. ECG-gated CT angiography was performed with a collimation of 12×0.75 mm, table feed of 0.28 mm/rotation, 100 kV with automatic dose modulation and a

rotation speed of 330 ms. Post-processing assessment was performed using Syngovia and Circulation cardiac package, enabling both vessel probes, curved MPR, MIP and 3D reconstructions.

CT coronary angiography demonstrated a short dilated left main coronary artery (LM), LAD aneurysm in the proximal and mid segments about 3.7 cm long and about 10 mm in diameter (Figure 1A). Right coronary artery (RCA) was non-dominant and showed an aneurysmal dilation in the mid segment about 1.5 cm in length and 4.5 mm in diameter (Figure 2A). Dilatation of the whole course of the circumflex artery (CX) was seen with a maximum transverse diameter of about 6 mm (Figure 3A). The second obtuse marginal branch showed proximal localized dilatation (4.4 mm in diameter).

A follow-up CT coronary angiography performed 6 months later showed almost complete disappearance of the aneurysmal dilatation seen previously in RCA (Figure 2B), regression of the ectasia of the CX artery (Figure 3B) and stationary appearance of the aneurysmal dilatation of LAD (Figure 1B).

Discussion

No general consensus has been reached regarding the most acceptable diagnostic method for KD when echocardiography is suboptimal [6]. Although CT coronary angiography

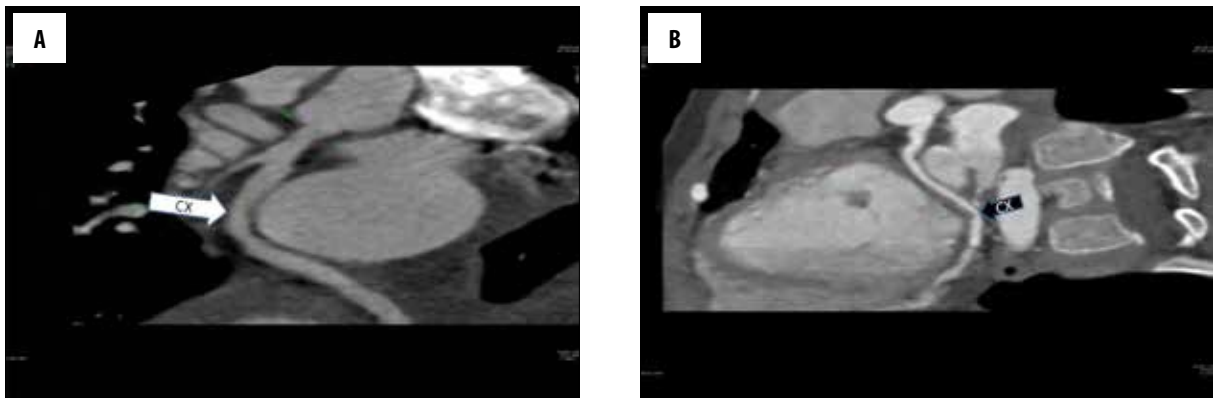


Figure 3. CT coronary angiography of a 5-year-old boy with Kawasaki disease. (A) Initial study: CX artery aneurysm; (B) Follow-up study: regression of ectasia of CX artery.

does not remove the risk of intravascular contrast administration and radiation associated with conventional angiography, it does not expose children to the risk of possible procedural and vascular complications associated with invasive coronary angiography [4]. Moreover, the need for repetitive procedures for follow-up of the coronary aneurysms increases the probability of the above mentioned procedural complications associated with conventional angiography. In addition, CT can be performed without the need for hospitalization that is required prior to and after invasive coronary angiography in order to administer intravenous anticoagulants and then restart oral anticoagulants after an invasive angiogram. We would like to emphasize the fact that despite the heart rate of our patient was about 80 b/m, we managed to carry out both studies without the need for beta-blocker injections and thus we avoided potential complications. That was possible since we used

very efficient dual source fast scanner with 128 detector rows.

Based on the results of our case, we found that CT coronary angiography provided us with all required imaging results in the terms of the number, size and location of coronary aneurysms, necessary for diagnosis and follow-up.

Conclusions

CT coronary angiography with the use of dual source dual energy ultra-fast scanner can be considered a better and safer non-invasive diagnostic tool, an alternative to invasive catheter selective coronary angiography in the diagnosis and long-term follow-up of patients with giant coronary aneurysms in KD, especially when echocardiographic images are limited or technically challenging.

References:

1. Kato H1, Sugimura T, Akagi T et al: Long term consequences of Kawasaki disease. A 10–21 year follow-up study of 594 patients. *Circulation*, 1996; 94: 1379–85
2. Frey E, Matherne G, Mahoney L et al: Coronary artery aneurysms due to Kawasaki disease: diagnosis with ultrafast CT. *Radiology*, 1988; 167: 725–26
3. Capanari T, Daniels S, Meyer R et al: Sensitivity, specificity and predictive value of two-dimensional echocardiography in detecting coronary artery aneurysms in patients with Kawasaki disease. *J Am Coll Cardiol*, 1986; 7: 355–60
4. Aggarwala G, Iyengar N, Burke SJ: Kawasaki disease: role of coronary CT angiography. *Int J Cardiovasc Imaging*, 2006; 22: 803–5
5. Khositseth A1, Siripornpitak S, Pornkul R, Wanitkun S: Giant coronary aneurysm caused by Kawasaki disease: follow-up with echocardiography and multidetector CT angiography *Br J Radiol*, 2008; 81(964): 106–9
6. Naiser JA, Schaller FA, Bannout R, Tak T: Kawasaki disease causing giant saccular aneurysm of the coronary arteries. *Tex Heart Inst*, 2008; 35(3): 369–70