



Received: 2014.12.28
Accepted: 2015.01.18
Published: 2015.04.22

Authors' Contribution:

- A** Study Design
- B** Data Collection
- C** Statistical Analysis
- D** Data Interpretation
- E** Manuscript Preparation
- F** Literature Search
- G** Funds Collection

Extraosseous, Epidural Cavernous Hemangioma with Back Pain

Birol Ozkal^{1AB}, Can Yaldiz^{2BE}, Onur Yaman^{3A}, Nail Ozdemir^{4DE}, Sedat Dalbayrak^{5ABCD}

¹ Department of Neurosurgery, Alanya Government Hospital, Antalya, Turkey

² Department of Neurosurgery, Sakarya University Training and Research Hospital, Sakarya, Turkey

³ Department of Neurosurgery, University of Koc, Istanbul, Turkey

⁴ Department of Neurosurgery, Izmir Tepecik Training and Research Hospital, Izmir, Turkey

⁵ Department of Neurosurgery, Neurospinal Academy, Istanbul, Turkey

Author's address: Can Yaldiz, Department of Neurosurgery, Sakarya University Training and Research Hospital, Sakarya, Turkey, e-mail: drcanyaldiz@yahoo.com

Summary

Background:

Cavernous malformations are characterized by enlarged vascular structures located in benign neural tissues within the cerebellum and spinal cord of the central nervous system. Cavernous hemangiomas (CHs) account for 5% to 12% of all spinal vascular malformations.

Case Report:

We removed a hemorrhagic thoracic mass in a 40-year-old male patient who presented with progressive neurological deficits.

Conclusions:

We found it appropriate to present this case due to its rarity.

MeSH Keywords:

Epidural Neoplasms • Hemangioma, Cavernous, Central Nervous System • Spine

PDF file:

<http://www.polradiol.com/abstract/index/idArt/893424>

Background

Cavernous malformations are characterized by vascular structures comprising enlarged vascular beds located in benign neural tissues within the cortex, cerebellum, and spinal cord of the central nervous system [1]. Cavernous hemangiomas (CHs) account for 5% to 12% of all spinal vascular malformations. They are usually accompanied by bone involvement. CHs are usually believed to be multiple in the central nervous system [5]. However, bone involvement is rare in the epidural area. Only 0.22/1 000 000 (4%) of all cavernous hemangiomas are pure epidural cavernous hemangiomas [2,3]. The diagnosis of cavernous hemangiomas has increased with the introduction of magnetic resonance imaging (MRI). Clinical symptoms include slowly progressing paraparesis, radiculopathy, and localized pain. Radiological tests cannot provide a definitive diagnosis. MRI thus far is the best diagnostic instrument [4,5]. This case was reported on because it is rare.

Case Report

A 40-year-old male patient was admitted to our clinic with complaints of back pain that had started 6 months before.

On the neurological examination, hypoesthesia was present, matching the T12–L1 levels. There was no urine or fecal incontinence. The laboratory tests were within normal limits.

The bi-directional X-rays were normal. On the thoracic, lumbar, and cervical MRI performed for further investigation, a mass lesion along the T12–L1 vertebral levels, which was hypointense on T1-weighted images (Figure 1A) with a slightly lower signal than the cerebrospinal fluid (CSF) on T2-weighted images (Figure 1B) and heterogeneous gadolinium-enhanced T1-weighted images (Figure 1C), was observed.

After the routine tests were completed, the patient underwent T12–L1 total laminectomy under general anesthesia. A dark hemorrhagic encapsulated mass, approximately 1.5×2 cm in size, with soft consistency in the epidural space without invasion of the dura, was localized on the right, posterolaterally, and was completely excised microsurgically (Figure 2). A histopathologically cavernous hemangioma composed of large, dilated, blood-filled vessels lined by a flattened endothelium, was observed (Figure 3).

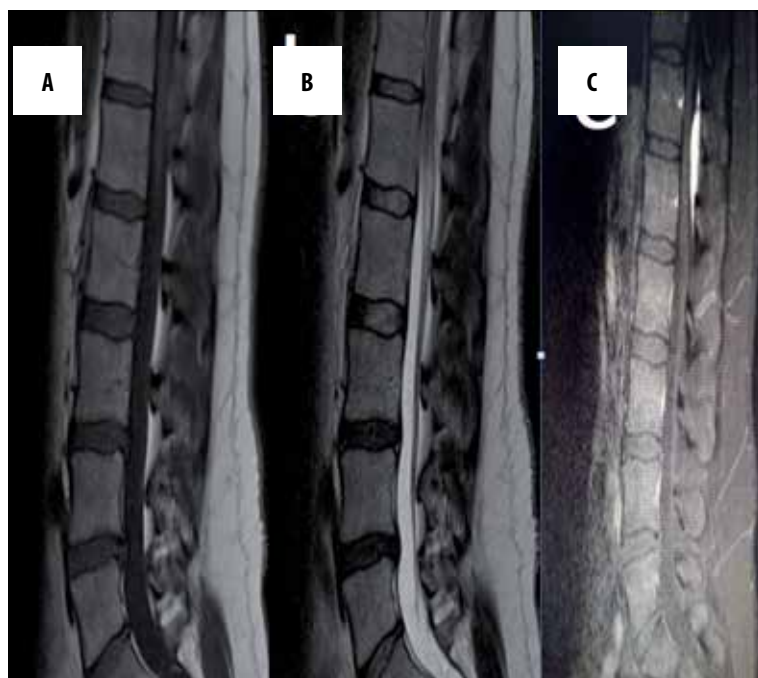


Figure 1. Magnetic resonant imaging, mass lesion along the T12–L1 vertebral levels, which was hypointense on T1-weighted images (A), with a slightly lower signal than CSF on T2-weighted images (B). Heterogeneous gadolinium-enhanced T1-weighted images (C)

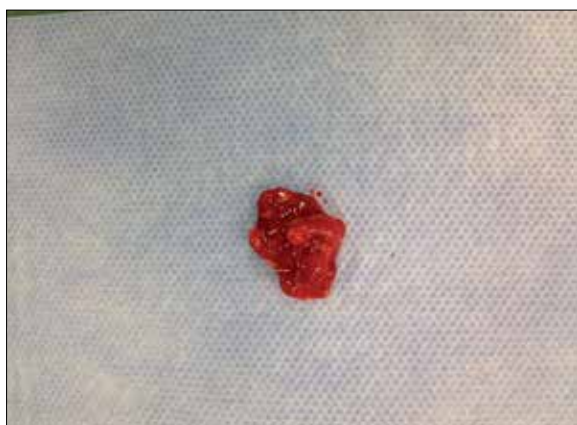

Figure 2. 0.5×1 cm extradural hemorrhagic reddish mass.

No additional neurological deficits were observed during the postoperative period. The first control MRI of the patient was performed after 10 days, and the patient was pain-free. There was no residue on the control MRI (Figure 4A, 4B).

Discussion

CHs refer to a group of small capillaries covered by a single layer of endothelium and characterized by lobules, which are made up of irregular and dilated sinusoidal vascular canals that show hypertrophic growth, usually without mitotic activity, but with fibrous connective tissue separated by the septa [6]. Globus and Doshay first described cavernous hemangiomas in 1929 [5,7]. CHs are not real neoplasms. Clinical symptoms are caused by the mass effect, vascular movements, hemorrhage, thrombosis, cyst, or cavern formation [5]. CHs may occur in any part of the body. Cavernous hemangioma of the central nervous system is most common in the supratentorial area of the cranial region [7].

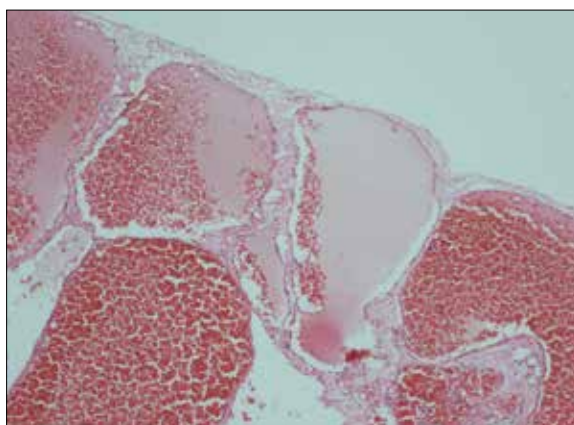


Figure 3. Postoperative MRI shows no mass in the operation area. The mass was completely removed.

However, cavernous hemangioma in the spinal canal is rare. Only 4% (0.22/1 000 000) of all cavernous hemangiomas are pure epidural cavernous hemangiomas. Spinal CHs are more common in women (70%) than in men, and the average age is 40 (age varies from 30 to 60). Their size may vary significantly. The most common location of a CH is the posterolateral spinal canal (19%). Aoyagi et al. showed in their series that 90% of CHs were located in the epidural region. CHs are found in the spinal vertebrae in the thoracic (58%), cervical (26%), lumbar (16%), and epidural space, in order of frequency [2,3]. A study by Li et al. [4], one of the largest in the literature, involved 14 patients. Among them, 9 had thoracic, 3 had cervical, and 1 had vertebral cavernous hemangioma in the lumbar spine. In a study by Aoyagi et al., 80% constituted thoracic epidural cavernous hemangiomas. The location of the tumor in our 40-year-old male patient was consistent with the literature.

Two hypotheses have been suggested in the literature for the high incidence rate of thoracic vertebral hemangiomas.

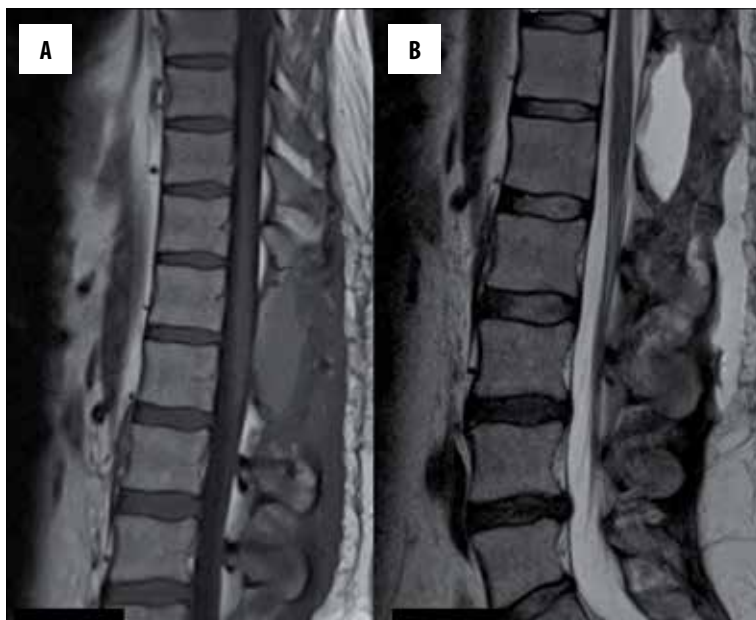

Figure 4. Preoperative T1-weighted MRI sagittal image shows a homogenous contrasted epidural mass at the T12 and L1 levels (A), and the axial T1-weighted MRI shows a mass in the epidural space (B).

The first one involves the large size of the thoracic epidural space, while the second one involves the poor resistance of the posterior thoracic spinal canal as the reason for high incidence rates [2,3].

CH develops due to acute clinical hemorrhage or thrombosis [5,7]. The most common clinical picture is slowly progressing paraparesis (71%) and radiculopathy (19%). The clinical picture varies depending on the location, size, and biological behavior of CH causing the mass effect. In a study by Li et al., 13 out of 14 patients presented due to complaints of myelopathy, while in a study by Aoyagi et al. [8], 18 out of 54 patients presented due to myelopathy, and 19 due to radiculopathy [2–4]. In our case, the clinical symptoms included back pain.

Spinal MRI is the best available radiological diagnostic tool, although the existing radiological tests fail to provide a definitive diagnosis for the preoperative period. MR imaging requires differential diagnosis. The most common differential is the schwannoma. However, CH may also be confused with neurogenic tumors, metastasis, lymphoma, meningioma, multiple myeloma and extraosseous Ewing's sarcoma, and epidural angiolioma. On MRI, CH presents as well defined and lobulated, isointense on T1-weighted images and hyperintense on T2-weighted images, while showing intense, homogeneous contrast enhancement in contrast-enhanced images. Intramedullary CHs show a hypointense ring caused by peripheral hemosiderin deposits and heterogeneous signal intensity at the center. However, this is not the case for epidural hemangiomas [5,7].

References:

- Hegde A, Mohan S, Tan KK et al: Spinal cavernous malformations: magnetic resonance imaging and associated findings. *Singapore Med J*, 2012; 53(9): 582–86
- Zhong W, Huang S, Chen H et al: Pure spinal epidural cavernous hemangioma. *Acta Neurochir (Wien)*, 2012; 154 (4): 739–45
- A L H, T R, Chamarthy NP Puri K: A pure epidural spinal cavernous hemangioma – with an innocuous face but a perilous behaviour!! *J Clin Diagn Res*, 2013; 7(7): 1434–35
- Li TY, Xu Y, Yang J et al: Primary spinal epidural cavernous hemangioma: clinical features and surgical outcome in 14 cases. *J Neurosurg Spine*, 2015; 22(1): 39–46

Spinal CHs are classified into four groups based on the MR images: arteriovenous type with an organized hematoma, venous type, cavernous type, and cavernous type with hematoma [4].

CHs are prone to bleeding and enlarging. Therefore, early surgical removal is recommended. The surgical goal should be total removal at the first surgery. Severe perioperative bleeding and anterior location may hinder total removal. Bleeding is rare in intramedullary CHs. Severe bleeding may occur in epidural CHs. Adjuvant therapy (RT) may be required for cases in which bleeding and location hinder total removal [5,7]. Recurrence was observed in 3 of the 14 patients in a series by Li et al. [4]. Our case is currently at follow-up month 11, and no recurrence has been observed.

Conclusions

In the central nervous system, there are many CHs [5] but epidural CHs with no bone involvement are rare non-neoplastic vascular malformations. They lead to different images on MRI. Differential diagnosis with epidural schwannoma is very difficult on MRI [7]. Early surgery is recommended, since clinical success depends on the preoperative neurological deficit as the most effective prognostic factor. Total removal is the best treatment method. In case of recurrence, it may be useful to repeat surgery with decompression. Adjuvant RT is recommended for subtotal removal.

5. Khalatbari MR, Abbassioun K, Amirjmsghidi A: Solitary spinal epidural cavernous angioma: report of nine surgically treated cases and review of the literature. *Eur Spine J*, 2013; 22(3): 542–47
6. Babu R, Owens TR, Karikari IO et al: Spinal cavernous and capillary hemangiomas in adults. *Spine (Phila Pa 1976)*, 2013; 38(7): E423–30
7. Sharma MS, Borkar SA, Kumar A et al: Thoracic extraosseous, epidural, cavernous hemangioma: Case report and review of literature. *J Neurosci Rural Pract*, 2013; 4(3): 309–12
8. Aoyagi N, Kojima K, Kasai H: Review of spinal epidural cavernous hemangioma. *Neurol Med Chir (Tokyo)*, 2003; 43(10): 471–75