



Received: 2016.06.07
Accepted: 2016.08.09
Published: 2017.03.22

Authors' Contribution:

- A** Study Design
- B** Data Collection
- C** Statistical Analysis
- D** Data Interpretation
- E** Manuscript Preparation
- F** Literature Search
- G** Funds Collection

Pulsatility Index of Popliteal Artery in Patients with Isolated Calf Vein Thrombosis: A Novel Technique for Detecting Thrombosis

Abdussamet Batur^{1AB}, Vural Polat^{2B}, Mesut Ozigokce^{1D}, Muhammed Alpaslan^{1E}, Alpaslan Yavuz^{1B}, Harun Arslan^{1B}, Aydin Bora^{1B}, Mehmet Emin Sakarya^{3G}

¹ Department of Radiology, Yuzuncuyil University, Dursun Odabas Medical Center, Van, Turkey

² Department of Cardiovascular Surgery, Yuzuncuyil University, Dursun Odabas Medical Center, Van, Turkey

³ Department of Radiology, Necmettin Erbakan University, Meram School of Medicine, Konya, Turkey

Author's address: Abdussamet Batur, Department of Radiology, Yuzuncu Yil University, Faculty of Medicine, 65080, Van, Turkey, e-mail: baturabdussamet@gmail.com

Summary

Background:

To investigate the usefulness of popliteal artery spectral doppler findings as a complimentary approach to isolated calf vein thrombosis (DVT).

Material/Methods:

We included consecutive patients presenting with symptomatic and sonographically proven acute isolated calf DVT. Patients with thrombosis of any other vein were excluded. We classified calf vein into into four main types. We investigated how many of these four vessels had DVT and compared them with respect to the pulsatility index (PI) value of the popliteal artery.

Results:

We evaluated spectral doppler characteristics of the popliteal artery on the same side as the isolated calf vein thrombosis as well as on the opposite side. The relationship between PI values of the popliteal artery and the number of thrombosed calf veins was investigated. In patients with 1 and/or 2 thrombosed veins, the mean PI was 6.03 ± 0.54 on the side of cDVT and 5.68 ± 0.39 on the opposite side ($p=0.008$), respectively. Inpatients with 3 and/or 4 thrombosed veins, the mean PI was 8.05 ± 0.61 on the side of cDVT and 6.34 ± 0.47 on the opposite side ($p=0.001$), respectively.

Conclusions:

Venous doppler sonography for the evaluation of calf DVT may be limited by patient characteristics such as obesity, edema, and tenderness., Arterial PI can be used as a complimentary technique for the detection of venous thrombosis in such of cases.

MeSH Keywords:

Popliteal Artery • Ultrasonography, Doppler, Pulsed • Venous Thrombosis

PDF file:

<http://www.polradiol.com/abstract/index/idArt/899949>

Background

Deep vein thrombosis (DVT) is the third most common cardiovascular disease after acute coronary syndromes and stroke [1,2]. DVT of the legs can result in symptoms that range from mild to the life-threatening pulmonary embolism (PE) [3]. It is considered to be the most common cause of death that may be prevented in hospitalized patients [4]. Most DVTs is believed to begin in the calves [5]. Because of that, early diagnosis through appropriate investigations is essential in reducing the risk of fatal PE [6].

Ultrasonography is the method of choice in patients with suspected DVT due to its noninvasive nature, high sensitivity and specificity in symptomatic patients, wide availability, portability, and low cost [7]. In contrast to other areas of DVT, the accuracy of US imaging in the detection of calf DVT is highly variable [1]. It may be associated with the fact that distal thrombosis is less symptomatic or even asymptomatic, leading to diagnostic difficulties [4]. Because of the low reported accuracy and high incidence of nondiagnostic studies, US of the calves for DVT is not routinely performed [5].

Moreover, the evaluation of calf veins can be difficult or limited in patients with obesity, marked swelling, and overlying casts [5]. Considering these disadvantages, in this study we investigated the usefulness of the popliteal artery spectral doppler findings as an alternative approach for the diagnosis of calf DVT.

Material and Methods

Patients

This study included patients diagnosed with isolated calf vein thrombosis based on US findings. Briefly, between September 2009 and October 2015 we enrolled 2816 patients admitted for clinically suspected DVT. Thrombosis was diagnosed on the basis of venous incompressibility, loss of phasicity in the spontaneous venous signal, visualization of thrombus or the absence of flow despite augmentation.

The diagnosis of an acute DVT, as shown with duplex Doppler, was made in 812 patients. One hundred and eight (13.3%) of them (mean age: 58.3 ± 12.7 , ranged between 23 and 82 years) had unilateral isolated calf vein thrombosis. We included consecutive patients presenting with symptomatic and sonographically proven acute isolated calf DVT. Patients with thrombosis of any other vein except for calf veins were excluded. We prospectively evaluated spectral doppler characteristics of the popliteal artery of these 108 patients. A triplex ultrasound examination of both lower extremities was performed in all patients.

Calf veins were defined as axial veins (peroneal, posterior tibial and anterior tibial veins), and muscular calf veins (soleal or gastrocnemius veins). We classified them as four main vein types. Because the reported rate of tibial anterior DVT is very low, tibial anterior DVTs were classified together with tibial posterior DVTs. We investigated how many of these four vessels were affected by DVT and compared the number of affected veins with respect to the pulsatility index (PI) value of the popliteal artery.

Technique

Real-time B-mode ultrasound, with color flow and spectral capability was performed for the diagnosis of cDVT (Logiq GE, GE Healthcare, Mil-waukee, USA, with a 9L linear 8 MHz transducer). With the patient in the supine position, the common femoral vein, deep and superficial femoral veins were examined with B-mode ultrasonography. Similarly, with the patient in the prone position, the popliteal vein and calf veins were examined as well. The posterior and anterior tibial veins were followed from the level of the ankle to the upper calf, with the knees slightly flexed and externally rotated. Then, the popliteal artery and vein as well as peroneal, soleal and gastrocnemius veins were examined in the prone position with the knee flexed at 30 degrees. Patients who could not keep the prone position were examined in the lateral decubitus position. The knee was supported on a small pillow to relieve any muscle tension or guarding. The opposite limb was checked as reference. In order to characterize arterial blood flow, PI was calculated from the duplex flow profile according to the following formula: $PI = (\text{peak systolic} - \text{end diastolic}) / \text{mean velocity}$ (Figure 1).

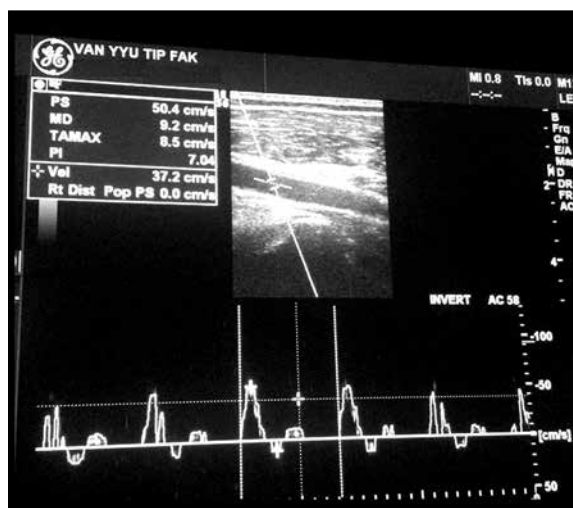

Figure 1. Duplex doppler sonographic image of the popliteal artery demonstrating pulsatility index, as described in the materials and methods section.

Table 1. Frequency counts for patients with cDVT.

Clinical parameter	No. (%)
Right-sided	68 (62.96)
Left-sided	40 (37.04)
Inpatients	63 (58.33)
Outpatients	45 (41.67)
Malignancy	40 (37.03)
Chronic diseases	28 (25.92)
Post-op.	20 (18.51)
No disease	20 (18.51)

Results

A total of 216 lower extremities with unilateral isolated thrombi in the calf veins of 108 patients (72 men and 36 women) were examined with sonography. Sixty-eight patients (62.96%) had right-sided thrombosis, and 40 had left-sided ICVT (37.04%), respectively. Sixty-three patients (58.33%) were inpatients, and 45 (41.67%) were outpatients. Of 108 patients, 40 (37.03%) presented with malignancy, 28 (25.92%) had chronic diseases, 20 (18.51%) had a history of surgery, and 20 (18.51%) had an unremarkable history (Table 1).

We examined the number of thrombosed deep calf veins within the four groups (peroneal, posterior tibial soleal, and gastrocnemius veins). Of 108 patients, 24 (22.2%) had thrombosis in only one of these veins, 32 (29.6%) in two veins, 40 (37.1%) in three veins, and 12 (11.1%) in four veins (Table 2). The statistical correlation was performed by accepting the median value of "2" as a reference. The most frequently involved vein was the soleal vein ($n=62$), the second most common vein involved was the peroneal vein ($n=38$). Less commonly involved veins were the

Table 2. Number of cDVT in limbs with multiple thrombi.

Number of thrombosed veins	No. (%)
Thrombosis in one vein	24 (22.2)
Thrombosis in two veins	32 (29.6)
Thrombosis in three veins	40 (37.1)
Thrombosis in fourveins	12 (11.1)

Table 3. Number of thrombosed calf deep veins.

Location of deep vein thrombosis	No. of limbs
Soleal vein	62
Peroneal vein	38
Gastrocnemial vein	29
Posterior tibial vein	25

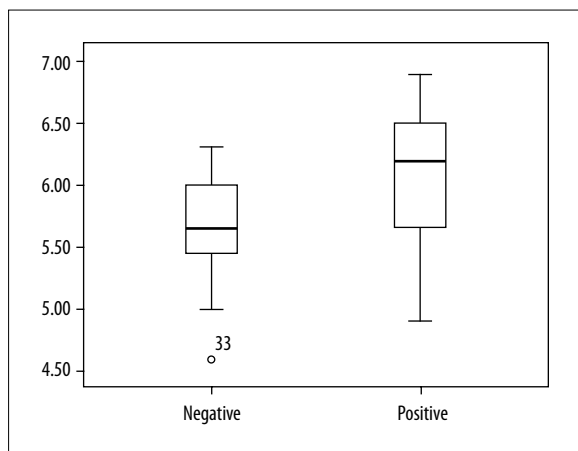


Figure 2. Box plot comparing the pulsatility index of the popliteal arteries on the same side as isolated calf vein thrombosis and on the opposite side in patients with 1 and/or 2 thrombosed veins ($p=0.008$).

gastrocnemius vein ($n=29$) and then the posterior tibial vein ($n=25$) (Table 3). The least commonly involved vein was the anterior tibial with only 6 positive results.

We evaluated spectral doppler characteristics of the popliteal artery on the same side as the isolated calf vein thrombosis and on the opposite side as well. We evaluated the relationship between the PI values of the popliteal artery and the number of thrombosed calf veins. In patients with 1 and/or 2 thrombosed veins, the mean PI was 6.03 ± 0.54 on the side of cDVT and 5.68 ± 0.39 on the opposite side ($p=0.008$), respectively (Figure 2). In patients with 3 and/or 4 thrombosed veins, the mean PI was 8.05 ± 0.61 on the side of cDVT and 6.34 ± 0.47 on the opposite side ($p=0.001$), respectively (Figure 3). A ROC curve for the difference between PI values of the popliteal artery on the side of cDVT and on the normal side is shown in Figure 4. A PI cut-off value greater than 6.25 yielded sensitivity and specificity values of 68.5% and 64.8%, respectively ($p=0.001$). The intraclass correlation coefficient for the PI of the popliteal artery was 76.3% (95% CI, .669–.856).

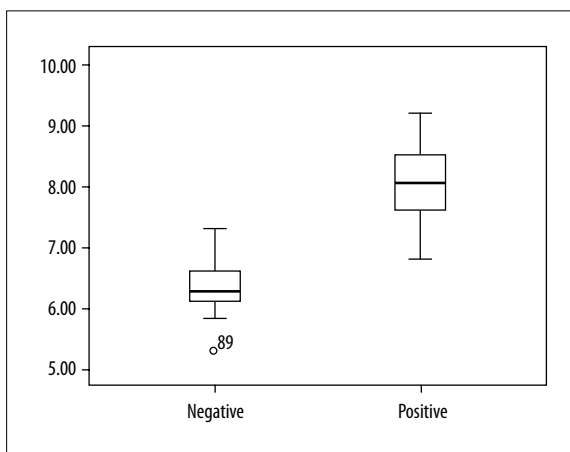


Figure 3. Box plot comparing the pulsatility index of the popliteal arteries on the same side as isolated calf vein thrombosis and on the opposite side in patients with 2 and/or 3 thrombosed veins ($p=0.001$).

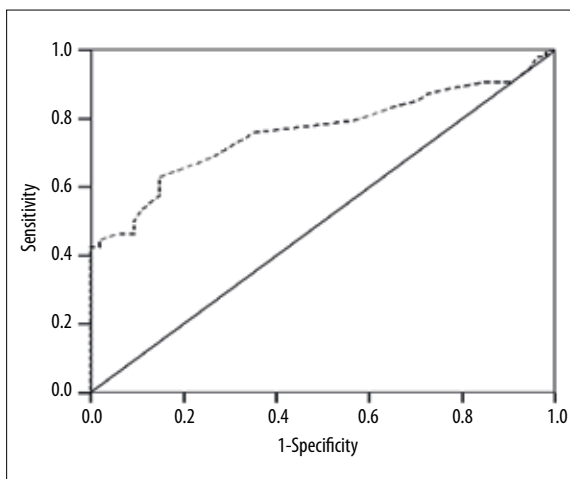


Figure 4. Receiver operating characteristic (ROC) curve for the difference between pulsatility index values of the popliteal artery on the side of cDVT and on the normal side. The area under the curve for diagnosing cDVT was .763 (95% confidence interval, .669–.856).

Discussion

A thrombus often forms in the distal region of the calf veins without DVT. This is known as isolated calf vein thrombosis (ICVT). Within a week, such thrombi can spread to proximal veins in up to 25% of untreated patients, often leading to deep calf vein thrombosis [3,8]. Ferrara et al. [9] reported that propagation and recurrence were significantly higher in case of two calf vein thrombi as opposed to a single vein clot. Indeed, ICVT is more strongly associated with transient risk factors, whereas proximal DVT is more likely to result from a chronic condition. This could suggest that the clinical condition of patients might vary according to the level of symptomatic isolated DVT. This may partly explain why, if one assumes that most DVTs originate in the muscle calf veins, only a limited number of them will extend proximally [10].

Ultrasound studies have revealed that in up to 17–33% of all DVT patients the problems originate from calf veins and can cause PE [7,10]. Thus, early diagnosis of isolated calf vein thrombosis is essential, as it may prevent the propagation of thrombosis from calves to thighs and subsequent PE, and decrease the risk of serious long-term complications that are associated with the condition [1].

Venous doppler US is the primary imaging modality for the diagnosis of lower extremity DVT. Although sonography is regarded as highly accurate in detecting thigh DVT, there is uncertainty as to the issue of its effectiveness in detecting calf DVT [1]. Because calf veins are smaller and characterized by slower flow, the US assessment is more difficult than in the proximal lower extremity veins. Additionally, venous compressibility may be limited by patient characteristics such as obesity, edema and tenderness [11].

In the present study, we demonstrated that arterial PI can be used for the detection of venous thrombosis in difficult situations described above. The PI is considered to be a sensitive index in differentiating vascular changes. It relates to arterial resistance of the vessels distal to the analyzed point [12]. The systolic acceleration time of the waveform is influenced by abnormalities proximal to the measurement site, whereas the decay of the velocity tends to relate to the distal circulation. In studies conducted in body parts other than the extremities, it has been reported that during elevated adjacent pressure the arterioles are easily compressed creating high peripheral vascular resistance [13] due to the capillary leakage of plasma proteins, erythrocytes and leukocytes with resultant edema, tissue hypoxia and damage [14].

In our study, the PI of the popliteal artery was significantly increased on the side of cDVT in comparison to the opposite side ($p=0.001$). The difference between PI of the affected and non-affected extremities was more pronounced when more than two calf veins were thrombosed. Based on the above-described pathogenesis, it can be said that periarteriolar pressure increases together with the number of thrombosed veins. According to these findings, the number of thrombosed veins was associated with increased perivascular pressure. Similarly, it is associated with propagations and recurrence as reported by Ferrara et al. [9]. In the differential diagnosis, nonvascular causes of edema such as cellulitis can be considered, whereas spectral doppler recordings in patients with infections demonstrate hyperemic flow with reduced pulsatility [15].

Conclusions

Early diagnosis of isolated calf vein thrombosis is essential, because it may prevent propagation of thrombosis from calves to thighs. Venous doppler US is regarded as highly accurate in detecting thigh DVT, however, there is uncertainty regarding its effectiveness in detecting calf DVT. Furthermore, it may be limited by patient characteristics such as obesity, edema, and tenderness. Arterial PI can be used as a complimentary technique for the detection of venous thrombosis in difficult situations described above.

Conflict of Interest

The authors declare that they have no conflict of interest.

References:

- Kloog I, Zanobetti A, Nordio F, Coull BA et al: Effects of airborne fine particles (PM_{2.5}) on deep vein thrombosis admissions in the northeastern United States. *J Thromb Haemost*, 2015; 13: 768–74
- Bucciarelli P, Maino A, Felicetta I et al: Association between red cell distribution width and risk of venous thromboembolism. *Thrombos Res*, 2007; 5: 692–99
- Su LY, Guo FJ, Xu G et al: Differential diagnosis of isolated calf muscle vein thrombosis and gastrocnemius hematoma by high-frequency ultrasound. *Chin Med J*, 2015; 136: 590–94
- Hotoleanu C, Fodor D, Suci O: Correlations between clinical probability and Doppler ultrasound results in the assessment of deep venous thrombosis. *Med Ultrasound*, 2010; 12: 17–21
- Arnoldussen CW, Wittens CH: Computed tomography and magnetic resonance venography of lower extremity deep vein disease. *PanVascular Medicine*, 2015; 4389–98
- Lee YM, Ting ACW, Cheng SWK: Diagnosing deep vein thrombosis in the lower extremity: Correlation of clinical and duplex scan findings. *Hong Kong Med J*, 2002; 8(1): 9–11
- Singh K, Yakoub D, Giangola P et al: Early follow-up and treatment recommendations for isolated calf deep venous thrombosis. *J Vasc Surg*, 2012; 55: 136–40
- Wang KL, Chu PH, Lee CH et al: Management of venous thromboembolisms: Part I. The consensus for deep vein thrombosis. *Acta Cardiol Sin*, 2016; 32: 1–22
- Ferrara F, Meli F, Amato C et al: Optimal duration of treatment in surgical patients with calf venous thrombosis involving one or more veins. *Angiology*, 2006; 57: 418–23
- Galanaud JP, Sevestre MA, Genty C et al: Comparison of the clinical history of symptomatic isolated muscular calf vein thrombosis versus deep calf vein thrombosis. *J Vasc Surg*, 2010; 52: 932–38
- Tapson VF, Carroll BA, Davidson BL et al: The diagnostic approach to acute venous thromboembolism. Clinical practice guideline. American Thoracic Society. *Am J Respir Crit Care Med*, 1999; 160(3): 1043–66
- Martins WP, Natri CO, Ferriani RA, Filho FM: Brachial artery pulsatility index change 1 minute after 5-minute forearm compression. *J Ultrasound Med*, 2008; 27: 693–99
- Bellner J, Romner B, Reinstrup P et al: Transcranial doppler sonography pulsatility index (PI) reflects intracranial pressure. *Surg Neurol*, 2004; 62: 45–51
- Hopkins NE, Wolfe JH: ABC of vascular disease, deep venous insufficiency and occlusion. *BMJ*, 1992; 304: 107–10
- Thrush A, Hartshorne T: *Peripheral vascular ultrasound: How, Why and When* (2nd ed.), New York: Elsevier Churchill Livingstone, 2004