

(53)

Characteristic features of choroidal tumors in Deep Range Imaging Optical Coherence Tomography

Cechy charakterystyczne guzów wewnątrzgałkowych w optycznej koherentnej tomografii (DRI-OCT)

Bożena Romanowska-Dixon^{1,2}, Anna Markiewicz^{1,2}, Barbara Jakubowska²,
Anna Romanowska-Pawliczek³

¹ Department of Ophthalmology and Ocular Oncology of the Jagiellonian University, Medical College, Cracow, Poland

Head: Professor Bożena Romanowska-Dixon, MD, PhD

² Department of Ophthalmology and Ocular Oncology University Hospital on Cracow, Poland

Head: Professor Bożena Romanowska-Dixon, MD, PhD

³ University of Texas Health Science Center, Houston, United States

Head: Jenifer Juranek, MD, PhD

Summary:	Presentation of literature review and own experience in imaging of characteristic features of choroidal tumors in Deep Range Imaging Optical Coherence Tomography.
Key words:	choroidal tumors, intraocular tumors, Deep Range Imaging Optical Coherence Tomography (DRI-OCT).
Streszczenie:	Zaprezentowano przegląd literatury medycznej oraz własne doświadczenia z zakresu obrazowania charakterystycznych cech guzów naczyniówki uwidocznionych w badaniu optycznej koherentnej tomografii.
Słowa kluczowe:	guzy naczyniówki, guzy wewnątrzgałkowe, optyczna koherentna tomografia (DRI-OCT).

Introduction

The choroid, which is located between retina and sclera, constitutes the middle, pigmented, highly vascular layer of the eye. It is made up of three layers: the external vessel layer, the capillary layer and the internal sheet-like Bruch's membrane. The main function of the choroid is to nourish the outer layers of the retina.

Choroidal tumors

Choroid can be affected by benign and malignant processes (tumors, neoplasms), choroidal nevus, choroidal melanoma, choroidal metastases, choroidal hemangioma, choroidal osteoma and others.

Benign melanocytic tumors of the choroid, such as choroidal nevi, are very common and pose no health risks, unless they show signs of malignancy, in which case they are considered melanomas.

Many of small choroidal melanomas are located close to optic nerve and macula and any treatment modality used to destroy the tumor, can cause high risk for severe decrease or loss of visual acuity. However, watchful waiting in potentially malignant lesion can lead to metastases. It could be crucial to find non-invasive diagnostic method for differentiation between lesion types.

Imaging techniques

Diagnosis of choroidal lesions is generally based on observation and measurements of cross-sectional ultrasound ima-

ges, A and mostly B presentation. The color fundus photography is also useful for documentation.

Optical coherence tomography (OCT) has become an excellent, noninvasive imaging technique for evaluation, measurement and observation of retinal and optic nerve disorders. In conventional OCT methods, light scatter by the retinal pigment epithelium and choroidal vasculature limits and degrades the choroidal images. The enhanced depth imaging optical coherence tomography (EDI-OCT) enables cross sectional imaging of the retina with resolution approaching histologic sections and choroidal mapping. Noori et al. observed that vascular choroidal changes play certain roles in the development of chorioretinal disorders. Establishing the use of topographic choroidal thickness and choroidal volume in choroidal lesions and providing a normative database is important for the choroidal neoplasms detection, evaluation and follow up. Topcon's 3D OCT combines color fundus photography with new OCT technology to capture a cross-sectional image of the fundus using light interference phenomenon. The 3D OCT system enables three-dimensional observation of the fundus by capturing image of both the surface and internal condition of the fundus.

Deep range imaging optical coherence tomography (DRI-OCT) examinations were performed in patients with choroidal lesions diagnosed, observed and treated in Department of Ophthalmology and Ocular Oncology University Hospital of Jagiellonian University in Krakow. There were benign and malignant

neoplasms: choroidal nevus, choroidal melanoma, choroidal metastases, choroidal hemangioma, and choroidal osteoma. The novelty of our approach involves evaluating choroidal tumors and an ability to make differential diagnosis of most common choroidal neoplasms. Below, we present choroidal neoplasms cases in DRI-OCT examination with description of typical features.

Choroidal nevus

Choroidal nevus is benign lesion. Shah et al. and Shields et al. described the typical features of choroidal nevus imaged with EDI-OCT. They found that typical for choroidal nevus are: gentle contour, choroidal shadowing (94%), choriocapillaris compression (94%), photoreceptors loss (43%), irregularity of the inner/outer (IS/OS) photoreceptor segment junction (37%) and retinal pigment epithelium detachment (8%) (1–3). Sometimes, subretinal fluid can be present above the nevus. Depending on chronicity of subretinal fluid overlying choroidal nevus, photoreceptors can appear shaggy, chronic with stalactite or chronic with retracted photoreceptors cleft (2). We have observed all these features in the DRI-OCT examination of choroidal nevus. The most common finding in our patients was uniform choroidal shadowing with well-defined borders present within the same choroidal layer where the tumor was situated, choriocapillaris compression and gentle contour (Fig. 1a., b.).

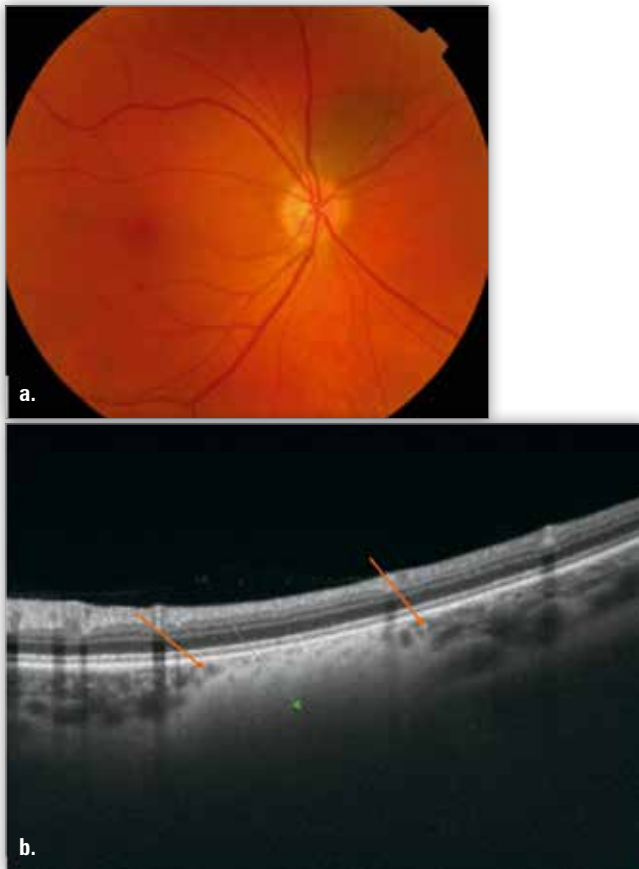


Fig. 1. Choroidal nevus in funduscopy (a.) and DRI-OCT (b.), characteristic features: choriocapillaris compression – red arrows, choroid shadowing – green arrow.

Ryc. 1. Widok dna oka ze znamieniem naczyniówki (a.) i DRI-OCT z charakterystycznymi cechami (b.) uciśnięcie choriokapilar – czerwone strzałki, cień naczyniówki – zielona strzałka.

Rarely, an irregularity (not flat) line between inner and outer photoreceptors segment junction was demonstrated.

Choroidal melanoma

Shields et al. examined 37 eyes with small choroidal melanoma with EDI-OCT and compared these images with results of nevus examination. They observed that melanoma is thicker, often with the presence of subretinal fluid and subretinal lipofuscin deposition, and with retinal irregularities including shaggy photoreceptors. The shaggy photoreceptors were found in 49% small choroidal melanoma. Shields et al. postulate that shaggy photoreceptors represent swollen photoreceptor tips or lipofuscin-laden macrophages clinging to the underside of the photoreceptors (2, 3). In choroidal melanoma, we also demonstrated choriocapillaris compression, choroidal shadowing and, more often, a layer of subretinal fluid thicker than in nevus (Fig. 2a., b.). The subretinal fluid volume in melanoma is primarily caused by highest permeability of pathological tumour vessels. However, there are no objective methods which enable its evaluation.

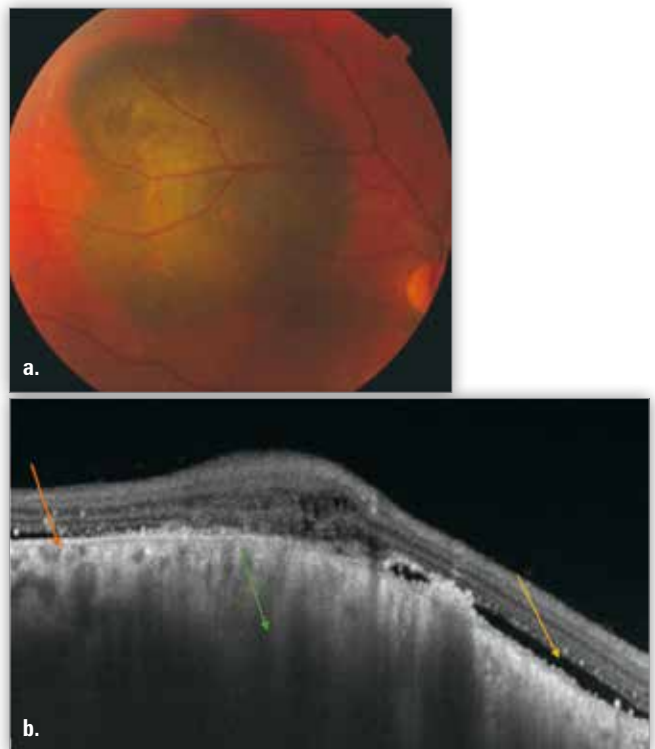


Fig. 2. Large choroidal melanoma – in funduscopy (a.) and DRI-OCT (b.), characteristic features: choriocapillaris compression – red arrow, subretinal fluid – yellow arrow, choroidal shadowing – green arrow.

Ryc. 2. Duży czerniak naczyniówki – widok dna (a.) i DRI-OCT z charakterystycznymi cechami (b.) uciśnięcie choriokapilar – czerwona strzałka, płyn podsiadkówkowy – żółta strzałka, cień naczyniówki – zielona strzałka.

Choroidal metastasis

Choroidal metastases are the most common intraocular tumors in adult patients. There is usually no problem with accurate diagnosis in such cases, but when small metastasis occurs as the only one lesion, in one eye, without positive oncological history, it can be mistaken for amelanotic melanoma or osteoma. We consider DRI-OCT very helpful in such cases.

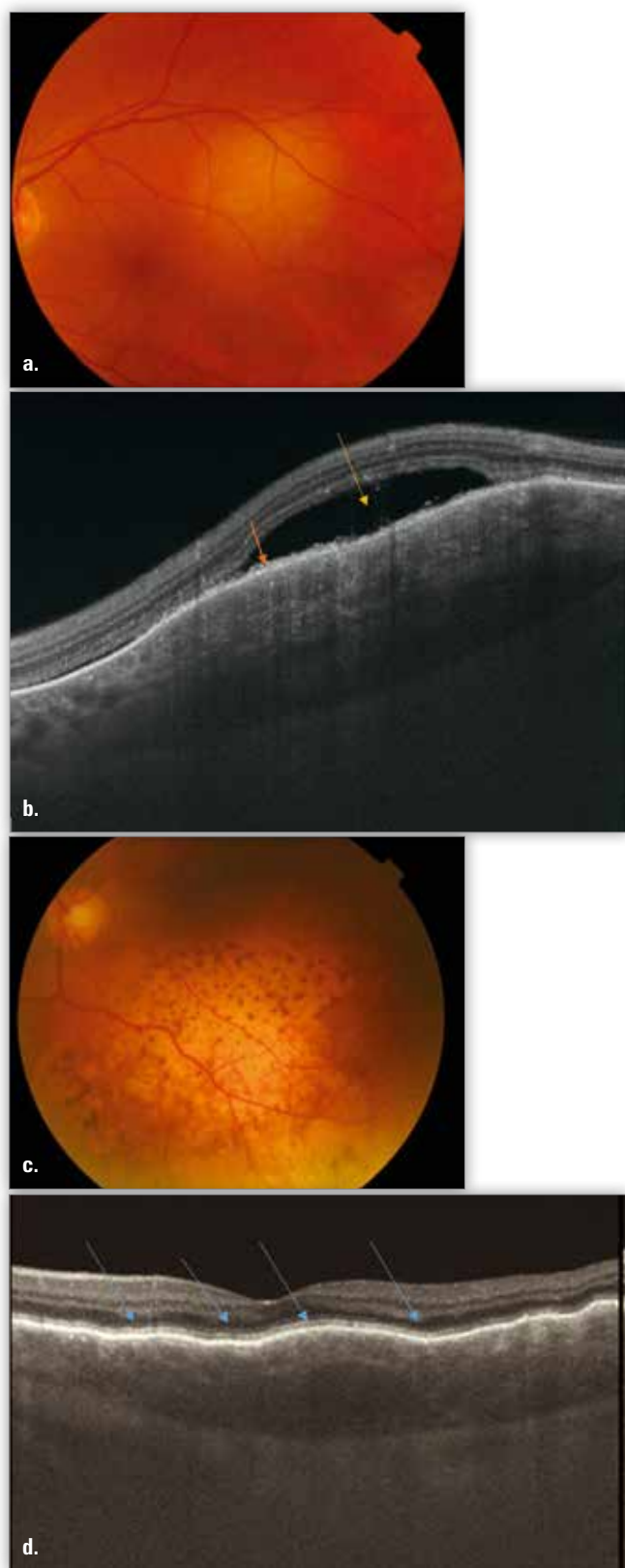


Fig. 3. Choroidal metastasis in funduscopy (a., c.) and DRI-OCT (b., d.), characteristic features: macrophages lipofuscin – orange arrow, subretinal fluid – yellow arrow, (d) lumpy-bumpy contour – blue arrows, (b., d.) choriocapilaris compression.

Ryc. 3. Przerzuty do naczyniówki – dno oka (a., c.) i DRI-OCT z charakterystycznymi cechami (b.) makrofagi z lipofuscyną – pomarańczowa strzałka, płyn podsiatkówkowy – żółta strzałka, (d.) pofalowana i wyboista powierzchnia – niebieska strzałka, (b., d.) ucisk choriokapilar.

Shields et al. carried out EDI-OCT-based observation of metastatic tumors, distinguishing such characteristic features as: lumpy-bumpy contour – like rough path from simple car computer games, choriocapilaris compression, photoreceptor loss, subretinal fluid and subretinal debris such as macrophages with lipofuscin (Fig. 3a.–e.) (2).

Choroidal circumscribed hemangioma

Our choroidal hemangioma patients presented in DRI-OCT with a characteristic dome-shaped tumor, subretinal fluid with or without cystoid retinal edema, no compression of choriocapilaris, tumor choroidal vessels are extended and no choroidal shadowing. Sometimes we found more typical features such as: wing tumor shape and indistinct margins of optical shadow. Shields et al. reported the same hemangioma features using EDI-OCT (Fig. 4) (2, 4).

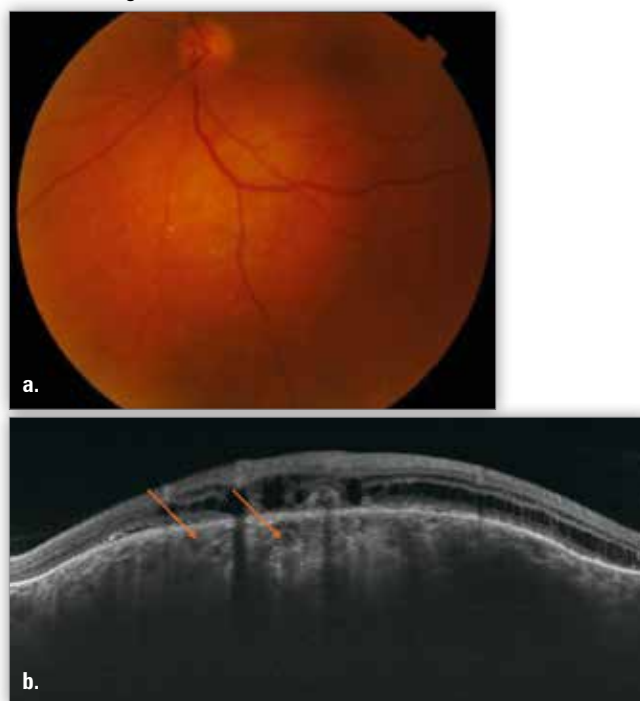


Fig. 4. Choroidal circumscribed hemangioma in funduscopy (a.) and DRI-OCT (b.), characteristic features: subretinal fluid with cystoid retinal edema, no compression of choriocapilaris, extended choroidal tumor vessels – bright red arrows.

Ryc. 4. Ograniczony naczyniak naczyniówki – widok dna (a.) i DRI-OCT z charakterystycznymi cechami (b.) obecność płynu podsiatkówkowego z cystowatym obrzękiem plamki, brak ucisku choriokapilar, poszerzone naczynia guza – jasnoczerwone strzałki.

Choroidal osteoma

Choroidal osteoma is a rare, benign tumor affecting mostly young women and located within the posterior pole. It should be particularly differentiated from amelanotic choroidal melanoma or metastatic tumors. Modern examinations, such as DRI-OCT, can be useful to establish correct diagnosis. Typical features of choroidal osteoma in DRI-OCT include: smooth undulating surface, multiple intra-lesional layers, sponge bone structure, presence of vessels, transparency with visibility of sclero-choroidal junction (Fig. 5a., b.). The same features characteristic of choroidal osteoma were confirmed in EDI-OCT by Pellegrini and SS-OCT by Hayashi (5, 6).

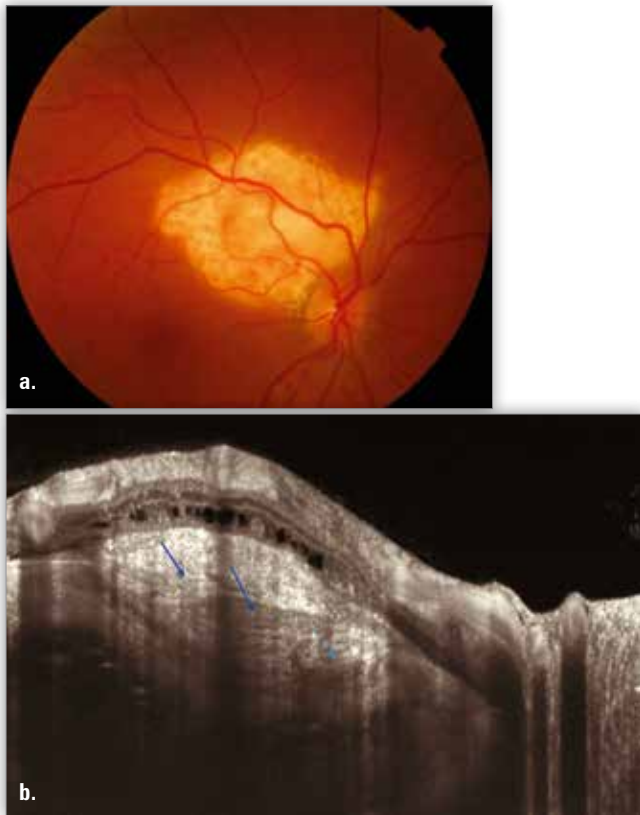


Fig. 5. Choroidal osteoma – funduscopy (a.) and DRI-OCT (b.), characteristic features: smooth undulating surface, multiple intra-lesion layers – blue arrows, sponge bone structure, presence of vessels, transparency with visibility of sclero-choroidal junction.

Ryc. 5. Kostniak naczyniówki – widok dna oka (a.) i DRI-OCT z charakterystycznymi cechami (b.) pofalowana powierzchnia, struktura wielowarstwowa – niebieskie strzałki, obecność fragmentów o budowie kości gąbczastej, obecność naczyń w obrębie zmiany, przezroczystość guza z widoczną granicą między naczyniówką a twardówką.

Conclusion

DR-OCT is a very useful tool in differential diagnosis of choroidal neoplasms. Every case of choroidal lesions has a characteristic DRI-OCT presentation, which is helpful in establishing correct diagnosis. For example, typical features of choroidal osteoma include transparency and sponge bone structure, of hemangioma – no compression of choriocapilaris and extending vessels and of metastasis – its lumpy-bumpy contour.

References:

1. Shah SU, Kaliki S, Rojanaporn D, Ferenczy SR, Shields JA: *Enhanced depth imaging optical coherence tomography of choroidal nevus in 104 cases*. *Ophthalmology*. 2012; 119(5): 1006–1072.
2. Shields CL: *EDI-OCT of Intraocular Tumors*, *Retina Today* November/December 2013: 62–65.
3. Shields CL, Kaliki S, Rojanaporn D, Ferenczy SR, Shields JA: *Enhanced depth imaging optical coherence tomography of small choroidal melanoma, comparison with choroidal naevus*. *Arch Ophthalmol*. 2012; 130(7): 850–856.
4. Shields CL, Pellegrini M, Ferenczy SR, Shields JA: *Enhanced depth imaging optical coherence tomography of intraocular tumors: from placid to seasick to rock and rolling topography – the 2013 Francesco Orzalesi Lecture*. *Retina*. 2014 Aug; 34(8): 1495–1512.
5. Pellegrini M, Invernizzi A, Giani A, Staurengi G: *Enhanced depth imaging optical coherence tomography features of choroidal osteoma*. *Retina*. 2014; 34(5): 958–963.
6. Hayashi Y, Mitamura Y, Egawa M, Semba K, Nagasawa T: *Swept-Source Optical Coherence Tomographic Findings of Choroidal Osteoma*. *Case Rep Ophthalmol*. 2014; 5: 195–202.

The paper was originally received 20.05.2016 (KO-00046-2016)/
Praca wpłynęła do Redakcji 20.05.2016 (KO-00046-2016)
Accepted for publication 07.09.2016 r./
Zakwalifikowano do druku 07.09.2016 r.

Reprint requests to (Adres do korespondencji):

prof. dr hab. n. med. Bożena Romanowska-Dixon
ul. Kopernika 38
31-501 Kraków
e-mail: romanowskadixonbozena1@gmail.com

Polskie Towarzystwo Okulistyczne

www.pto.com.pl

e-mail: pto@pto.com.pl