

FOLIA MEDICA CRACOVIENSIA

Vol. LVI, 4, 2016: 43–50

PL ISSN 0015-5616

Quantitation of condylar position in temporomandibular joint. A methodological study

PIOTR PEŁKA¹, STEPHEN WILLIAMS¹, MARCIN LIPSKI², BARTŁOMIEJ W. LOSTER¹

¹Department of Orthodontics, Dental Institute, Faculty of Medicine, Jagiellonian University Medical College
ul. Montelupich 4/108, 31-155 Kraków, Poland

²Department of Anatomy, Faculty of Medicine, Jagiellonian University Medical College
ul. Kopernika 12, 31-034 Kraków, Poland

Corresponding author: Piotr Pełka, Department of Orthodontics, Dental Institute,
Faculty of Medicine, Jagiellonian University Medical College,
ul. Montelupich 4/108, 31-155 Kraków, Poland
E-mail: p.pelka@uj.edu.pl

Abstract: Ten CBCT scans of asymptomatic patients were evaluated on sagittal slices to obtain condylar position in temporomandibular joint. Measurements focused on antero-posterior and superior-inferior position of the condyle. The study the study was performed to investigate reproducibility of the method described before using Dahlberg formula. The method seems to be fair reproducible.

Key words: reproducibility, condyle, temporomandibular joint.

Introduction

Morphology of temporomandibular joint and relations between condyle and fossa have been investigated by many observers and different methods have been used according to imaging methods available at the time particular research was provided.

Early studies performed by Gillis [1] and Reisner [2] used cephalograms. Mandibular condyle is a double structure [3] and forms temporomandibular joint with glenoid fossa of temporal bone. The picture of temporomandibular joint on lateral cephalogram is not clear because petrosus part of temporal bone superimposes the joint structures. The use of angular radiograms created distortion of picture, which might influence the results.

R.M. Ricketts [4] used laminagraphy to picture the joint structures. The method was introduced by Pacini in 1922. Laminography enabled the visualisation of selected plane of the body to the exclusion of other planes. He measured condylar position in by three distances: (1) between most anterior point of the condyle and posterior surface of the tuberculum articulare, (2) highest point of the condyle and deepest point of the fossa and (3) most posterior point of the condyle and middle of the meatus. His results were that condyle is positioned not in the centre of the fossae but superiorly and anteriorly in the fossa. Laminography was also used by Broadbend [5] and Brader [6] in their growth studies.

Recent method of examining temporomandibular joint is cone beam computed tomography (CBCT) introduced in 1996 which is a three-dimensional scan of anatomical structures and any plane can be chosen to be examined or measured [7]. Rodrigues *et al.* [8] they used the shortest distances between anterior point of the condyle and articular eminence, highest point of the condyle to the deepest point in the fossa and most posterior point of the condyle and posterior wall of the fossa to describe antero-posterior position of the condyle.

The aim of the present pilot study was to evaluate reproducibility, repeatability of method of describing condylar position in the fossa, presented by Rodrigues *et al.* [8].

Material and method

The material of the present study was based on 10 CBCT scans of orthodontic patients taken for other reasons. Mean age was 19.1, maximum age was 36, minimum age was 13 years. 9 of the patients were female, 1 patient was male. The patients did not present any symptomatic temporomandibular disorders or pain.

The evaluation was performed by calibrated independent observer (PP) both right and left TMJ for each CBCT scan. All measurements were performed twice at separate sessions at least 2 weeks apart.

The CBCT scans were evaluated on Osirix software. Three measurements were provided for each condyle as described:

1. anterior joint space: expressed by the shortest distance between the most anterior point of the condyle and the posterior wall of the articular tubercle (Fig. 1 — a)

2. superior joint space: measured from the shortest distance between the most superior point of the condyle and the most superior point of the mandibular fossa (Fig. 1 — s)
3. posterior joint space: represented by the shortest distance between the most posterior point of the condyle and the posterior wall of the mandibular fossa (Fig. 1 — p)

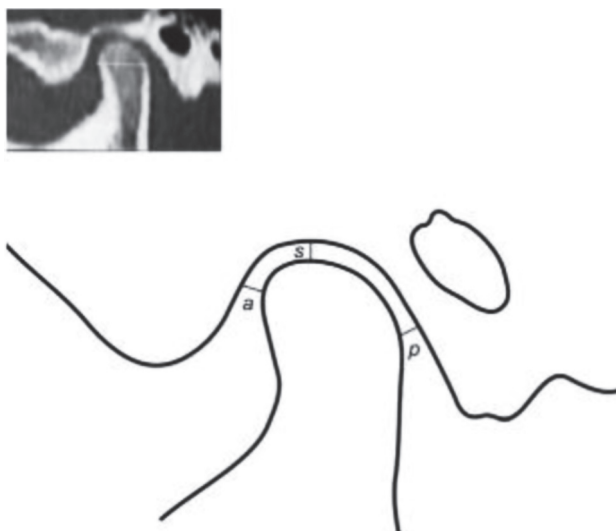


Fig. 1

The measurements were determined in the CBCT scan viewer using measuring tool. All distances were expressed in millimeters. The measurement slice was found as described by authors of the method.

Measurements 1 and 2 of anterior, superior and posterior space were compared to find the differences between left and right condyle position.

Statistical analysis

Reproducibility of the measuring method was evaluated by using Dahlberg formula [9].

Results

The results show that distances of AS, SS and PS on the right site ranged 1.5–4.2; 1.3–3.3; 0.6–7.2 and on the left site ranged 1.4–3.8; 0.9–5.0; 0.6–6.9 respectively (Table 1).

Table 1.

Patient	Assesment 1						Assesment 2					
	LEFT			RIGHT			LEFT			RIGHT		
	AS	SS	PS	AS	SS	PS	AS	SS	PS	AS	SS	PS
1.	1.9	2.5	3.8	1.8	1.7	2.1	2.2	2.4	3.1	2.0	1.9	2.1
2.	2.2	3.2	2.4	2.3	2.5	2.7	2.1	3.2	2.2	2.2	3.0	2.7
3.	1.4	1.2	1.6	2.1	1.3	0.6	1.3	1.3	1.3	1.4	1.3	0.4
4.	2.4	0.9	3.4	4.2	1.6	0.7	1.8	1.1	3.3	4.4	1.8	0.8
5.	2.3	1.8	2.2	2.3	1.4	2.9	2.3	2.4	2.3	2.2	1.7	2.8
6.	2.7	1.6	6.9	2.3	2.4	7.2	2.1	2.2	7.0	2.3	2.1	7.2
7.	2.1	5.0	3.9	1.5	2.7	2.8	1.9	5.2	3.9	1.6	3.0	3.5
8.	1.6	4.8	1.4	1.9	3.3	1.4	1.9	4.9	1.5	1.8	4.0	1.6
9.	2.2	3.2	0.6	1.6	1.4	3.4	2.4	2.4	0.9	2.2	2.8	2.4
10.	3.8	3.2	1.5	1.9	2.6	2.1	3.9	3.2	1.6	1.7	2.8	1.9

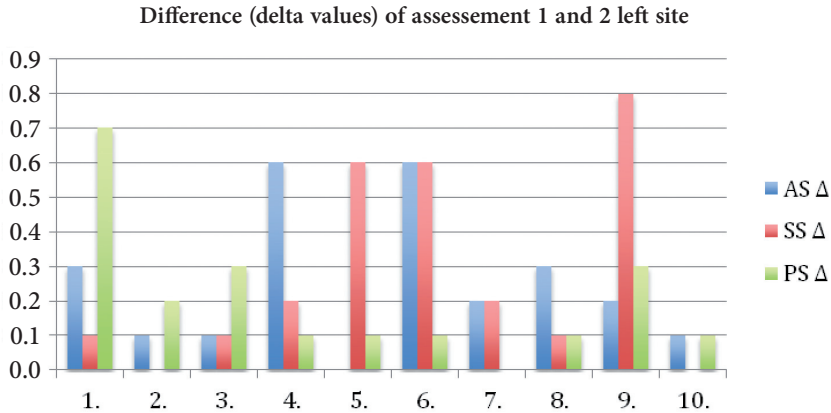
Measurements 1 and 2 results in both right and left condyle AS — anterior space, SS — superior space, PS — posterior space.

Table 2.

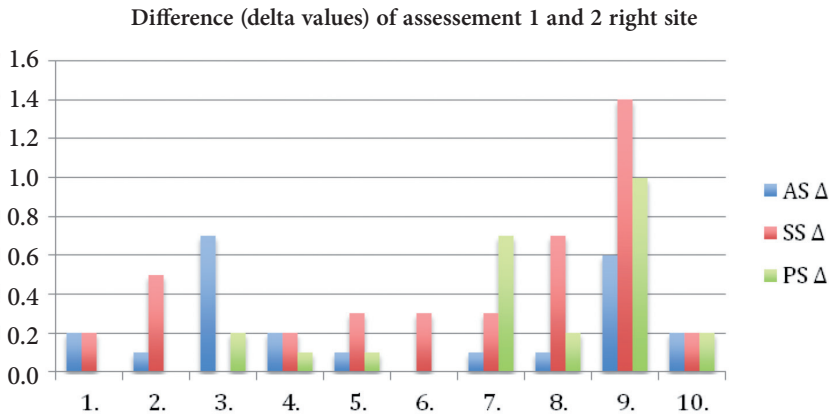
	LEFT			RIGHT		
	AS Δ	SS Δ	PS Δ	AS Δ	SS Δ	PS Δ
1.	0.3	0.1	0.7	0.2	0.2	0
2.	0.1	0	0.2	0.1	0.5	0
3.	0.1	0.1	0.3	0.7	0	0.2
4.	0.6	0.2	0.1	0.2	0.2	0.1
5.	0	0.6	0.1	0.1	0.3	0.1
6.	0.6	0.6	0.1	0	0.3	0
7.	0.2	0.2	0	0.1	0.3	0.7
8.	0.3	0.1	0.1	0.1	0.7	0.2
9.	0.2	0.8	0.3	0.6	1.4	1
10.	0.1	0	0.1	0.2	0.2	0.2
D=	0.2247	0.2711	0.1949	0.2247	0.3931	0.2855

Delta values of massesment 1 and 2. Dahlberg calculation results.

The results show that delta values of assessments 1 and 2 for anterior space (AS), superior space (SS) and posterior space (PS) were 0–0.7; 0–1.4; 0–1.0 respectively. Delta values for 60 measured distances was calculated. 0–0.5 was presented by 49 assessments, 0.6–1.0 by 10 assessments and >1.0 by 1 assessment (Table 2, Fig. 2 a, b).



a. Left site. Y axis in mm.



b. Right site.

Fig. 2.

Dahlberg formula was calculated (ref) for error of measurement finding. The results on the right site were as follows: AS = 0.2247, SS = 0.3931, PS = 0.2855 and on the left side: AS = 0.2247, SS = 0.2711, PS = 0.1949. The results were calculated with accuracy to 0.0001 (Table 2).

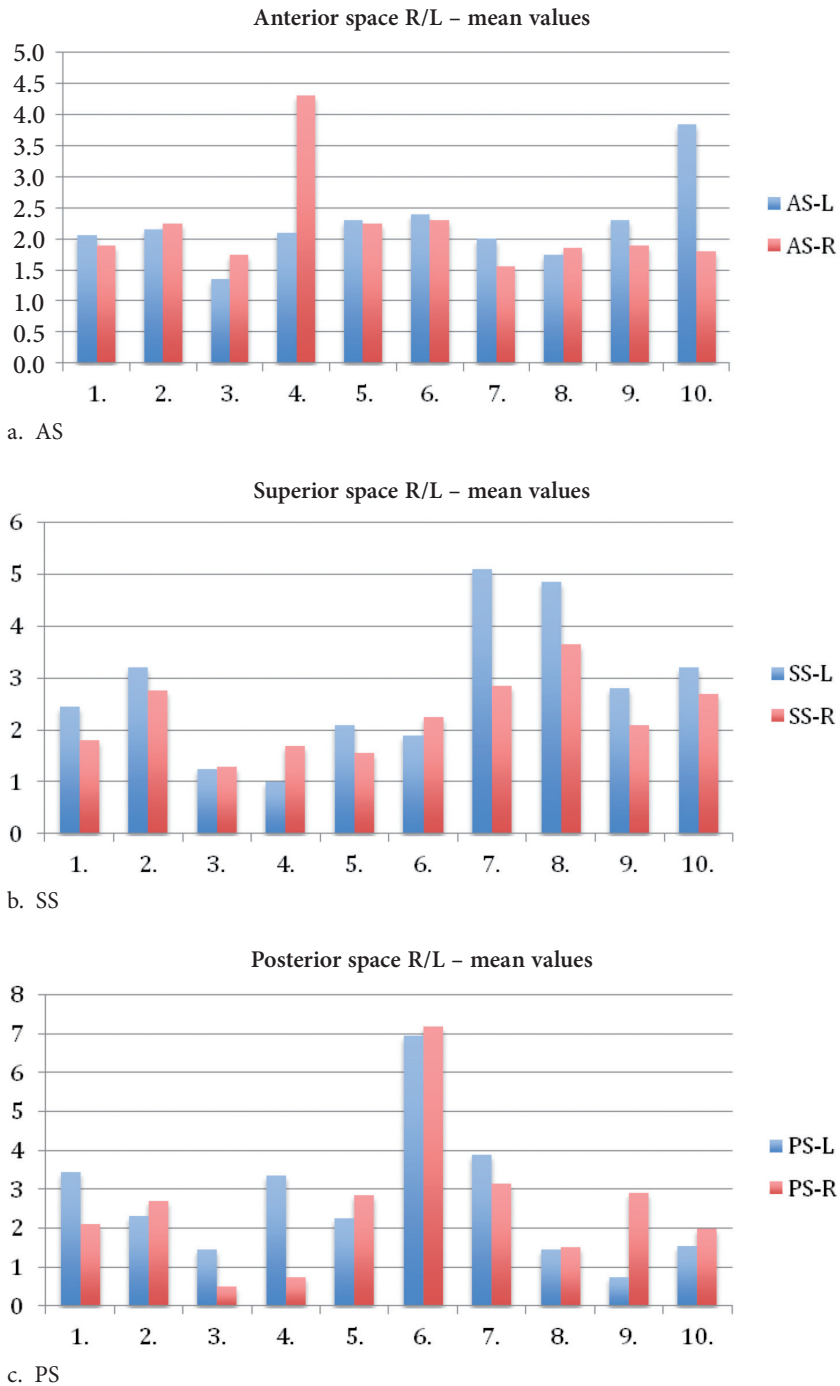


Fig. 3. Comparison of mean values of assesment 1 and 2 in right and left condyle.

The results show that the range of anterior space (AS) was 1.4 to 3.8 in assessment 1 and 1.3 to 3.9 in assessment 2; superior space (SS) was 0.9–5.0 and 1.1–5.2; posterior space (PS) was 0.6–7.2 and 0.9–7.2.

It was observed, that corresponding distances on the right and left site were different in all patients (Fig. 3 a, b, c).

Discussion

Alteration of occlusion as a result of orthodontic treatment may influence temporomandibular joint and alter condylar position on the fossa [10, 11].

The method used in the study was CBCT. It allows to investigate bony structures but TMJ consists also ligaments and disc which structures are not visible on CBCT scan. Shape of the disc may influence three-dimensional position of the condyle in the fossa. And in patients presenting asymptomatic TMJ, condyle may be positioned anteriorly, posteriorly or in the centre of the fossa. It may also be different on the right and left site of the same patient as described in results of present study.

Conclusions

The evaluation 1 and 2 showed minor differences and Dahlberg's formula results were low which might indicate that the method may be used as fair and reproducible.

Conflict of interest

None declared.

References

1. Gillis R.: Roentgen Ray Study of the Temporomandibular Articulation. *J Am Dent A.* 1935; 22: 1321–1328.
2. Reisner S.E.: Temporomandibular Reactions to Occlusal Anomalies. *J Am Dent A.* 1938–1953; 25: 1938.
3. Lipski M., Tomaszewska I.M., Lipska W., Lis G.J., Tomaszewski K.A.: The mandible and its foramen: anatomy, anthropology, embryology and resulting clinical implications. *Folia Morphol.* 2013; 72 (4): 285–292.
4. Ricketts R.M.: Variations of the temporomandibular joint as revealed by cephalometric laminagraphy. *Am J Orthod.* 1950; 36, 12: 877–898.
5. Broadbent B., Holly: A New X-ray Technique and Its Spplcation to Orthodontia, *Angle Orthodontist.* 1931; 1: 45–66.
6. Brader A.C.: The Application of the Principles of Cephalometric Laminagraphy to the Studies of the Frontal Planes of the Human Head. *Am J Orthod.* 1949; 35: 249–268.

7. *Berghan S., Tetradis S., Mallya S.M.*: Application of cone beam computed tomography for assesment of the temporomandibular joints. *Aus Dent J.* 2012; 57 (Suppl): 109–118.
8. *Rodrigues A.F., Fraga M.R., Vitral R.W.*: Computed tomography evaluation of the temporomandibular joint in Class I malocclusion patients: Condylar symmetry and condyle-fossa relationship. *Am J Orthod.* 2009; 136: 2: 199–206.
9. *Galvão M.C.S., Sato J.R., Coelho E.C.*: Dahlberg formula — a novel approach for its evaluation. *Dental Press J Orthod.* 2012 Jan–Feb; 17 (1): 115–124.
10. *Pullinger A.G., Solberg W.K., Hotiender L., Petersson A.*: Relationship of mandibular condylar position to dental occlusion factors in an asymptomatic population. *Am J Orthod Dentofac Orthop.* 1987; 91: 200–206.
11. *Weinberg L.A.*: Role of condylar position in TMJ dysfunction-pain syndrome. *J Prosthet Dent.* 1979; 41: 636–643.