




Arab Journal of Urology
(Official Journal of the Arab Association of Urology)

www.sciencedirect.com



LAPAROSCOPY/ROBOTICS
POINT OF TECHNIQUE

Laparoscopic implantation of an artificial urinary sphincter around the prostatic urethra



Piotr Chłosta^{a,b,e}, Omar Aboumarzouk^{a,c}, Jasper Bondad^{d,*},
Tomasz Szopiński^{a,b}, Ignacy Korzeliak^e, Andrzej Borówka^{d,e}

^a Department of Urology, Jagiellonian University, Cracow, Poland

^b Department of Urology Medical Centre of Postgraduate Education, Warsaw, Poland

^c Islamic University of Gaza, College of Medicine, Gaza, Palestine

^d Department of Urology, Southend University Hospital, Westcliff-on-Sea, UK

^e Department of Urology, Institute of Oncology, Kielce, Poland

Received 31 March 2015, Received in revised form 2 June 2015, Accepted 6 June 2015

Available online 29 June 2015

KEYWORDS

Artificial urinary sphincter;
Laparoscopy;
Urinary incontinence;
TURP

ABBREVIATIONS

AUS, artificial urinary sphincter;
UI, urinary incontinence

Abstract Objective: To report the first laparoscopic periprostatic implantation of an artificial urinary sphincter (AUS) after a transurethral resection of the prostate.

Background: The implantation of an AUS is a standard procedure for severe urinary incontinence. In men it is usually implanted through a perineal approach, with the cuff placed around the bulbous urethra, bladder neck, or even around the prostate.

Method: We report a laparoscopic periprostatic implantation of an AUS after a transurethral resection of a prostate in a 72-year-old-man with incontinence.

Results: The operative duration was 180 min and the blood loss was 150 mL. There were no complications. After activating the AUS the patient was totally continent.

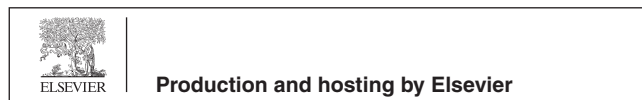
Conclusion: The laparoscopic periprostatic implantation of an AUS is a safe, effective and considerably less invasive procedure.

Crown Copyright © 2015 Production and hosting by Elsevier B.V. on behalf of Arab Association of Urology. This is an open access article under the CC BY-NC-ND license (<http://creativecommons.org/licenses/by-nc-nd/4.0/>).

* Corresponding author at: Southend University Hospital, Westcliff-on-Sea SS0 0RY, UK.

E-mail address: jbondad@nhs.net (J. Bondad).

Peer review under responsibility of Arab Association of Urology.



Introduction

Urinary incontinence (UI) in men has been reported to have a variable overall prevalence of 5–39% and is more common in elderly men [1,2]. It can reduce the quality of life considerably, and cause emotional and psychosocial

distress to the patient and their families. In the USA it was estimated that the financial costs of UI were > \$10 billion/year [3].

Although more common after radical prostatectomy, UI can also occur after TURP [4], but Wasson et al. [5] reported that they found no difference in the occurrence of UI between patients who were under 'watchful waiting' and those treated by TURP. Nevertheless, due to the increasing reduction in quality of life associated with UI, the surgical correction with an artificial urinary sphincter (AUS) has been advocated as the standard for UI caused by sphincter insufficiency [6]. This is supported by studies suggesting that the AUS can produce continence rates of 73–90% in men with UI after TURP, and has a durability rate of 80% over 5 years [4,6–8].

Traditionally, an AUS is inserted using an open procedure [4]. With the increasing use of laparoscopic surgery in urology, we report our laparoscopic technique for implanting an AUS.

Case report

A 72-year-old man presented to our department in 2012 with severe UI. He had undergone a TURP 3 years before presentation due to troublesome LUTS secondary to benign prostatic enlargement. His UI was urodynamically confirmed as stress UI. Due to the irreversible intrinsic sphincter deficiency caused by the TURP, and bothersome involuntary leakage of urine which reduced his quality of life considerably, he was considered for surgical intervention. After thorough counselling the patient was keen to undergo a laparoscopic approach, knowing the high risk of conversion, as the procedure had not been attempted before.

The patient was operated under general anaesthesia and placed in the Trendelenburg position. The trocar placements were similar to those for a laparoscopic radical prostatectomy. A 10-mm trocar was placed at the level of the umbilicus. Two 10-mm working trocars were inserted lateral to the rectus and just inferior to the umbilical trocar bilaterally. Two further 5-mm trocars were placed at the mid-clavicular line and medial to the anterior superior iliac spine bilaterally. The five-trocar configuration created a fan-shaped array (Fig. 1). Dissection was carried out from the superior part of the rectovesical pouch, then to the fascia posterior to the seminal vesicle, and down to Denonvilliers' fascia (Fig. 2). After this, the endopelvic fascia was dissected bilaterally to gain access to the retropubic space. As a result, a 'tunnel' between the prostate and rectum is created in which a cuff with a specific length can be introduced (Fig. 3). The 0° laparoscope was used for most of the procedure, but a 30° laparoscope was necessary for the dissection of the prostate, for the measuring tape and the cuff. The diameter of the AUS that was required was measured using the measuring tape introduced via the right-sided 10-mm working port. The

AUS (AMS 800) was subsequently implanted around the prostate (Fig. 4). A 5-cm lower midline incision was made to accommodate the insertion of the reservoir. All remaining parts of the AUS were placed and connected in a standard manner. The total duration of the procedure was 180 min and the estimated blood loss was 150 mL. There were no complications during or after the surgery. At 48 h after the procedure, the urinary catheter was removed and the patient was discharged from the hospital. The AUS was activated 1 month after surgery. After 1 year the patient maintained continence, with no accidental leakage reported and no malfunction problems with the device.

Discussion

The European Association of Urology (EAU) recommends that the treatment of choice for persistent moderate to severe UI is the implantation of an AUS [9]. The implantation of an AUS laparoscopically was previously described in women [10–12], but as far as we are aware, our report represents the first case of laparoscopic AUS implantation after a TURP.

Roupret et al. reported the largest case series of laparoscopic AUS implantation in 12 women, achieving complete continence or a significant improvement in 11 of the patients [10]. These results are comparable with that of the open approach, whereby long-term continence rates are maintained in >90% of patients [13–15].

Furthermore, Roupret et al. [10] found that there was also an additional benefit of reduced postoperative pain with the laparoscopic approach. However, the hospital stay was not reduced. They also reported five cases of urinary retention after catheter removal, but there were no long-term consequences when the catheter was left for longer.

The laparoscopic technique has a benefit over the open procedure in that it gives better imaging and a direct view of the anatomy, which allows for a more meticulous dissection of the planes when in experienced hands. However, in patients with previous pelvic surgery or radiotherapy, these planes might become very difficult to dissect. Therefore, as most men with UI have had such surgery or therapy, the learning curve for AUS surgery might be quite steep.

Nonetheless, unlike in the published series, the present patient was able to go home 2 days after surgery, with minimal complications, and the AUS was activated 1 month later [10–12]. We believe this allowed sufficient time for healing and the sling to take to its position around the prostate. After 1 year the patient remains continent with no complications.

We believe that the laparoscopic procedure can be offered to selected patients to treat UI, but only robust comparative trials can confirm the technique to be better than its open counterpart.

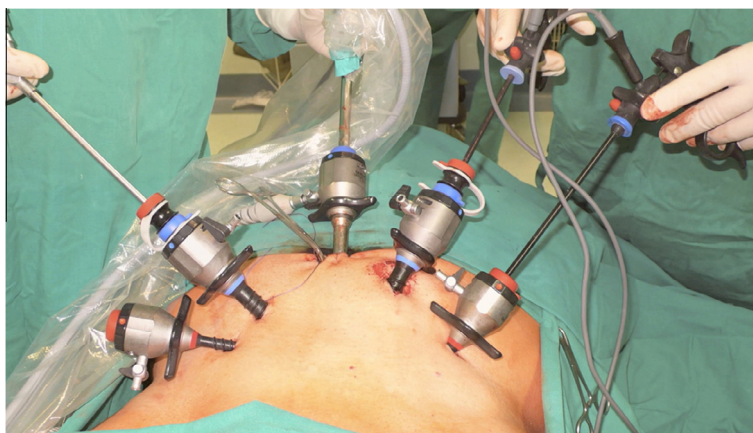

Figure 1 Port placement.

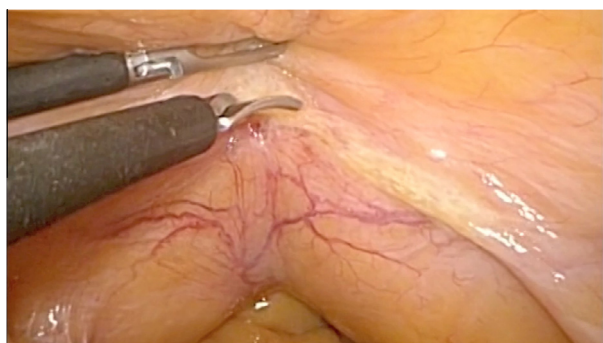

Figure 2 Start of the dissection of the rectovesical pouch.

In conclusion, we report the first successful case of a laparoscopically implanted AUS in a man with severe UI secondary to a TURP. With a follow-up of 1 year, the patient remained fully continent with no sphincter-related complications. Nonetheless, larger series in similar patients are required to fully establish the feasibility of the laparoscopic approach. However, in the era of

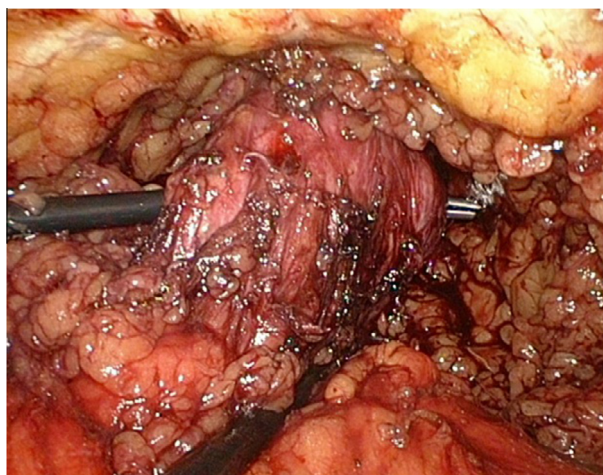


Figure 3 A view of the 'tunnel'.

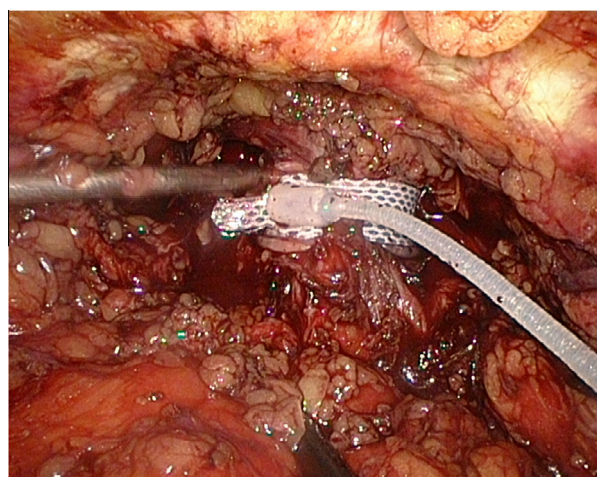


Figure 4 A laparoscopic view of the prostate with the AUS in place.

minimally invasive surgery we envisage that this will not take long and will soon replace the open technique as the standard.

Conflict of interest

None.

Source of funding

None.

Acknowledgements

We thank Dr. Isra Ashi for her support and advice. We obtained informed consent from the patient to write this case report, with full confidentiality of his identity provided.

Appendix A. Supplementary data

Supplementary data associated with this article can be found, in the online version, at <http://dx.doi.org/10.1016/j.aju.2015.06.001>.

References

- [1] Bortolotti A, Bernardini B, Colli E, Di Benedetto P, Giocoli Nacci G, Landoni M, et al. Prevalence and risk factors for urinary incontinence in Italy. *Eur Urol* 2000;**37**:30–5.
- [2] Bauer RM, Gozzi C, Hubner W, Nitti VW, Novara G, Peterson A, et al. Contemporary management of postprostatectomy incontinence. *Eur Urol* 2011;**59**:985–96.
- [3] Elliott DS, Barrett DM. Mayo Clinic long-term analysis of the functional durability of the AMS 800 artificial urinary sphincter: a review of 323 cases. *J Urol* 1998;**159**:1206–8.
- [4] Hussain M, Greenwell TJ, Venn SN, Mundy AR. The current role of the artificial urinary sphincter for the treatment of urinary incontinence. *J Urol* 2005;**174**:418–24.
- [5] Wasson JH, Reda DJ, Bruskewitz RC, Elinson J, Keller AM, Henderson WG. A comparison of transurethral surgery with watchful waiting for moderate symptoms of benign prostatic hyperplasia. The Veterans Affairs Cooperative Study Group on Transurethral Resection of the Prostate. *New England J Med* 1995;**332**:75–9.
- [6] Tuygun C, Imamoglu A, Gucuk A, Goktug G, Demirel F. Comparison of outcomes for adjustable bulbourethral male sling and artificial urinary sphincter after previous artificial urinary sphincter erosion. *Urology* 2009;**73**:1363–7.
- [7] Lai HH, Hsu EI, Teh BS, Butler EB, Boone TB. 13 years of experience with artificial urinary sphincter implantation at Baylor College of Medicine. *J Urol* 2007;**177**:1021–5.
- [8] Gundian JC, Barrett DM, Parulkar BG. Mayo Clinic experience with the AMS 800 artificial urinary sphincter for urinary incontinence after transurethral resection of prostate or open prostatectomy. *Urology* 1993;**41**:318–21.
- [9] Schroder A, Abrams P, Andersson K-E, et al. *Guidelines on urinary incontinence*. European Association of Urology; 2010.
- [10] Roupret M, Misrai V, Vaessen C, Cardot V, Cour F, Richard F, et al. Laparoscopic approach for artificial urinary sphincter implantation in women with intrinsic sphincter deficiency incontinence: a single-centre preliminary experience. *Eur Urol* 2010;**57**:499–504.
- [11] Hoda MR, Gauruder-Burmester A, Kummel C, Nitzke T, Popken G. Management of female stress urinary incontinence. Endoscopic extraperitoneal artificial urinary sphincter – early experience. *Der Urologe Ausg A* 2008;**47**:10048.
- [12] Ngninkeu BN, van Heugen G, di Gregorio M, Debie B, Evans A. Laparoscopic artificial urinary sphincter in women for type III incontinence: preliminary results. *Eur Urol* 2005;**47**:793–7.
- [13] Costa P, Mottet N, Rabut B, Thuret R, Ben Naoum K, Wagner L. The use of an artificial urinary sphincter in women with type III incontinence and a negative Marshall test. *J Urol* 2001;**165**:1172–6.
- [14] Petero Jr VG, Diokno AC. Comparison of the long-term outcomes between incontinent men and women treated with artificial urinary sphincter. *J Urol* 2006;**175**:605–9.
- [15] Thomas K, Venn SN, Mundy AR. Outcome of the artificial urinary sphincter in female patients. *J Urol* 2002;**167**:1720–2.