LETTER TO THE EDITOR

Ablation of arrhythmias in adult patients after Fontan operation

Adult patients after the Fontan operation are a heterogeneous group with respect to underlying etiology, method of correction, and clinical status. Despite the improvements in surgical techniques that reduce perioperative mortality, late deterioration in functional status can be observed with longer duration of follow-up. Data regarding the actual incidence of arrhythmias in adults after the Fontan procedure are scarce. In a group of 520 patients, Stephenson et al.[1] found supraventricular tachyarrhythmias in 9.4% and ventricular tachycardia in 3.5% of the patients at 8.6 years after the Fontan procedure. Idorn et al.[2] demonstrated the incidence of heart rhythm disorders in 32% of adult Danish patients undergoing the Fontan operation. Radiofrequency (RF) ablation is performed in drug-refractory disorders. However, access to pulmonary venous atrium in Fontan patients with lateral tunnel or external conduit is limited. There are a few data regarding RF ablation in adult patient after Fontan operation. In this letter, we would like to present our results in percutaneous catheter ablation of arrhythmias in adult patients with nonfenestrated Fontan procedures.

The first patient was a 27-year-old man with complex congenital heart disease including tricuspid atresia, D-transposition of the great arteries, and large ventricular septal defect. He had undergone total cavopulmonary connection at the age of 3 years. He presented multiple monomorphic ventricular extrasystole beats, and recurrent symptomatic nonsustained ventricular tachycardia, which created the subject for ablation. Ventricular arrhythmia recorded on ECG presented noncharacteristic QRS morphology with right-axis deviation and left bundle branch block. The patient presented also cyanosis, poliglobulia, thrombocytopenia, and recurrent exacerbation of heart insufficiency symptoms. The patient was treated ineffectively with antiarrhythmic drugs. The lead with 4-mm tip was advanced from femoral artery retrogradely through aorta to remnant right ventricle, ventricular septal defect to left ventricle and, subsequently, through systemic atrioventricular valve to the atrium (FIGURE 1A). One could find here dual electrical characteristic: on the left side irregular, chaotic, small "f" waves of atrial fibrillation, on the right side more regular "F" waves, typical for atypical atrial flutter. Six RF 60-second applications with a power of 25 Watts and temperature of 55°C was targeted at the sites of multifragmented "F" potentials with no result. The lead was then withdrawn to the ventricle, and using pace-mapping technique as well as evaluation of the earliest intracardiac extrasystole beats, potential ectopic site was localized in the subvalvular anatomical left ventricular region. During each of 4 RF applications targeted there, arrhythmia accelerated and subsequently terminated (FIGURE 1B). During the last application, there was no arrhythmia episode, despite sympaticomimetic drug administration and programmed ventricular pacing. The fluoroscopy time was 35 minutes. In a 2-year follow-up, there was no ventricular arrhythmia, which was proved by 24-hour ambulatory ECG. Atrial fibrillation/flutter remains chronic.

The second patient was a 37-year-old man with D-transposition of the great arteries, pulmonary valve stenosis, and with large ventricular septal defect after total cavopulmonary connection at the age of 16 years. He underwent RF ablation of recurrent resistant narrow QRS tachycardia 160/min with retrograde P wave and VA interval 150 ms. The electrophysiological study conducted with 2 leads revealed the existence of an accessory pathway, as the anatomic substrate for atrioventricular reentrant tachycardia (AVRT). It was located on the anatomical right side. At the site of shortest coupling interval with most preexcited atrial signal during AVRT, 1 60-s RF pulse was applied with a power of 10 Watts and a temperature of 66°C. Tachycardia was terminated during ablation, and was not initiated by typical techniques afterwards. The fluoroscopy time was 49 minutes. In a 3-year follow-up, the patient remains with no arrhythmia and conduction disturbance, in a good clinical state.

The third patient, a 23-year-old man with D-transposition of the great arteries, pulmonary valve stenosis, and with large ventricular septal defect after total cavopulmonary connection at the age of 16 years was admitted for RF

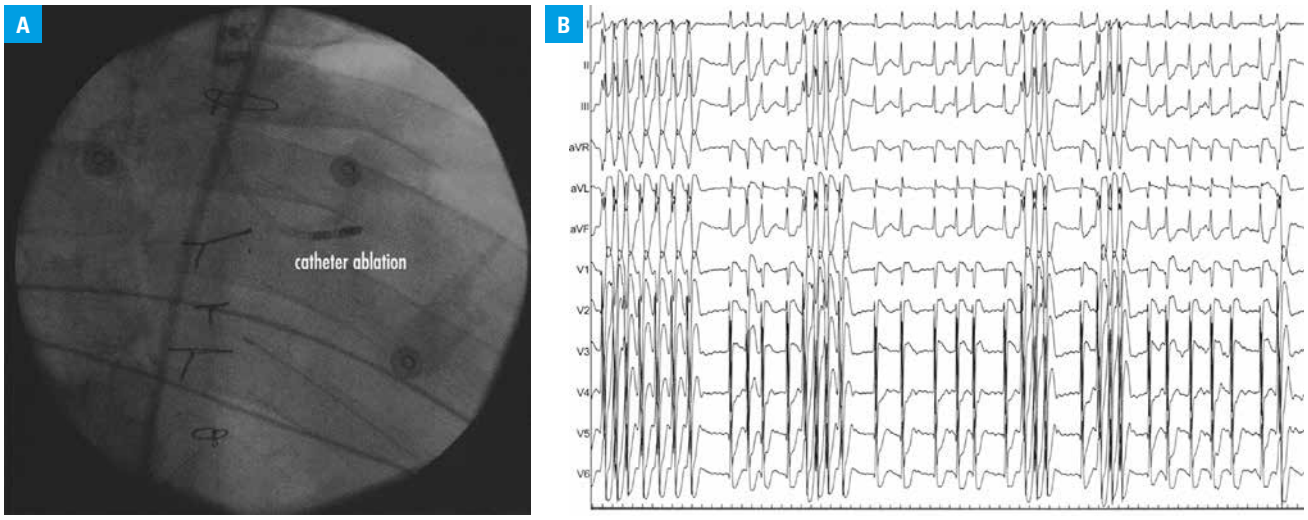

FIGURE Radiofrequency ablation in adult Fontan patient with symptomatic nonsustained ventricular tachycardia. **A** – X-ray, A-P projection. The lead was advanced retrogradely through aorta to remnant right ventricle, ventricular septal defect to left ventricle, and subsequently through systemic atrioventricular valve to the atrium. **B** – electrocardiogram during ablation. Ventricular arrhythmia accelerated and subsequently terminated.

ablation of chronic atypical, nonclassical atrial flutter. The lead was advanced retrogradely via aorta and functional left ventricle to big, common atrium. The multifragmented "F" waves were recorded right above atrioventricular valve. Using 3D CARTO mapping system, we identified pulmonary vein ostiums. The linear circumferential lines around ostiums were created with 26 RF applications with a power of 20 Watts and a temperature of 37°C. During right-sided application, atrial flutter was interrupted. The fluoroscopy time was 31 minutes, 31 seconds. In 30 days follow-up, no arrhythmia has been detected.

Arrhythmias may aggravate hemodynamics in the Fontan circulation and lead to heart failure over a short period of time.[1,2] Scarring after atrial incision, site of synthetic fabric sewing, and atrial remodeling predispose to intra-atrial reentrant tachycardia and atrial fibrillation/flatter. The ablation of atrial arrhythmias in patients with congenital heart diseases has been previously described.[3-5] One of the major problems in Fontan patients is limitation of the access to the pulmonary venous atrium, where most arrhythmia substrates are located. In our study, similarly to the previously published one, a retrograde arterial approach across the single aortic and atrioventricular valves were performed.[4,5] The duration of the procedure and success rate were comparable to the published experience with RF ablation of complex atrial tachycardias in patients with other congenital heart disease.[3-5] Retrograde access was used safely without any compromise to atrioventricular valve structure or function.

Data regarding the actual incidence of ventricular arrhythmias in adults after the Fontan procedure are scarce. Stephenson et al.[1] found ventricular tachycardia in 3.5% of the patients at 8.6 years after the Fontan procedure. Khairy et al.[6] found that the incidence of sudden death late after Fontan surgery was 0.15% per year, with most events of presumed arrhythmic origin with no identifiable predictor. However, implantation of cardioverter defibrillator in Fontan patients remains a great challenge for electrophysiologists. In our study, 1 patient had recurrent symptomatic nonsustained ventricular tachycardia. In presented case using pace-mapping technique as well as evaluation of earliest intracardiac extrasystole beats, the potential ectopic site was localized and terminated. In a single ventricle, the unique anatomy can be challenging for ablation procedure. In our study, we used computed tomography, which helped plan such intervention. As shown in the previous publication, the synopsis of morphological and structural information and a thorough evaluation of the electrical activities can result in superior guidance and successful ablation in such difficult cases.[7]

Summarizing, percutaneous RF ablation is an effective and save treatment method of both supraventricular and ventricular arrhythmias in adult Fontan patients. Preprocedural computed tomography is useful in planning this procedure.

Acknowledgments We thank Paweł Kołacz for figure preparation.

Author names and affiliations Lidia Tomkiewicz-Pająk, Jacek Lelakowski, Jacek Pająk, Grzegorz Kopeć, Piotr Podolec, Jacek Bednarek (L.T.P., J.L., G.K., P.P., J.B.: Institute of Cardiology, Jagiellonian University Medical College, John Paul II Hospital, Kraków; J.P.: Department of Pediatric Cardiology, Silesian Pediatric Medical Center, Katowice, Poland)

Correspondence to: Lidia Tomkiewicz-Pająk, MD, PhD, Instytut Kardiologii, Collegium Medicum, Uniwersytet Jagielloński, Krakowski Szpital Specjalistyczny im. Jana Pawła II, 31-202 Kraków, ul Prądnicka 80, phone: +48-12-614-22-87, fax: +48-12-423-43-76, e-mail: ltom@wp.pl

REFERENCES

1 Stephenson EA, Lu M, Berul CI, et al. Arrhythmias in a contemporary fontan cohort: prevalence and clinical associations in a multicenter cross-sectional study. J Am Coll Cardiol. 2010; 56: 890-896.

2 Idorn L, Juul K, Jensen AS, et al. Arrhythmia and exercise intolerance in Fontan patients: Current status and future burden. Int J Cardiol. 2013; 168: 1458-1465.

3 Rodrigo A. Nehgme, MD, Michael P. Carboni, et all. Transthoracic percutaneous access for electroanatomic mapping and catheter ablation of atrial tachycardia in Fontan patients with a lateral tunnel. Heart Rhythm. 2006; 3: 37-43.

4 Ambrose K, Shih-Lin C, Pi-Chang L, et all. Catheter Ablation of an Intra-Atrial Reentrant Tachycardia in a Young Adult Fontan Patient With Complex Palliated Congenital Heart Disease. Circ J. 2012 S; 76: 2494-2495.

5 Ueda A, Suman-Horduna I, Mantziari L et al. Contemporary outcomes in supraventricular tachycardia ablation in congenital heart diseases: a single center experience in 116 patients. Circ Arrhythm Electrophysiol. 2013; 6: 606-613.

6 Khairy P, Fernandes SM, Mayer JE Jr, et al. Long-term survival, modes of death, and predictors of mortality in patients with Fontan surgery. Circulation. 2008 1; 117: 85-92.

7 Reiter T, Ritter O, Nordbeck P, et all. MRI-guided ablation of wide complex tachycardia in a univentricular heart World J Cardiol. 2012; 26: 260-268.