



Received: 2014.04.28
Accepted: 2014.05.12
Published: 2014.10.27

Authors' Contribution:

- A** Study Design
- B** Data Collection
- C** Statistical Analysis
- D** Data Interpretation
- E** Manuscript Preparation
- F** Literature Search
- G** Funds Collection

Joubert Syndrome: Imaging Features and Illustration of a Case

Richa Arora^{ABEF}

Department of Radiology, Nizams Institute of Medical Sciences, Hyderabad, India

Author's address: Richa Arora, Department of Radiology, Nizams Institute of Medical Sciences, Hyderabad, India, e-mail: dr.richaarora@gmail.com

Background:

Joubert Syndrome (JS) is a rare autosomal recessive disorder characterised clinically by neonatal breathing dysregulation, developmental delay, intellectual disability, hypotonia, ataxia, nystagmus.

Case Report:

We present another case of this uncommon syndrome in a 12 years old patient presenting with classical complaints of developmental delay, intellectual impairment, weakness in both lower limbs, ataxia and abnormal facies and diagnosed on Computed Tomography.

Conclusions:

Joubert Syndrome should be ruled out in all patients presenting with hypotonia, ataxia, nystagmus, breathing abnormalities and developmental delay. Its neuroimaging hallmarks include molar tooth sign and batwing shaped fourth ventricle. As JS is associated with multiorgan involvement, these patients should enter a diagnostic protocol to assess systemic abnormalities. Extreme caution should be taken while administering drugs in these patients as they are prone to respiratory depression.

MeSH Keywords:

Congenital Abnormalities • Multidetector Computed Tomography • Nervous System Malformations

PDF file:

<http://www.polradiol.com/abstract/index/idArt/890941>

Background

Joubert Syndrome (JS) is a rare autosomal recessive disorder characterized clinically by neonatal breathing dysregulation, developmental delay, intellectual disability, hypotonia, ataxia, nystagmus and facial dysmorphism. Approximately 212 cases have been reported so far [1].

We present a case of this uncommon syndrome in a 12-year-old boy diagnosed with computed tomography and discuss the spectrum of neuroimaging findings.

Case Report

A twelve-year-old male child presented to neurology outpatient department with complaints of developmental delay, intellectual impairment, weakness in both lower limbs, ataxia and abnormal facies (Figure 1) (Previously, the patient had consulted a local practitioner in his village, but no imaging was performed. India is a developing country, where proper medical facilities are still not accessible at many places and people are ignorant. Therefore, the patient remained undiagnosed till that age and presented to our

institute when the symptoms became more obvious). He was referred for non-contrast computed tomography of the brain by a neurologist to rule out organic brain anomalies. Non-contrast computed tomography of the head showed hypoplastic vermis with a dilated batwing-shaped fourth ventricle (Figures 2 and 3A). The isthmus was hypoplastic with deep interpeduncular fossa, thickening and elongation of the superior cerebellar peduncle giving "molar tooth" sign (Figure 3A, 3B). Superior cerebellar peduncles were thickened and oriented horizontally (Figure 4). The size of the posterior fossa and corpus callosum was normal (Figure 2). There was no ventriculomegaly or any evidence of neuronal migration anomalies. Hence, the diagnosis of Joubert syndrome was made based on pathognomonic neuroimaging and clinical features. No genetic tests were performed as in about a half of the cases of Joubert syndrome the genetic cause is unknown and in the remaining half there are mutations of about 10 genes. Other investigations, namely ultrasound of the abdomen, kidney and liver function tests, urine analysis, ocular investigations (visual acuity, electroretinogram) were normal. The patient was kept on supportive treatment which consisted of neuropsychological support and rehabilitation.

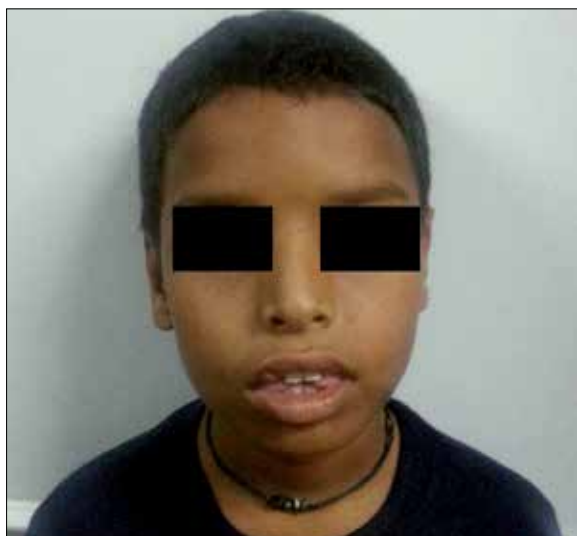

Figure 1. Photograph of the patient showing a broadened bridge of the nose and an open mouth.

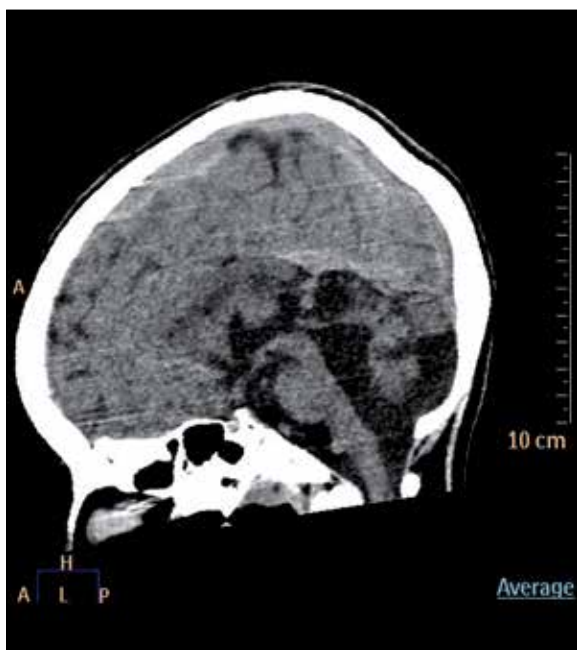

Figure 2. Median sagittal reformatted section of computed tomography of the brain showing hypoplastic vermis with dilated fourth ventricle and deep interpeduncular fossa.

Discussion

Joubert Syndrome (JS) is a rare congenital syndrome associated with varying degrees of vermian hypoplasia and failure of fibre decussation in the superior cerebellar peduncles and pyramidal tracts which causes thickened superior cerebellar peduncles to have a more horizontal course between the brainstem and the cerebellum [2]. The incidence ranges between 1/80000 to 1/100000 live births [3].

JS was originally described by Marie Joubert in 1968. Later, Joubert Syndrome-related disorders (JSRD) were defined based on associated multi-organ involvement (retinal dystrophy, nephronophthisis, hepatic fibrosis and polydactyly).

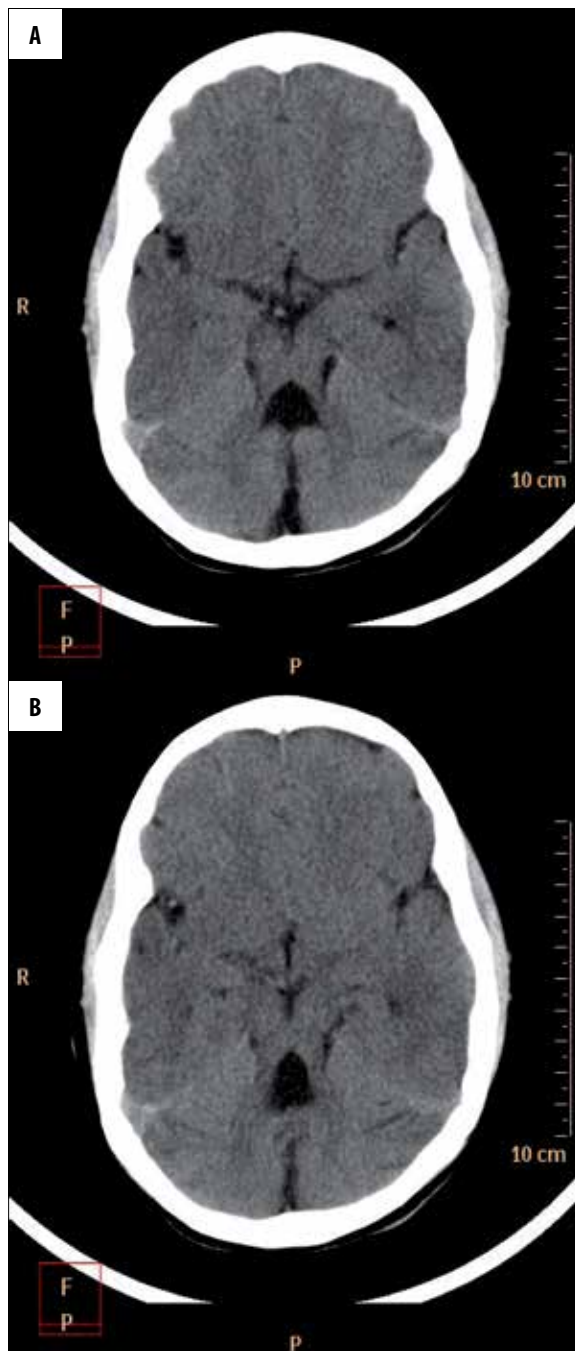


Figure 3. Axial sections of computed tomography of the head showing a dilated batwing-shaped fourth ventricle, hypoplastic vermis (A), and thickened and elongated superior cerebellar peduncles (A, B) with deep interpeduncular fossa (B) giving a "molar tooth sign" (A, B).

JSRD has six phenotypic subtypes: Pure JS, JS with ocular defect, JS with renal defect, JS with oculorenal defects, JS with hepatic defects and JS with orofaciocigital defects. Pure JS is classified into two types depending on the presence or absence of retinal dystrophy. Type 2 is associated with retinal dysplasia and therefore has a poor prognosis. Recent studies have shown mutations in 10 genes in JS [3]. There is no evidence in the literature that Joubert syndrome may be linked with any kind of prenatal exposure.

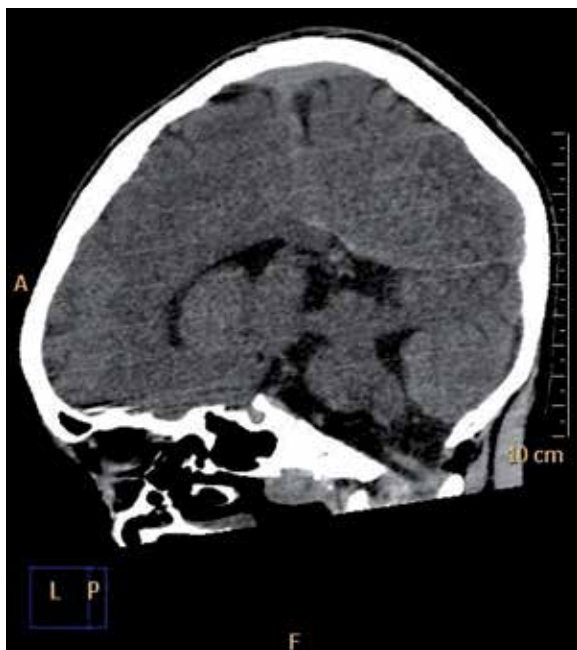

Figure 4. Sagittal reformatted section of computed tomography of the brain showing thickened superior cerebellar peduncles oriented horizontally.

The clinical features include episodic hyperpnoea and apnoea in the neonatal period, ocular abnormalities (oculomotor apraxia and ocular coloboma), hypotonia, truncal ataxia, developmental delay, intellectual impairment and abnormal facies [4,5].

The diagnosis is based on characteristic imaging features on computed tomography (CT) or magnetic resonance imaging (MRI), which include molar tooth sign and varying degrees of vermian hypoplasia causing batwing appearance of the fourth ventricle. The molar tooth sign is produced

by a thinned ponto-mesencephalic junction and deep interpeduncular fossa due to dysgenesis of the isthmus (a part of the brainstem between pons and inferior colliculus) and thickening of superior cerebellar peduncles which are oriented horizontally [1,2]. Other associated brain anomalies include cortical dysplasias, grey matter heterotopias, ventriculomegaly and corpus callosum agenesis [1,6].

Nevertheless, in diagnosed cases of JS, further investigations should be done to exclude any systemic abnormalities. The protocol should include ocular investigations (visual acuity, ocular motility, electroretinography), kidney and liver function tests, urine analysis and abdominal ultrasound to identify multicystic dysplastic kidneys and congenital hepatic fibrosis) [3].

Management is supportive and requires a multidisciplinary approach. In particular, special care should be taken in managing breathing abnormalities in infants. Medication like opioids should be used with caution as these patients are sensitive to respiratory depressants, and anaesthetic agents like nitrous oxide should be avoided. Cognitive and behavioral abnormalities should be dealt with adequate neuropsychological support and rehabilitation. Prognosis depends on the extent and severity of breathing dysregulation and systemic abnormalities [1–3].

Conclusions

Joubert Syndrome should be ruled out in all patients presenting with hypotonia, ataxia, nystagmus, breathing abnormalities and developmental delay. Its neuroimaging hallmarks include molar tooth sign and batwing-shaped fourth ventricle. As JS is associated with multi-organ involvement, these patients should undergo a diagnostic protocol to assess systemic abnormalities. Extreme caution should be taken while administering drugs in these patients as they are prone to respiratory depression.

References:

1. Singh P, Goraya JS, Sagar K et al: A report of Joubert Syndrome in an infant, with literature review. *J Pediatr Neurosci*, 2011; 6(1): 44–47
2. Sarikaya B, Akpınar E, Karlı-Oğuz K et al: Joubert Syndrome: Magnetic resonance imaging findings. *Neuroanatomy*, 2004; 3: 30–31
3. Brancati F, Dallapiccola B, Valente EM: Joubert Syndrome and related disorders. *Orphanet J Rare Dis*, 2010; 5: 20
4. Kumar J, Kumar A, Saha S: The molar tooth sign of Joubert Syndrome. *Images in Neurology. Arch Neurol*, 2007; 64: 602
5. Poretti A, Huisman TAGM, Scheer I et al: Joubert Syndrome and related disorders: Spectrum of Neuroimaging findings in 75 patients. *Am J Neuroradiol*, 2011; 32: 1459–63
6. Zamponi N, Rossi B, Messori A et al: Joubert Syndrome with associated corpus callosum agenesis. *Eur J Paediatr Neurol*, 2002; 6: 63–66