

# Morphology, topography and clinical significance of the jugular foramen

JANUSZ SKRZAT, IZABELA MRÓZ, ALEXANDRU SPULBER, JERZY WALOCHA

Department of Anatomy, Jagiellonian University Medical College  
ul. Kopernika 12, 31-034 Kraków, Poland

**Corresponding author:** Dr. hab. Janusz Skrzat, Department of Anatomy, Jagiellonian University Medical College  
ul. Kopernika 12, 31-034 Kraków, Poland; Phone/Fax: +48 12 422 95 11; E-mail: jskrzat@poczta.onet.pl

**Abstract:** The paper describes morphological variants of the jugular foramen of the human skull and discusses the reasons for its frequent asymmetry. Bilateral disproportions between the anteroposterior and mediolateral diameters of the jugular foramina were analyzed. We established that the jugular foramen is extremely narrow when its anteroposterior diameter is less than 5.0 mm. When the mediolateral diameter exceeds 20.0 mm, then the foramen exhibits extreme widening.

**Key words:** jugular foramen, cranial foramina, cranial base.

## Introduction

The jugular foramen is a paired aperture located in the cranial base laterally and anteriorly relative to the foramen magnum. Its anterolateral borders are formed by the petrous part of the temporal bone and its posteromedial border by the occipital bone.

The jugular foramen enables a passage for numerous neurovascular structures of clinical importance. The anteromedial compartment (nervous part) contains the glossopharyngeal nerve and the inferior petrosal sinus. The posterolateral compartment (vascular part) contains the jugular bulb, the vagus nerve and the spinal portion of the accessory nerve [1–4].

The jugular foramen has an irregular shape (curvilinear outline) and frequently reveals unequal size (bilateral disproportion between width and length of the endo- and exocranial openings). Its morphological appearance depends on the side of the cranium,

sex of individual, a local subset of the human population, and additionally can be complicated by division into separate compartments [4–6]. The jugular foramen may be divided completely or incompletely into two, three, or even four compartments by the fibrous or osseous bridges that connect the jugular spine of the petrous part of the temporal bone with the jugular process of the occipital bone [1, 3, 7, 8]. In the case of tripartition the jugular foramen contains two venous and one neural compartments. The venous compartments consist of a larger posterolateral (sigmoid) part which receives blood from the sigmoid sinus, and a smaller anteromedial (petrosal) part which receives blood from the inferior petrosal sinus. The neural (intrajugular) part is located between the sigmoid and petrosal parts of the jugular foramen, at the site of the intrajugular processes of the temporal and occipital bones, which can be joined by a fibrous or osseous bridge [9].

The jugular foramen was a subject of many morphological studies because of its clinical significance. It can be affected by congenital, vascular, and tumoral lesions which manifest in various clinical syndromes. The most common tumors that can be found in the region of jugular foramen are: glomus jugulare tumor, paragangliomas, neuroma, meningioma, metastatic carcinoma, chondroma, nasopharynx carcinoma, carcinoma of the tympanic cavity, and infiltrating inflammatory processes [10].

The symptoms of these lesions are the following: loss of hearing, tinnitus, otorrhea, pain, and paralysis of the facial, glossopharyngeal, vagus, and accessory nerves. Dysfunction of these nerves is called syndrome of the jugular fossa (Vernet's syndrome) which is characterized by: loss of taste sensation in the posterior third of the tongue, paralysis of the vocal cords and soft palate, and weakness of the trapezius and sternocleidomastoid muscles. If tumors of the jugular foramen region extend medially to the hypoglossal canal and cause hypoglossal nerve paralysis, the clinical presentation is known as Collet-Sicard syndrome [2, 11–13]. Due to the clinical importance of the jugular foramen, this cranial region was extensively explored in different human populations. Morphological studies of the jugular foramen were focused on measuring its diameters, analysing the bilateral asymmetry of its size, and establishing relationships to other structures of the cranial base.

Our study was aimed at searching for atypical jugular foramina whose diameters are much lesser or greater than the values presented in the literature and finding the jugular foramina which reveal considerable disproportion in size: extreme bilateral narrowing, extreme bilateral widening, and extreme unilateral narrowing versus unilateral widening. We analyzed the frequency and morphological appearance of the jugular foramen partitions.

## Material and method

Morphometric analysis of the jugular foramina was performed on the dry human skulls of 54 adult individuals of both sexes. Examined skulls were well preserved, non-deformed and their cranial base revealed normal anatomy. In all case the jugular foramina

had non-destroyed exocranial edges and were clearly visible. The skulls are housed in the Museum of the Department of Anatomy of the Medical College of the Jagiellonian University.

To evaluate the size of the jugular foramen we measured anteroposterior and mediolateral diameters determined by the most remote points located along the edge of the exocranial opening of the jugular foramen (Fig. 1).

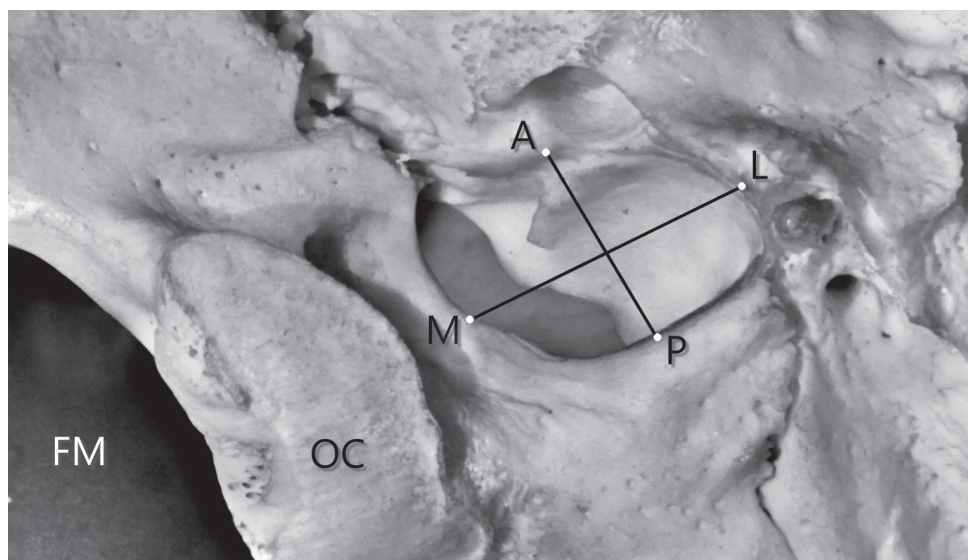


Fig. 1. Measurements of the jugular foramen: A-P — anteroposterior diameter, M-L — mediolateral diameter. FM — foramen magnum, OC — occipital condyle

Minimum and maximum diameters of the jugular foramen were measured on the external surface of the cranial base using digital caliper. To find out which jugular foramina can be regarded as abnormal in size we took into consideration data on average diameters of this foramen published in literature and normal range of variation of this feature.

We defined extreme narrowing of the jugular foramen when at least one of the diameters measured less than 5.0 mm. Furthermore, extreme widening of the jugular foramen was accepted when one or both diameters exceeded 20.0 mm.

## Results

Topography and morphological appearance of distinct jugular foramina is presented in Fig. 2. In this case, a huge asymmetry in the shape and size of the jugular foramina was observed. The left jugular foramen is narrow and elongated (elliptical shape), whereas the right foramen is oval and has both diameters (minimal and maximal) nearly equal.

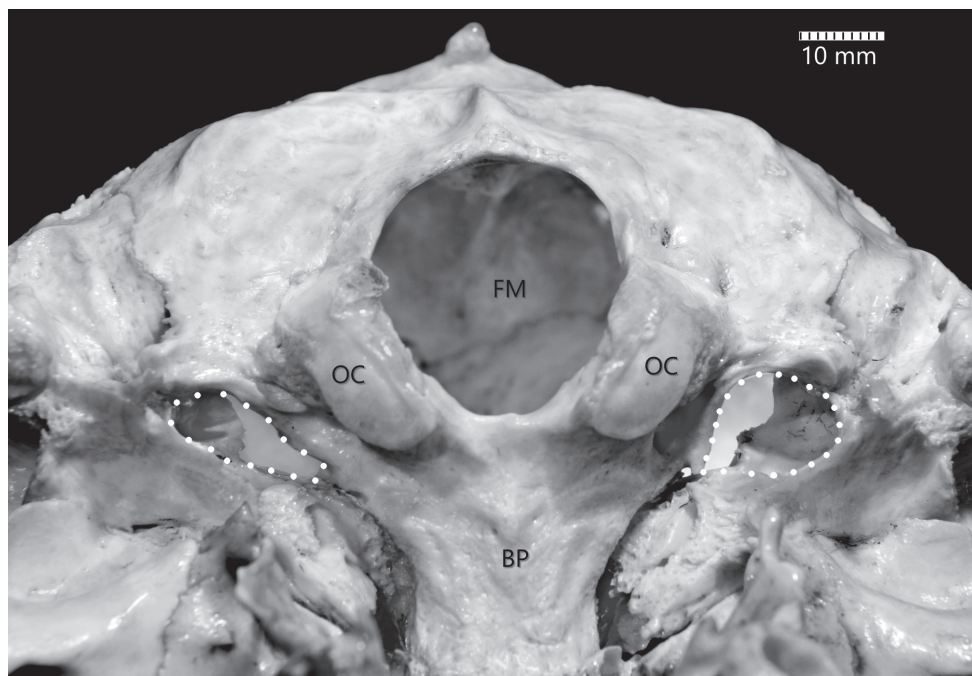


Fig. 2. Asymmetrical jugular foramina. Dotted line demarcates their borders as seen on the external surface of the cranial base. FM — foramen magnum, OC — occipital condyle, BP — basilar part of the occipital bone, PT — petrous part of the temporal bone.

Potential osseous partition of the jugular foramen is shown in Fig. 3. In our material we rarely observed division of the jugular foramen by osseous bridges. We found only one case of unilateral (left side) division of the jugular foramen into three compartments.

Overall variation of the jugular foramen diameters was established as 3.6–16.6 mm for the anteroposterior diameter and 7.8–23.1 mm for mediolateral diameter.

The minimal mediolateral diameter of the jugular foramen measured on the left side was 10.1 mm and 7.8 mm on the right side. The maximal mediolateral diameter of the jugular foramen measured on the left side was 22.0 mm and 23.1 mm on the right side.

In turn, the minimal anteroposterior diameter of the jugular foramen measured on the left side was 4.1 mm and 3.6 mm on the right side. The maximal anteroposterior diameter on the left side was 11.2 mm and 16.6 mm on the right side.

We did not find any skull which had both right and left jugular foramina extremely narrow or a case when one of the foramina was extremely narrow and the other extremely wide. Extreme bilateral widening of the jugular foramen was observed only in 1 skull. Extreme unilateral narrowing of the jugular foramen was observed in 8 skulls (3 on the right side and 5 on the left side). Extreme unilateral widening of the jugular foramen was observed in 6 skulls (4 on the right side and 2 on the left side).

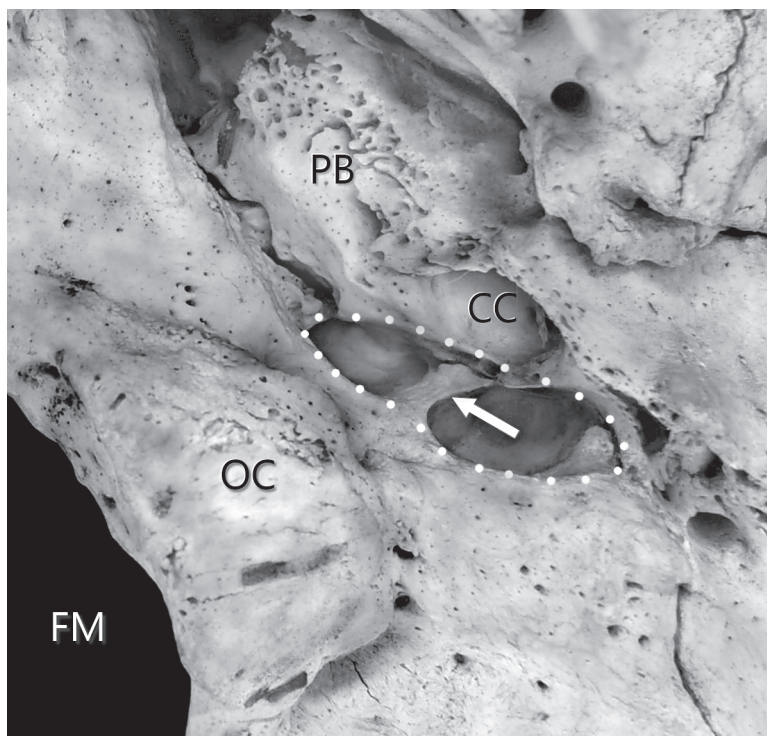


Fig. 3. Close up view of the jugular foramen partition (osseous bridge) indicated by the arrow. Dotted line demarcates borders of the jugular foramen. FM — foramen magnum, OC — occipital condyle, PB — petrous bone, CC — carotid canal.

According to performed measurements and morphometric data on the size of the jugular foramina presented in literature, we regarded the jugular foramen to be extremely narrow when anteroposterior diameter was lesser than 5.0 mm. On the contrary, when the mediolateral diameter exceeded 20.0 mm then such a foramen was regarded as extremely wide.

## Discussion

The size and shape of the jugular foramen is related to the diameter of the internal jugular vein and the presence or absence of a prominent jugular bulb. The difference in size of the two internal jugular veins is already visible in the human embryo at the 23 mm stage of development and probably results from differences in the pattern of development of the right and left brachiocephalic veins [4, 5, 14].

As mentioned in the introduction section, the jugular foramen has complex anatomy. Therefore, any quantitative analysis of its size is also difficult and may depend



on the measuring method and applied material (dry skulls, radiographs or CT-scans) [3, 15–17]. Some authors presented measured data of the jugular foramen without specifying the side or measured only the exocranial opening and ignored the fact that measurements performed at the internal surface of the basicranium can be different. Lang and Schreiber established that diameters of the jugular foramen measured on the outer surface of the skull are  $9 \times 17.0$  mm and at the internal skull base are  $7 \times 14.5$  mm [18].

Evaluation of the size of the jugular foramina based on measuring their diameters or estimating surface area indicates frequent asymmetry. Data presented by different authors states unequivocally that jugular foramina on the right side of the skull are larger than on the left side. Also, right jugular foramina are usually deeper, as shown by Singh *et al.* [4].

Although the size of the jugular foramina varies in different human populations, this rule was observed both in European and non-European populations (e.g. Brazilian, Nigerian, Turkish, Indian) [6, 8, 19–22]. See data in Table 1 and Table 2.

Ayeni *et al.* showed that jugular foramina on the right side were wider than on the left side in 70% of the cases [23]. According to Ramos-Junior *et al.* this difference increases to 84% [24]. Shruti *et al.* showed that in 71.2% of cases the right jugular foramina were larger than the left ones and in 20.8% of cases the left foramina were larger than the right. In 8% of cases they were equal in size on both sides [5]. According to Singh *et al.* the jugular foramen was larger in 88.3% of skulls on the right side as compared to 3.3% of skulls on the left side. In the remaining 8.3% of skulls, it was equal on both sides [4]. Kumar *et al.* showed that the jugular foramen is larger on the right in 64.7% of cases, larger on the left in 19.1% of cases, whereas in 16.1% of cases left and right sides are equal in size [2].

**Table 1.** Range of variation of the jugular foramen diameters: mediolateral (M–L) and anteroposterior (A–P). Measurements in millimeters.

Author	Right side				Left side			
	Min. length (M–L)	Min. width (A–P)	Max. length (M–L)	Max. width (A–P)	Min. length (M–L)	Min. width (A–P)	Max. length (M–L)	Max. width (A–P)
Rudinger (1875) [25]	6.00	4.00	18.00	13.00	5.00	2.00	16.00	16.00
Aubaniac (1951) [26]	10.00	5.00	26.00	15.00	11.00	4.00	21.00	14.00
Di Chiro <i>et al.</i> (1964) [17]	8.00	5.00	25.00	15.00	6.00	4.00	21.00	16.00
Idowu (2004) [20]	11.60	6.80	17.00	14.40	9.20	7.40	20.20	12.80
Patel and Mehta (2014) [27]	4.50	3.00	16.50	12.50	5.00	3.00	16.00	12.50
Singh <i>et al.</i> (2015) [4]	12.00	7.00	21.00	15.00	10.00	6.00	18.00	11.00
Shruthi <i>et al.</i> (2015) [5]	20.23	5.32	29.16	9.88	16.54	4.50	26.95	9.67
Our study	7.80	3.60	23.10	16.60	10.10	4.10	22.00	11.20

**Table 2.** Comparison of average diameters of the jugular foramen mediolateral (M–L) and anteroposterior (A–P). Measurements in millimeters.

Author	Right side		Left side	
	Average M–L diameter	Average A–P diameter	Average M–L diameter	Average A–P diameter
Lindblom (1936) [28]	12.90	8.60	11.60	7.60
Aubaniac (1951) [26]	16.80	10.20	16.10	9.00
Di Chiro <i>et al.</i> (1964) [17]	16.60	10.70	16.20	7.70
Idowu (2004) [20]	13.90	10.22	14.11	9.57
Pereira <i>et al.</i> (2010) [19]	15.82	9.21	15.86	8.65
Singla <i>et al.</i> (2012) [29]	15.65	9.32	14.85	7.34
Osunwoke <i>et al.</i> (2012) [30]	15.79	9.34	13.39	7.54
Vijisha <i>et al.</i> (2013) [31]	17.30	12.13	15.30	9.27
Patel & Mehta (2014) [27]	12.17	7.90	11.00	6.20
Kumar <i>et al.</i> (2015) [2]	13.60	10.60	13.90	9.20
Shruthi <i>et al.</i> (2015) [5]	24.48	7.51	21.24	7.16
Singh <i>et al.</i> (2015) [4]	17.65	11.41	13.70	8.21

In all above mentioned studies the jugular foramen was larger on the right side of the skull than on the left side. Wysocki *et al.* explains that there is a relationship between larger asymmetry and a larger skull capacity in left-side dominant skulls, and in right-side domination the degree of asymmetry is less meaningful for the venous outflow. A reason for this finding may be the different anatomy of the jugular and brachiocephalic veins: on the right side the distance for the venous blood outflow from the jugular vein to the superior vena cava and the heart is shorter than that on the left [32]. In turn, Adams *et al.* noticed that there was an association between jugular foramen dominance and hand preference (a larger right jugular foramen occurs more often in right-handed patients) [16].

According to Caldemeyer *et al.*, asymmetrically enlarged jugular foramina may be an anatomical variant and can be related to large sigmoid and transverse sinuses. Also, asymmetric jugular bulbs or a high jugular bulb may be reasons for enlargement of the jugular foramen. Another reason for the enlargement of the jugular foramen may be tumors such as: paraganglioma, metastasis, schwannoma, meningioma, plasmocytoma, lymphoma, histiocytosis, and chondrosarcoma [33].

Another important anatomical feature of the jugular foramina is their division by osseous or fibrous bridges. Dodo analyzed Asiatic and North American skulls and noticed that bridges occurred more frequently on the right side than on the left side [34]. Kumar *et al.* observed partial septation of the jugular foramina very often both on the right (83.17%) and left side (91.2%) [2]. In turn, occurrence of partial septation of the

jugular foramina reported by Singh *et al.* was much lower (48.3% on the right side and 35.0% on the left side). He also found that bilateral complete septation occurred only in 3.3% of the examined skulls, whereas unilateral complete septation was present in 8.3% skulls on the right side and in 5.0 % of skulls on left side [4]. Occurrence of complete bridges may cause septation of the jugular foramen into two or three compartments. Vljaković *et al.* found complete bony bridges of the jugular foramen in 24% of examined skulls (of these, two compartments existed in 56% and three compartments in 44%) [35].

Sturrock noticed that occurrence of complete bridges when analyzed on dry skulls can be lower when compared to living individuals in which apparently incomplete bony septation may be completed by cartilage. His results showed that 10% of the examined skulls had incomplete septation of the jugular foramina [21].

To sum up, there are discrepancies in literature data on the jugular foramen morphology and other cranial foramina (eg. the oval foramen, round or lacerum), therefore further and more extensive studies are necessary, particularly focused on rare anatomical variants and their relationship with other cranial traits [36–40].

## Conclusions

Knowledge of the size and shape of the jugular foramen seems to be important for anatomical studies aimed at assessing normal and pathological variation of the basicranial foramina and their relationship with the venous system of the skull. Results of morphometric analysis of the jugular foramen can be helpful for neurosurgeons and radiologists in their clinical practice because they can use them to predict the chances of preserving intact nervous and vascular structures during surgical interventions.

## Conflicts of interest

None declared.

## References

1. Daniels D.L., Williams A.L., Haughton V.M.: Jugular foramen: anatomic and computed tomographic study. *AJR*. 1984; 142: 153–158.
2. Kumar A., Akhtar J., Kumar A.: Variations in jugular foramen of human skull. *Asian Journal of Medical Sciences*. 2015; 6 (2): 95–98.
3. Lo W.W.M., Solti-Bohman L.G.: High-resolution CT of the jugular foramen: anatomy and vascular variants and anomalies. *Radiology*. 1984; 150: 743–747.
4. Singh S., Suman P., Panigrahi A.K.: Morphometric variation of jugular foramen in dry adult skull of South Indian population and its clinical implications. *IJHSR* 2015; 5 (9): 215–219.
5. Shruthi B.N., Havaladar P.P., Saheb S.H., Henjarappa K.S.: Morphometric study of jugular foramen. *Int J Intg Med Sci*. 2015; 2 (10): 164–166.
6. Navsa N., Kramer B.: A quantitative assessment of the jugular foramen. *Ann Anat*. 1998; 180 (3): 269–273.



7. Athavale S.A.: Morphology and compartmentation of the jugular foramen in adult Indian skulls. *Surg Radiol Anat.* 2010; 32: 447–453.
8. Hatiboğlu M.T., Anil A.: Structural variations in the jugular foramen of the human skull. *J Anat.* 1992; 180: 191–196.
9. Katsuta T., Rhoton A.L. Jr., Matsushima T.: The Jugular Foramen: Microsurgical anatomy and operative approaches. *Neurosurgery.* 1997; 41 (1): 149–202.
10. Ramina R., Maniglia J.J., Fernandes. Y.B., Paschoal J.R., Pfeilsticker L.N., Coelho Neto M.: Tumors of the jugular foramen: diagnosis and management. *Neurosurgery.* 2005; 57 (1): 59–68.
11. Friedman C.D., Costantino P.D., Teitelbaum B.S.: Primary extracranial meningiomas of the head and neck. *Laryngoscop.* 1990; 100: 41–48.
12. Kumen A., Mafee.M., Vassalli L.: Intracranial and infratemporal meningiomas with primary otologic symptoms. *Otolaryngol Head Neck Surg.* 1998; 99: 444–454.
13. Erongun U., Uyar Y., Çakir B., Uygun A., Kocaogullar Y.: Infratemporal approach for jugular foramen meningioma. *Turkish Neurosurgery.* 1993; 3: 128–133.
14. Khanday S., Subramanian R.M., Rajendran M., Hassan A.U., Khan S.H.: Morphological and morphometric study of jugular foramen in South Indian population. *Int J Anat Res.* 2013; 1: 122–127.
15. Adejuwon S.A., Salawu O.T., Ekeand C.C., Ajani R.S.: The Jugular Foramen and the Intracranial Volume; Are they Related? *Asian Journal of Medical Sciences.* 2011; 3 (8): 143–145.
16. Adams W.M., Jones R.L., Chavda S.V., Pahor A.L.: CT assessment of jugular foramen dominance and its association with hand preference. *Journal of Laryngology & Otology.* 1997; 111: 290–292.
17. Di Chiro G., Fisher R.L., Nelson K.B.: The jugular foramen. *Journal of Neurosurgery.* 1964; 21 (6): 447–460.
18. Lang J., Schreiber T.: Über Form und Lage des Foramen jugulare (Fossa jugularis), des Canalis caroticus und des Foramen stylomastoideum sowie deren postnatale Lageveränderungen. *HNO.* 1983; 31: 80–87.
19. Pereira G.A.M., Lopes P.T.C., Santos A.M.P.V., Krebs W.D.: Morphometric aspects of the jugular foramen in dry skulls of adult individuals in Southern Brazil. *J Morphol Sci.* 2010; 27 (1): 3–5.
20. Idowu O.E.: The jugular foramen — a morphometric study. *Folia Morphol.* 2004; 63 (4): 419–422.
21. Sturrock R.R.: Variations in the structure of the jugular foramen of human skull. *J Anat.* 1988; 160: 227–230.
22. Schelling F.: Die Emissarien des menschlichen Schädels. *Anat Anz.* 1978; 143: 340–382.
23. Ayeni S.A., Ohata K., Tanaka K., Hakuba A.: The microsurgical anatomy of the jugular foramen. *J Neurosurg.* 1995; 83: 903–909.
24. Ramos-Junior S.P., da Silva Gusmão S.N., Raso J.L., Nicolato A.A., Santos M., Caetano I.M.: Comparative morphometric study of the sigmoid sinus sulcus and the jugular foramen. *Arq Neuro-Psiquiatr.* 2014; 72 (9): 694–698.
25. Rudinger N.: Die Fossa jugularis und ihre individuelle grossenverschiedenheit. *Msschr Ohrenheilk.* 1875 (9): 1–7.
26. Aubaniac R.: Les variations du canal dechire posterieur. *Trav Lob Anat Fac Mdd Alger.* 1951: 23–33.
27. Patel R., Mehta C.D.: Morphometric study of jugular foramen at base of the skull in South Gujarat region. *IOSR Journal of Dental and Medical Sciences.* 2014 (9): 58–61.
28. Lindblom K.: A roentgenographic study of the vascular channels of the skull. With special reference to intracraual tumors and arterio-venousaneurysms. *Acta radiol, Stockh.* 1936; Suppl. 30; 146: 33–35.
29. Singla A., Sahni D., Aggarwal A., Gupta T., Kaur H.: Morphometric study of the jugular foramen in Northwest Indian population. *Journal of Postgraduate Medicine, Education and Research.* 2012; 46 (4): 165–171.
30. Osunwoke E.A., Oladipo G.S., Gwunireama I.U., Ngaokere J.O.: Morphometric analysis of the foramen magnum and jugular foramen in adult skulls in southern Nigerian population. *Am J Sci Ind Res.* 2012; 3 (6): 446–448.

31. Vijisha P, Billodi A.K., Lokeshmaran: Morphometric study of jugular foramen in Tamil Nadu region. *National Journal of Clinical Anatomy*. 2013; 2 (2): 71–74.
32. Wysocki J, Chmielik L.P., Gacek W.: Variability of magnitude of the human jugular foramen in relation to condition of the venous outflow after ligation of the internal jugular vein. *Otolaryngologia*. 1999; 53: 173–177.
33. Caldemeyer K.S., Mathews V.P., Azzarelli B., Smith R.R.: The jugular foramen: a review of anatomy, masses, and imaging characteristics. *RadioGraphics*. 1997; 17: 1123–1139.
34. Dodo Y.: A population study of the jugular foramen bridging of the human cranium. *American Journal of Physical Anthropology*. 1986; 69: 15–19.
35. Vlajković S., Vasović L., Daković-Bjelaković M., Stanković S., Popović J., Čukuranović R.: Human bony jugular foramen: Some additional morphological and morphometric features. *Med Sci Monit*. 2010; 16 (5): 140–146.
36. Burdan F., Umlawska W., Dworżański W., Klepacz R., Szumilo J., Starosławska E., Drop A.: Anatomical variances and dimensions of the superior orbital fissure and foramen ovale in adults. *Folia Morphol (Warsz)*. 2011; 70 (4): 263–271.
37. Skrzat J., Walocha J., Środek R., Niżankowska A.: An atypical position of the foramen ovale. *Folia Morphol (Warsz)*. 2006; 65 (4): 396–399.
38. Zhu H.Y., Zhao J.M., Yang M., Xia C.L., Li Y.Q., Sun H., Zhang Y.Q., Tian Y.: Relative location of foramen ovale, foramen lacerum, and foramen spinosum in Hartel pathway. *J Craniofac Surg*. 2014; 25 (3): 1038–1040.
39. Ginsberg L.E., Pruett S.W., Chen M.Y., Elster A.D.: Skull-base foramina of the middle cranial fossa: reassessment of normal variation with high-resolution CT. *AJNR Am J Neuroradiol*. 1994; 15 (2): 283–291.
40. Policeni B.A., Smoker W.R.: Imaging of the skull base: anatomy and pathology. *Radiol Clin North Am*. 2015; 53 (1): 1–14.