

Received: 2013.07.26  
Accepted: 2013.09.27

## Radiographic changes in the operative treatment of acute acromioclavicular joint dislocation – tight rope technique vs. K-wire fixation

Klemens Horst, Thomas Dienstknecht, Hagen Andruszkow, Gertraud Gradl, Philipp Kobbe, Hans-Christoph Pape

Department of Trauma and Reconstructive Surgery, University Hospital RWTH Aachen, Aachen, Germany

Author's address: Klemens Horst, Department of Trauma and Reconstructive Surgery, University Hospital RWTH Aachen, Paulwelsstraße 30, 52074 Aachen, Germany, e-mail: khorst@ukaachen.de

### Summary

**Background:**

Operative treatment of higher degree acromioclavicular joint luxation is common. A new option is made available by the tight rope technique. It claims to provide adequate outcome with the use of a minimally invasive technique. First clinical studies justified its medical use, but the equivalence to established surgical methods remains unclear. We therefore analyzed radiographic data from patients that were treated with the tight rope system (TR) and compared them to those treated with K-wires (KW) fixation.

**Material/Methods:**

Retrospective study with inclusion criteria: surgery for acromioclavicular joint luxation between 2004 and 2011, classified as Rockwood type III, no concomitant injury, first event injury. We compared pre- and post-operative X-rays with those taken at the end of treatment. Clinical data from follow-ups and radiographic data were evaluated. The main outcome variable was the remaining distance between the acromion and clavicle (ACD), as well as the coracoid process and clavicle (CCD).

**Results:**

27 patients (TR: n=16; KW: n=11) with comparable demographics and injury severity were included. Surgery reduced ACD (TR: p=0.002; KW: p<0.001) and CCD (TR: p=0.001; KW: p=0.003). Heterotopic ossification or postoperative osteolysis was not significantly associated with either one of the procedures. Three patients (18.75%) in the TR group showed impaired wound healing, migrating K-wires were recorded in 2 patients (18.2%) and impingement syndrome occurred in 1 patient (9.1%) with K-wires. Posttraumatic arthritis was not seen. There was a loss of reduction in 2 cases within the TR-group (12.51%) and 1 in the KW-group (9.1%). At last follow up, ACD and CCD were wider in both groups compared to the healthy side.

**Conclusions:**

This study shows that the Tight rope system is an effective alternative in the treatment of higher degree acromioclavicular luxation and comparable to the established methods.

**Key words:**

radiographic changes • K-wire • tight rope

**PDF file:**

<http://www.polradiol.com/download/index/idArt/889615>

### Background

Acromioclavicular joint dislocation (AC dislocation) typically affects young adults [1,2]. In 9 to 12 percent of shoulder girdle injuries the AC joint is involved [2,3]. The cause is usually a direct blow to the shoulder. Treatment of AC dislocation relies on the Rockwood classification system [4]. Additionally, AC joint injuries classified as either type I or

type II occur twice as often as the more severe type III or type VI injuries [3].

Operative treatment is typically performed in higher grade AC separation [5]. Indications for Rockwood type III dislocation have been widely discussed. While some publications postulate conservative treatment to be superior [6,7], Cecerelli et al. saw a deficiency in the operative treatment

of Rockwood type III dislocations [8]. Various methods have been described, such as an augmented suture with absorbable material, stabilization via K-wires in combination with or without additional wire loop, hook plate or the Bosworth screw [9–12]. A new option is offered by the TightRope™ system (Arthrex, Naples, USA) [13]. This technique was developed as a minimally invasive procedure to treat torn coracoid and trapezoid ligaments in acromioclavicular luxation. Due to its minimally invasive approach, traumatic soft tissue damage is reduced in comparison to open surgery procedures [13]. Additional advantages, such as no need for re-operation to remove hardware (wires, screws or plates) are striking. Complications of hardware failure like breakage, dislocation or bone resorption leading to reoperation and further harm to the patient should be minimized [14–16]. Better cosmetic results are also seen [17].

There are publications investigating operative treatment using the established methods named above. Results comparing different methods are rare and literature research regarding treatment with the tight rope device is slowly growing [18–20]. As a result, the situation concerning comparative investigations focusing on the advantages (safe stabilization of AC joint by K-wires, low morbidity *versus* minimally invasive approach and remaining implants in treatment by tight rope systems) and disadvantages (risk of material failure, decreased range of motion, operative revision *versus* difficult technique with expensive material) of both methods is unsatisfying.

We have focused on radiologic results and changes in verifying the value of either K-wire fixation or fixation using the tight rope technique. We therefore analyzed patients from our institution that were treated with one of the named procedures between 2005 and 2011. Acromioclavicular and coracoclavicular distances, presence of heterotopic ossification, postoperative osteolysis and arthritis were analyzed. Furthermore timing of surgical treatment, time of operative procedure and duration of hospital stay were assessed.

## Material and Methods

### Patient population

We performed a retrospective radiographic study that included patients diagnosed and treated at our institution between 2004 and 2011 with either the TightRope™ system (Arthrex, Naples, USA) or K-wire fixation. Inclusion criteria were first event injury, Rockwood type III dislocation, injury occurrence within 2 weeks, no concomitant injury and no previous surgery for acromioclavicular joint luxation.

Decision regarding the operative procedure was made by the operating surgeon after educating the patient about the risks and benefits of the surgical techniques. All patients provided their written informed consent before undergoing the operation.

### Surgical techniques

All patients were operated in beach chair position under general anesthesia.

In case of the minimally invasive tight rope system technique, a non-absorbable string was positioned through the boreholes between the coracoid process and the clavicle. Repositioning maneuver was performed and the string held in position by anchors placed underneath the coracoid process and above the clavicle [13].

K-wires (strength 1.6mm) were brought in from the lateral aspect of the acromion aiming cranially at the center of the lateral clavicle. The clavicle was then brought into position and K-wires were screwed in. Augmented sutures or suture of ruptured ligaments were additionally performed [21].

All patients followed a standardized postoperative treatment scheme [22].

### Radiologic evaluation

The distance between the acromion and lateral clavicle (AC), as well as between the coracoid process and clavicle (CC), was measured on the day of admission based on true anteroposterior views of the affected shoulder and on anteroposterior stress views with 10-kg load on both shoulders. Further x-rays were obtained within the first postoperative week, as well as during the last follow up (anteroposterior view). Results were compared to the distances on the patients' healthy side. The AC distance was measured between the center of the medial aspect of the acromion and the center of the lateral aspect of the clavicle. The CC distance was measured between the coracoid and inferior cortex of the clavicle. We then compared measurement results from both groups. We also focused on heterotopic ossification and postoperative osteolysis in both groups.

### Statistics

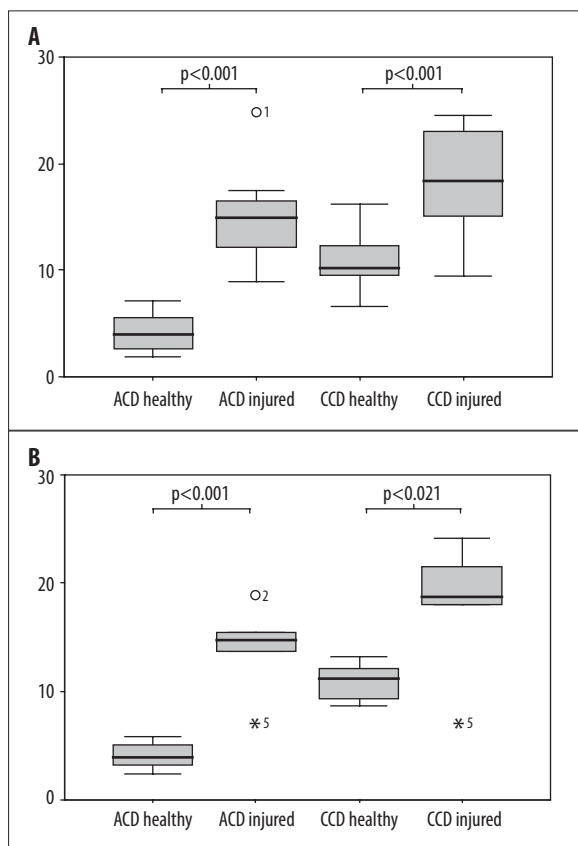
Statistics were carried out by SPSS (Version 11.5.1). The Kolmogorov-Smirnov-Test was used on all data to test for normal distribution. Metric data were compared using the Student t-test. Results were analyzed and compared with each other. The chi-square test was used to detect the impact of each procedure. Descriptive results were demonstrated as the mean  $\pm$ sd. The level of significance was defined as  $p=0.05$ . Graphics were illustrated by using SPSS (Version 11.5.1) and Windows EXCEL®.

## Results

### Radiographic results

The TR group included 16 patients (male  $n=15$ ; female  $n=1$ , mean age 38.9 years (range 25–63)). The KW group included 11 patients (male  $n=10$ ; female  $n=1$ , mean age 32.2 years (range 25–44)). Most injuries were caused by sport activities ( $n=6$ ), followed by traffic accidents by car ( $n=5$ ), motorcycle ( $n=4$ ) and bicycle ( $n=5$ ). Falls were another cause ( $n=4$ ). In 3 cases the c could not be reconstructed. All demographic data, clinical and operative information, as well as time intervals were revealed by chart review.

In both groups, the distance between the acromion and lateral clavicle (ACD), as well as the coracoid process and



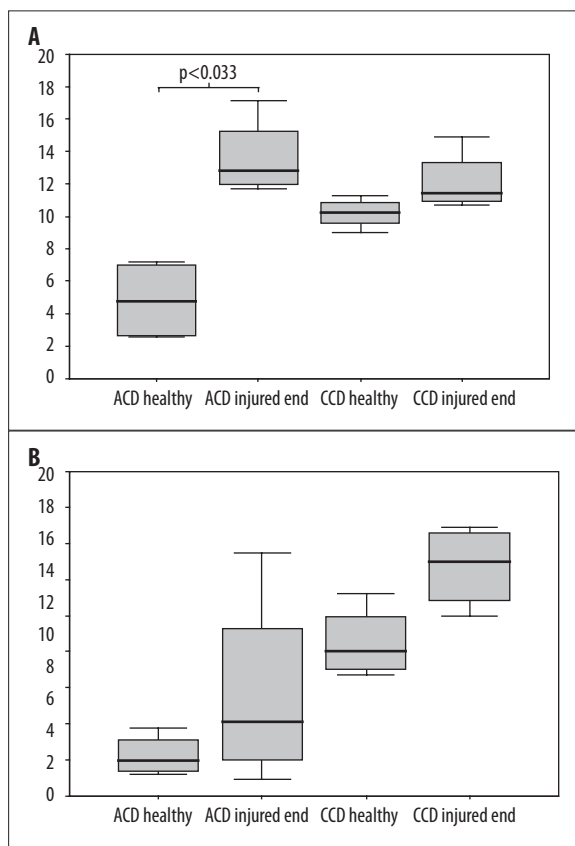
**Figure 1.** (A) AC & CC distance in millimeters in the TR group. (B) AC & CC distance in millimeters in the KW group.

clavicle (CCD) was significantly higher on the injured side as compared to the healthy one (TR ACD  $4.27 \pm 1.87$  vs.  $14.3 \pm 4.75$  and CCD  $10.89 \pm 2.67$  vs.  $17.11 \pm 5.3$ ; KW ACD  $4.07 \pm 1.27$  vs.  $14.34 \pm 3.61$  and CCD  $10.95 \pm 1.72$  vs.  $17.16 \pm 6.04$ ) (Figure 1A, 1B).

First radiologic follow up concerning anteroposterior view was performed within the first postoperative week. Surgery reduced ACD (TR  $14.3 \pm 4.75$  vs.  $6.69$ ,  $p=0.002$ ; KW  $17.16 \pm 6.04$  vs.  $3.86 \pm 1.59$ ,  $p<0.001$ ) and CCD (TR  $17.11 \pm 5.3$  vs.  $10.63 \pm 2.53$ ,  $p=0.001$ ; KW  $17.15 \pm 6.04$  vs.  $9.66 \pm 5.04$ ,  $p=0.003$ ) (Figure 2A, 2B). Comparison of the initial ACD on each patient's healthy side with early postoperative results displayed reduction from the traumatic increases in ACD and CCD and good reconstruction alignment in both groups.

The last radiologic follow up in the TR group was performed 6 weeks after surgery and after 21 weeks in the KW group. Results were compared to the distance on the patients' contralateral healthy side and also to preoperative measurements. The last radiologic control revealed higher ACD and CCD in comparison to the healthy side (TR ACD  $10.48 \pm 5.29$  vs.  $4.27 \pm 1.87$  and CCD  $11.55 \pm 1.77$  vs.  $10.89 \pm 2.67$ ; KW ACD  $6.93 \pm 4.75$  vs.  $4.07 \pm 1.27$  and CCD  $13.52 \pm 2.69$  vs.  $10.95 \pm 1.72$ ). ACD in the TR group showed significant difference (Figure 2A, 2B).

With the exception of early postoperative follow up, no significant differences were noted in the distances measured



**Figure 2.** (A) AC & CC distance in millimeters during last radiological follow up compared to the healthy side (TR group). (B) AC & CC distance in millimeters during last radiological follow up compared to the healthy side (KW group).

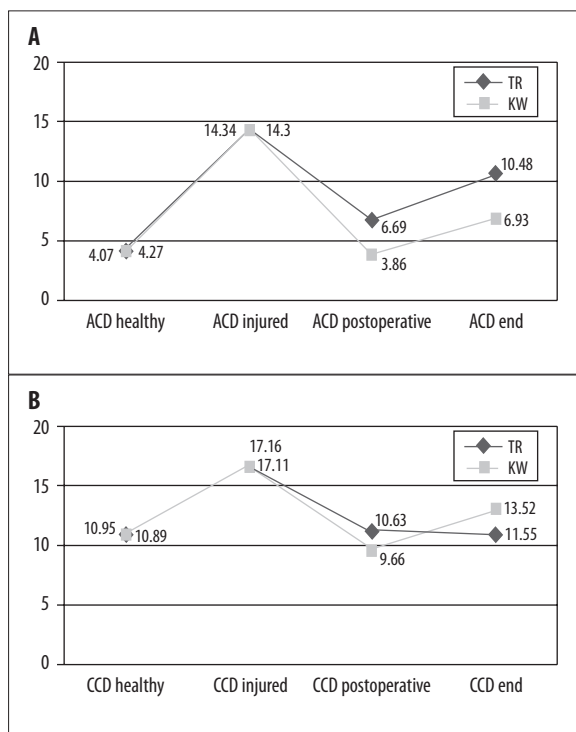
between the day of injury and the last radiological follow up (Figure 2A, 2B).

Comparison of ACD and CCD of the TR- with the KW cohort showed equal measurements on the healthy, as well as the injured preoperative radiographs. Although by the end of the treatment, there was a tendency toward greater distances in ACD and CCD in the TR group, significant shift toward one of the groups could not be seen (Figure 3A, 3B).

Radiological signs of heterotopic ossification were seen in 2 cases in the KW group (18.2%), yet neither of the operative procedures was significantly associated with heterotopic ossification. Signs of posttraumatic osteolysis could not be seen in either group, nor in posttraumatic arthritis.

### Clinical results

Patients from both groups were operated on average within 5.7 days (range 1–13) after sustaining trauma. However, patients from the TR group were more likely to be discharged earlier. They left hospital after 2 days (range 1–4), while patients from the KW group left hospital after 2.6 days (range 1–4). Surgery time in the TR group exhibited shorter duration (61.6 min (range 36–101) vs. 84.8 min (range 51–187)). Three patients (18.75%) in the TR group showed impaired wound healing, migrating K-wires were recorded in 2 patients (18.2%) and impingement syndrome



**Figure 3.** (A) AC in millimeters on healthy side and injured side on day of trauma, postoperatively and on last radiological follow up in the TR- and KW groups. (B) CC in millimeters on the healthy side and injured side on day of trauma, postoperatively and on last radiological follow up in the TR- and KW groups.

occurred in 1 patient (9.1%) with K-wires. There was a loss of reduction (more than 1 clavicle shaft width) in 2 cases within the TR-group (12.51%) and 1 in the KW-group (9.1%).

## Discussion

Due to high percentage of AC joint dislocation in shoulder injuries, different operative techniques have been developed and are frequently found in the treatment of higher grade AC joint separation. The use of hook plate, temporary K-wire fixation or the Bosworth screw is common [9–12]. Treatment of Rockwood type III dislocation is considered controversial. Due to lack of high quality investigations regarding this issue, Cecarelli et al. called for more prospective randomized studies using validated outcome measures to identify suitable operation techniques for acute injuries [8].

A new option for the treatment of higher grade acromioclavicular separations is provided by the tight rope reconstruction technique. This method represents a minimally invasive procedure to treat torn conoid and trapezoid ligaments in the presence of acromioclavicular dislocation [13].

Literature regarding the Tight rope device, its indications, applications and outcomes is growing. Patzer et al. compared a single (STR) to a double (DTR) Tight rope technique and found that the DTR technique provides lower CC distances compared to the STR technique, but fails to provide a significant difference in CC distance and scores

[23]. Scheibel et al. proved that a combined arthroscopically assisted and image intensifier-controlled DTR technique is a safe procedure that yields good- to excellent early clinical results. Still, partial recurrent vertical and horizontal AC joint instability is present [19]. Despite partial recurrent instability, Gerhardt et al. also reported favorable clinical results following arthroscopic AC joint stabilization using the DTR technique [24].

To our knowledge, there are no comparative studies emphasizing the radiological changes of this new and promising device to established methods. Due to the fact that operative treatment in Rockwood III separations is considered controversial, we only included patients graded with a Rockwood III lesion. Our patient cohort was homogenous with regard to age, gender and physical activity. Patients from both groups were operated within the same time interval following injury. However patients from the TR group tended to be discharged earlier. The reasons for finding could include the fact that the Tight rope system is a minimally invasive procedure using small incisions that cause less soft tissue damage, is less invasive in placement of foreign material and offers a higher postoperative range of motion.

Focusing on the x-ray examination, the patient's injured side was compared to the healthy one. Preoperative radiographs revealed a significant increase in the AC and the CC distances in both the TR and KW groups (Figure 1A, 1B). Early postoperative radiographic controls demonstrated a significant reduction in the AC and CC distances compared to preoperative status. Reduction was achieved using either one of the procedures and good alignment reconstruction was observed in both cohorts (Figure 3A, 3B). We therefore confirm measurement results that were taken in other studies evaluating the tight rope system in the early postoperative period [19,23].

However, during clinical follow-up, loss of reduction was seen in 2 cases within the TR-group and 1 in the KW-group. Compared to stable fixation via K-wires, acromioclavicular alignment by tight rope reconstruction is held by simple sutures. Walz et al. demonstrated that anatomic reconstruction of the AC joint using the tight rope is a stable and functional anatomic reconstruction procedure, which displayed favorable *in vitro* results with equivalent or even higher forces than native ligaments [25]. Nevertheless, suture rupture with loss of reduction is the main complication that may occur due to tunnel malpositioning or implant loosening [18,26]. Motta et al. noted that the use of flip buttons may not be indicated in patients with joint hyperlaxity. The device obtains immediate stability only on the vertical plane and not on the horizontal plane. Therefore, he points to anteroposterior movements of the acromioclavicular joint that may rub the suture against bone tunnels, leading to wear and tear [26].

Due to the fact that K-wires maintain a rigid stabilization during recovery, mobility is decreased. The wires lower the forces that are put on the acromioclavicular joint. Nevertheless, as long as an internal fixation stabilizes the AC joint, a judgment about the success of this treatment option cannot be made. We therefore performed the last

radiological control 6 weeks after the surgery in the TR group and after 21 weeks in the KW group. By this time, the K-wires were removed and treatment was completed. Results from the formerly injured side were compared to the distances measured on the healthy side. Distance in the AC joint was significantly higher in the TR group, while CC distance did not show a significant difference. AC and CC distance in the KW group did not show significantly increased distances, either. Furthermore, there was no longer a significant reduction in the distance measured during the last radiographic controls as compared to the pre-operative status, in both groups. Postoperative widening in the AC and CC distances is described commonly by authors analyzing established AC repair methods [15] and seems to be present in treatment with the tight rope device [19,23] or using comparable devices [27,28]. Literature addressing this topic is slowly beginning to appear. To our knowledge, only Patzer et al. have published data that provide information about reduced CC distance after double tight rope reconstruction compared to the STR technique. Comparison of the distances measured in the TR group with those from the KW group, provided equal results in preoperative radiographs on the healthy and the injured sides, which is due to homogenous cohorts. Postoperatively, the ACD and the CCD measured in the KW group were closer to the distances measured on the healthy side than to distances from the TR group. Better alignment was achieved by K-wire stabilization. Following the removal of K-wires, the ACD continued to appear wider in the TR group, while CCD rose in the KW group. No significant difference in the distance measurements comparing the two groups was seen.

Regarding posttraumatic ossification, we cannot confirm the high rates described by Rehbein et al. [29]. They published a report concerning transosseal acromioclavicular and coracoclavicular FiberWire cerclage for the treatment of acute acromioclavicular dislocation. Their study included acromioclavicular separations graded Type III–V, while we focused solely on Type III separations. We are not certain whether more complex dislocations have a higher tendency for ossification, or if the operative technique has an influence on heterotopic ossification. Mouhsine et al. reported a small percentage of posttraumatic ossifications in conservative treatment of dislocations graded Type I and II [30]; as did Calvo et al., who compared surgical treatment vs. conservative treatment in dislocations graded

Rockwood III [31]. On the other hand, the procedure itself could be questioned. Kim et al. did not find high rates of postoperative ossification after coracoacromial ligament transfer in patients with chronic type V dislocation and Eulert et al. named operative procedures as one risk factor for heterotopic ossification [32,33]. Zhao et al. described a higher percentage of heterotopic ossifications in the arthroscopic double Endobutton fixation technique compared to a modified Dewar technique [34]. We believe that the use of Tight rope is not associated with an increased risk for heterotopic ossification, but despite having a good working hypothesis, the causes of heterotopic ossification remain unclear. Further studies must focus on the causes of post-traumatic ossification, before it can be revealed as to what extent different operative techniques are affected by it.

Although this is a retrospective study with missing indications for performing x-rays on patients with asymptomatic clinical follow-ups, our intention was to compare an established treatment option of acromioclavicular joint separation with a new operative procedure. Based on our data, we conclude that the use of a minimally invasive tight rope device is an effective and safe alternative for the treatment of higher degree acromioclavicular luxation that is comparable to the already established methods. Severe radiographic changes (heterotopic ossification, osteolysis, arthritis was not associated with neither procedure). Long-term clinical and radiographic results are still rare and need to be evaluated in further studies.

#### Advances in knowledge

This is the first study focusing on radiographic results after implementation of the Tight rope system as a new option for the treatment of acromioclavicular joint separation.

#### Conflicts of interest

The authors declare no conflict of interest, including financial, consultant, institutional or other relationships.

#### Acknowledgements

The article was proofread by Proof-Reading-Service.com, Devonshire Business Centre, Works Road, Letchworth Garden City, SG6 1GJ, United Kingdom.

#### References:

1. Clayton RA, Court-Brown CM: The epidemiology of musculoskeletal tendinous and ligamentous injuries. *Injury*, 2008; 39(12): 1338–44
2. Rockwood C, Williams, G, Young D: Disorders of the AC joint. The Shoulder. Vol Volume 1. Philadelphia: WB Saunders: 483
3. Lemos MJ: The evaluation and treatment of the injured acromioclavicular joint in athletes. *Am J Sports Med*, 1998; 26(1): 137–44
4. CA R, GR W, DC Y: Acromioclavicular injuries. In: Rockwood CA GD, Bucholz RW, Heckman JD (eds.): *Fractures in Adults*. Vol 4<sup>th</sup> ed. Philadelphia, PA: Lippincott-Raven, 1996; 1341–413
5. Bradley JP, Elkousy H: Decision making: operative versus nonoperative treatment of acromioclavicular joint injuries. *Clin Sports Med*, 2003; 22(2): 277–90
6. Spencer EE: Treatment of grade III acromioclavicular joint injuries: a systematic review. *Clin Orthop Relat Res*, 2007; 455: 38–44
7. Hootman JM: Acromioclavicular Dislocation: Conservative or Surgical Therapy. *J Athl Train*, 2004; 39(1): 10–11
8. Ceccarelli E, Bondi R, Alviti F et al: Treatment of acute grade III acromioclavicular dislocation: a lack of evidence. *J Orthop Traumatol*, 2008; 9(2): 105–8
9. Leidel BA, Braunstein V, Kirchhoff C et al: Consistency of long-term outcome of acute Rockwood grade III acromioclavicular joint separations after K-wire transfixation. *J Trauma*, 2009; 66(6): 1666–71
10. Ejam S, Lind T, Falkenberg B: Surgical treatment of acute and chronic acromioclavicular dislocation Tossy type III and V using the Hook plate. *Acta Orthop Belg*, 2008; 74(4): 441–45
11. Eberle C, Fodor P, Metzger U: Hook plate (so-called Balsler plate) or tension banding with the Bosworth screw in complete acromioclavicular dislocation and clavicular fracture. *Z Unfallchir Versicherungsmed*, 1992; 85(3): 134–39

12. Weitzmann G: Treatment of Acute Acromioclavicular Joint Dislocation by a Modified Bosworth Method report on twenty-four cases. *J Bone Joint Surg Am*, 1967; 49: 1167-78
13. Salzmann GM, Walz L, Schoettle PB et al: Arthroscopic anatomical reconstruction of the acromioclavicular joint. *Acta Orthop Belg*, 2008; 74(3): 397-400
14. Bragin VB, Bezgodkov Iu A: Comparative evaluation of the methods of treatment of dislocations of the clavicle. *Vestn Khir Im I I Grek*, 2002; 161(4): 33-36
15. Melenevsky Y, Yablon CM, Ramappa A et al: Clavicle and acromioclavicular joint injuries: a review of imaging, treatment, and complications. *Skeletal Radiol*, 2011; 40(7): 831-42
16. Li BC, Zhang M, Shi D, Yang ZX et al: [Postoperative complications of acromioclavicular joint dislocation of Tossy III]. *Zhongguo Gu Shang*, 2009; 22(2): 95-97
17. Basyoni Y, El-Ganainy AE, Aboul-Saad M: Acromioclavicular joint reconstruction using anchor sutures: surgical technique and preliminary results. *Acta Orthop Belg*, 2010; 76(3): 307-11
18. Thiel E, Mutnal A, Gilot GJ: Surgical outcome following arthroscopic fixation of acromioclavicular joint disruption with the tightrope device. *Orthopedics*, 2011; 34(7): e267-74
19. Scheibel M, Droschel S, Gerhardt C et al: Arthroscopically assisted stabilization of acute high-grade acromioclavicular joint separations. *Am J Sports Med*, 2011; 39(7): 1507-16
20. El Sallakh SA: Evaluation of Arthroscopic Stabilization of Acute Acromioclavicular Joint Dislocation Using the TightRope System. *Orthopedics*, 2012; 35(1): e18-22
21. Weigel B, Nerlich M: *Praxisbuch Unfallchirurgie. Vol 2. Erding*, Regensburg, Springer, 2011 [in German]
22. Horst K, Dienstknecht T, Pape HC: Die operative Versorgung der Akromioklavikurgelenkssprengung *OP Journal*, 2013; 1/2013: 24-30 [in German]
23. Patzer T, Clauss C, Kuhne CA et al: [Arthroscopically assisted reduction of acute acromioclavicular joint separations: Comparison of clinical and radiological results of single versus double TightRope technique.]. *Unfallchirurg*, 2012
24. Gerhardt C, Kraus N, Pauly S et al: [Arthroscopically assisted stabilization of acute injury to the acromioclavicular joint with the double TightRope technique: One-year results.]. *Unfallchirurg*, 2011
25. Walz L, Salzmann GM, Fabbro T et al: The anatomic reconstruction of acromioclavicular joint dislocations using 2 TightRope devices: a biomechanical study. *Am J Sports Med*, 2008; 36(12): 2398-406
26. Motta P, Maderni A, Bruno L et al: Suture rupture in acromioclavicular joint dislocations treated with flip buttons. *Arthroscopy*, 2011; 27(2): 294-98
27. Petersen W, Wellmann M, Rosslenbroich S et al: Minimally Invasive Acromioclavicular Joint Reconstruction (MINAR). *Oper Orthop Traumatol*, 2010; 22(1): 52-61
28. Murena L, Vulcano E, Ratti C et al: Arthroscopic treatment of acute acromioclavicular joint dislocation with double flip button. *Knee Surg Sports Traumatol Arthrosc*, 2009; 17(12): 1511-15
29. Rehbein K, Jung C, Becker U et al: [Treatment of acute AC joint dislocation by transosseal acromioclavicular and coracoclavicular fiberwire cerclage]. *Z Orthop Unfall*, 2008; 146(3): 339-43
30. Mouhsine E, Garofalo R, Crevoisier X et al: Grade I and II acromioclavicular dislocations: results of conservative treatment. *J Shoulder Elbow Surg*, 2003; 12(6): 599-602
31. Calvo E, Lopez-Franco M, Arribas IM: Clinical and radiologic outcomes of surgical and conservative treatment of type III acromioclavicular joint injury. *J Shoulder Elbow Surg*, 2006; 15(3): 300-5
32. Kim SH, Lee YH, Shin SH et al: Outcome of conjoined tendon and coracoacromial ligament transfer for the treatment of chronic type V acromioclavicular joint separation. *Injury*, 2012; 43(2): 213-18
33. Eulert J, Knelles D, Barthel T: Heterotopic ossifications. *Unfallchirurg*, 1997; 100(8): 667-74
34. Zhao LL, Zhang YN, Xue QY et al: Comparative analysis of modified Dewar method versus arthroscopic double Endobutton fixation technique for the treatment of acute acromioclavicular joint dislocation. *Zhonghua Yi Xue Za Zhi*, 2011; 91(23): 1587-90