

Received: 2014.02.26
Accepted: 2014.02.26
Published: 2014.05.20

Breast Magnetic Resonance Imaging (MRI) – expectations versus possibilities. Problem concerning clinician–radiographer, and radiographer–radiographer communication

Józef Gancarz

Department of Radiology and Diagnostic Imaging, Specialist Hospital in Brzozów, B. Markiewicz Subcarpathian Oncological Centre, Brzozów, Poland

Author's address: Józef Gancarz, Department of Radiology and Diagnostic Imaging, Specialist Hospital in Brzozów, B. Markiewicz Subcarpathian Oncological Centre, Ks. J. Bielawskiego 18 Str., 36-200 Brzozów, Poland,
e-mail: gancarzj@poczta.onet.pl

Summary

As the number of MRI laboratories equipped with resonance systems featuring magnetic field strengths of more than one Tesla as well as coils dedicated to breast examinations increases, such examinations are being made at increasing frequency.

Clinicians expect the summaries to include exhaustive information concerning the topography of detected lesions as well as approximate staging of the disease process, which helps them in making decisions regarding further management. On the other hand, radiographers performing medical check-ups, expect the previous examination summary to include a wide range of information facilitating comparative analysis and evaluation of scan efficacy.

Undoubtedly, breast MR offers an opportunity to obtain aforementioned information. However, the indispensable requirement for preparation of such summary is radiographer's awareness of the expectations being raised. We have to face the difficult task of standardizing the summaries, and even more than that, of making our colleagues aware of the importance of each sentence included in or excluded from the summary. This article is an attempt to present the correct form of a medical examination summary which should include data concerning former diagnostic examinations, detailed description of morphology as well as the location of lesions being diagnosed and suspected of malignant character together with the assessment of their relation to the skin and fascia as well as infiltration of fascia and chest wall. The essential requirement is the analysis of the contrast enhancement curve as well as the appraisal of diffusion limitation with numerical ADC values. Assessment of lymph nodes is also required, as is the classification of lesions into appropriate BI RADS in summary conclusions.

In order to avoid significant differences in the phrasing of summaries prepared at particular centers as well as by particular individuals, a general scheme forming a basis for the summary should be adopted or else, a list of questions to be answered in order to make the summary complete, comprehensible and unambiguous should be developed. Such procedures would certainly make the radiologist's work easier; it would also ensure radiographers being better understood by fellow radiographers and clinicians.

MeSH Keywords: Breast • Report • Magnetic Resonance Imaging

PDF file: <http://www.polradiol.com/download/index/idArt/890597>

Background

Recent years witnessed a rapid increase in the number of magnetic resonance labs featuring systems with magnetic field strengths of more than one Tesla. Due to the above, the number of scans performed in Poland increases each month, naturally leading to increasing numbers of clinicians' requests for consultations explaining examination summary terms that are commonly used by radiologists but not widely understood by others. It is also common that patients reporting for follow-up examinations are able to provide only the summary of previous examination, without imaging documentation, or that defective data carriers make it impossible to display the previous scan files. Breast MRI examinations are also in this number, as the diagnostic value of scans is increasingly appreciated by clinicians. What are the clinicians' expectations? Clinicians expect information allowing them to decide upon further management, including possible surgical treatment if the patient is qualified.

The objective of this work was to define what should be included in breast MRI scan reports so that they are clear and comprehensible as well as contain information important for clinicians while simultaneously being an exhaustive source of information allowing for possibly most accurate comparative analyses in the absence of imaging documentation.

Discussion

The referring physician awaits answers to a number of questions. Firstly, can the lesion in question be described as malignant? If yes, what is the actual extent and stage of the disease, i.e. is it an isolated lesion, a multifocal or multicentered process; does the lesion infiltrate the skin, fascia or chest wall; what is the topography of the lesion and its location in relation to the skin, nipple and fascia [1]. The last and a very important issue is related with suspected lymph nodes within axillary and parasternal fossae. Can MRI scans answer these questions? With no doubt, yes. Magnetic resonance imaging is the only technique allowing to assess the current stage of neoplastic growth. However, for this information to reach the addressee, i.e. the clinician, it must be included in the summary. Uninformative and incomprehensible summaries can still be encountered, albeit rarely. An example summary of this type may be the following: after introductory data on examination methodology, the summary reads "Malignant lesion sized 25×20 mm, gain curve type 3, in the left outer upper quadrant. Otherwise breasts unremarkable, lymph nodes normal". Can this summary be considered exhaustive? Surely not, as it does not contain the minimum information that would allow to decide upon further treatment. On the opposite pole, there are summaries with detailed descriptions of simple cysts, intraglandular or axillary lymph nodes, or asymmetrical distribution of normal gland tissue.

Let us therefore follow the step by step guidelines to what should constitute, in Author's opinion, a correct summary to be considered a standard in breast MRI. Let us assume that the following were detected: a single malignant lesion, multiple benign lesions, i.e. simple cyst, a suspected

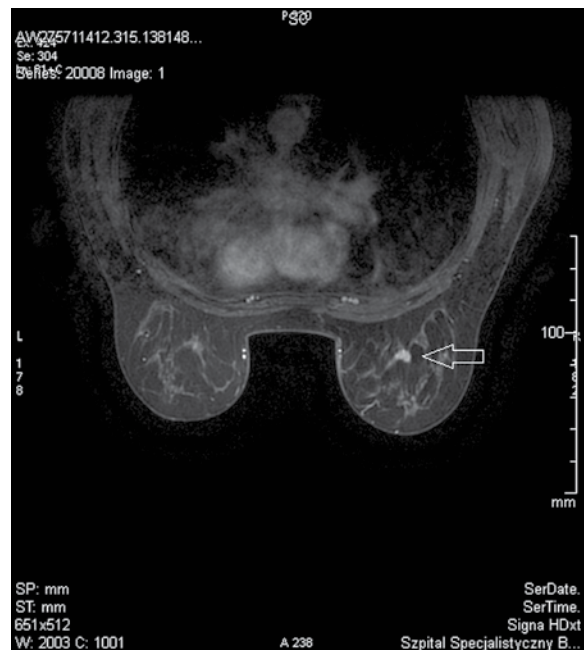

Figure 1. MRI, T1-weighted image with fat saturation, dynamic scan, axial plane. A small (11×8 mm) smooth, well-circumscribed nodule of the right breast localized at the border of the upper inner and upper outer quadrants (arrow). Carcinoma invasivum NST G1. (WHO 2002: Carcinoma ductale invasivum NOS G1 mammae).

intraglandular lymph node and lymph nodes in axillary fossa level I and II.

The introductory remarks of the summary include the data on the scanning method. Since examinations should be performed in all labs according to the same predefined guidelines, this part of the summary should be limited to the essential minimum. Next, the reason for referral should be mentioned briefly, e.g.: "Patient with BRCA1 mutation burden referred for prophylactic scan" or "previous mammography and/or ultrasound scans revealed a lesion classified as BI RADS category ... within the ... breast". This short phrase provides some valuable information, particularly when the patient is transferred from another site with incomplete documentation. In the next stage, we should proceed to the description of detected pathologies, starting from the most important ones. Firstly, we should focus on the lesion with malignant features, attempting to provide concise and comprehensible yet exhaustive information for the clinician and the radiologist who might be performing a follow up scan. Figures 1–3 illustrate the variety of morphologies and stages of malignant breast lesions. Presentation of lesion behavior in individual scanning sequences appears redundant as it significantly elongates the summary while the language that might be incomprehensible for an average clinician may discourage them from more detailed analysis of the summary.

Let us start from identification of the lesion's location and morphology: "in the left breast, at 2:00 hours, 75 mm from the mamilla, 15 mm deep under skin and 20 mm from the fascia, a single tumor lesion with no signs of fascia infiltration, sized 12×15×20 mm. The tumor has irregular, partially blurred contour and features of central necrosis".

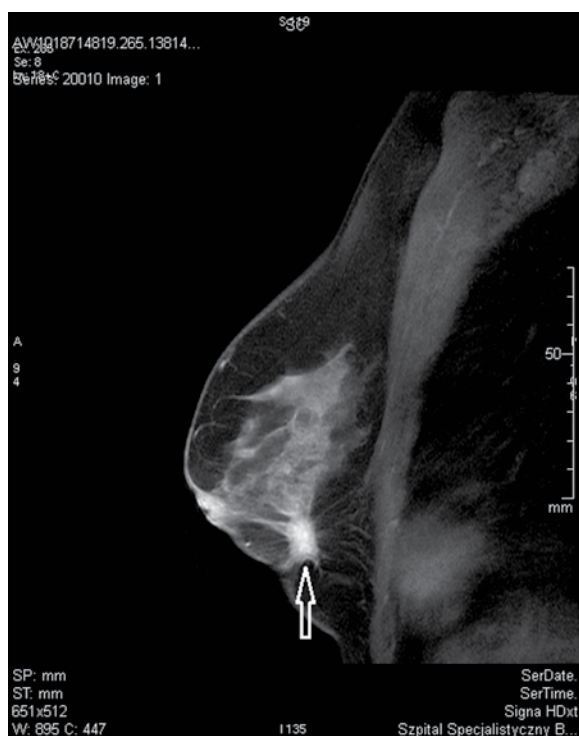

Figure 2. MRI, T1-weighted image with fat saturation, sagittal plane, acquisition immediately after dynamic phase end. Spiculated, blurry-edged tumor of the right breast localized at the border of the lower inner and lower outer quadrants, causing the nipple and skin retraction (arrow). Carcinoma invasivum NST G2. (WHO 2002: Carcinoma ductale invasivum NOS G2 mammae).

Further on, we describe the contrast enhancement by referring to its dynamics. As is well known, there are three types of gain curves, with malignant lesions being characterized by type III curves [2]. The phrase “lesion of gain curve type III” is insufficient for two reasons. Firstly, the term may be incomprehensible for some clinicians. Secondly, it provides too little information, not allowing to compare the metabolism of the lesion in a follow up scan when appropriate data processing software is lacking [3]. Type III curve may be defined by completely different numerical value sets, as illustrated in Figures 4–6. What words should we wrap the curve in? I propose the following phrasing: “Non-homogenous enhancement of the focal lesion; irregular regions characterized by type III curve in the dynamic scan are visible. Areas of strongest vascularization feature strong early contrast enhancement of up to 220% within 160 seconds of the dynamic scan, followed by strong wash-out effect down to 130% in 490 seconds”.

Description of limited diffusion is another element of the summary. Again, one should not content oneself with the sentence “the lesion is characterized by limited diffusion in DWI scan”. As we know, DWI scan is required to determine limitations in diffusion. Due to the lack of numerical ADC values which may undergo characteristic changes, for instance over the course of chemotherapy, these valuable data would not be provided to the clinician or radiologist conducting further treatment or diagnostic examinations.

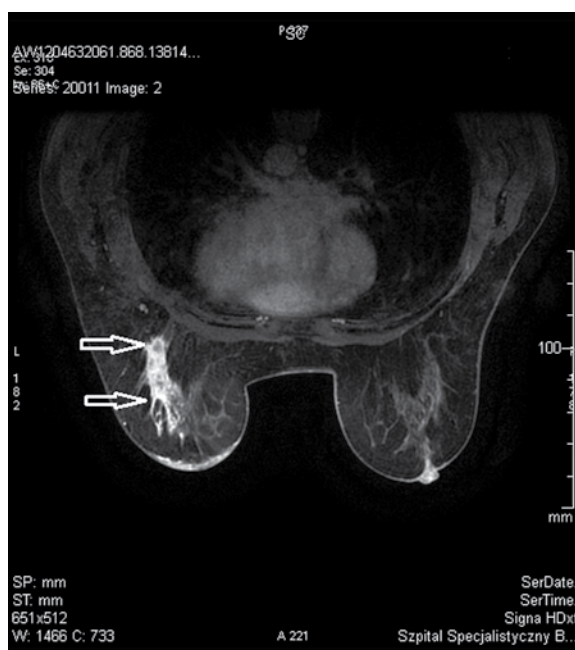


Figure 3. MRI, T1-weighted image with fat saturation, dynamic scan, transverse plane. Extensive, advanced neoplastic transformations of irregular edges and non-homogenous contrast enhancement localized in the outer quadrants of the right (arrows). Carcinoma invasivum NST G3. (WHO 2002: Carcinoma ductale invasivum NOS G3 mammae).

Thus, the statement should read as follows: “The lesion features diffusion limitation suggestive of its malignant character, ADC of ca. $0.9 \times 10^{-3} \text{ mm}^2/\text{s}$ ”.

We have thus completed the description of the focal lesion showing features of malignancy. Let us now proceed the assessment of lesions that accompany the neoplastic growth. We should determine the location of suspected lymph nodes, if any. “In the vicinity of the above focal lesion, also at 2:00 hours, peripherally and in a distance of 12 mm, a suspected intraglandular lymph node is visible, enlarged to ca. $9 \times 7 \text{ mm}$ ”. In level I of left axillary fossa there are several spherical lymph nodes featuring strong non-homogenous contrast enhancement and partial contour blurring; the largest node being ca. 14 mm in size. Two tiny lymph nodes with features as above and sized about 6 mm each are also visible in level II – image of suspected metastatic lesions”.

Having completed describing the most important pathologies, we should devote few words to the remaining, obviously benign lesions, if any are detected. “Besides the above, both breasts feature non-numerous, scattered simple cysts, largest cysts being ca. 10 mm in diameter. No other focal lesions detected.”

To complete the summary, one should highlight the lack of detected lymph nodes suspected of metastatic lesions in the remaining locations typical for this type of locations. “No suspected lymph nodes in level III of left axillary fossa as well as right axillary fossa. Parasternal lymph nodes not visible.” If any artifacts were identified in the examination, they should be mentioned in the final part of the summary [4].

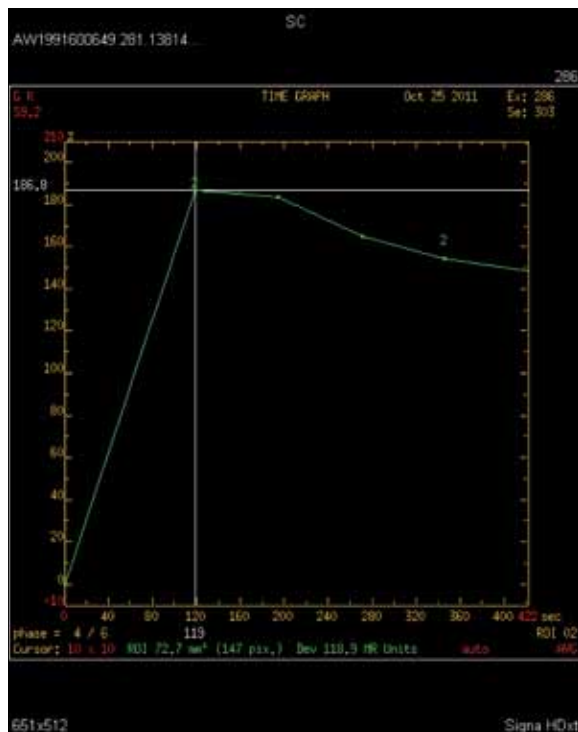


Figure 4. Gain curve type III. Strong, early contrast enhancement of up to 187% within 119 seconds of longitudinal study, weak wash-out effect down to 150%. Carcinoma invasivum NST G2. (WHO 2002: Carcinoma ductale invasivum NOS G2 mammae).

The last step of the summary is formulation of conclusions. An absolute obligation is to qualify the lesion into an appropriate BI RADS category, with location being highlighted. One should once again point to the presence of suspected lymph nodes. In our example case, the conclusions should be as follows: "Tu mammae sin.- BI RADS 5. Suspected intraglandular lymph nodes and left axillary fossa level I and II lymph nodes".

To summarize the above considerations, it should be highlighted that breast MRI provides a possibility to obtain comprehensive and unambiguous assessment of pathological lesions provided that it is performed together with the analysis with previous diagnostic examinations, particularly mammography and ultrasound scans. One should always and unconditionally request the delivery of patient's documentation, i.e. the summaries of ultrasound examinations conducted to date and particularly the imaging documentation of previous mammographic examinations. An exception is reserved for patients with BRCA 1 and 2 mutations in whom mammography is not performed and MRI and ultrasound scans are considered basic prophylactic examinations. The overall assessment of these scans would allow correct qualification of lesions while safeguarding us against mistakes that might bear serious consequences for both the patient and the radiologist. From this standpoint, it is unacceptable for radiologists without expertise in primary methods to interpret the breast MRI scans.

With the above guidelines being observed, one arrives at an examination summary which would, in Author's opinion,

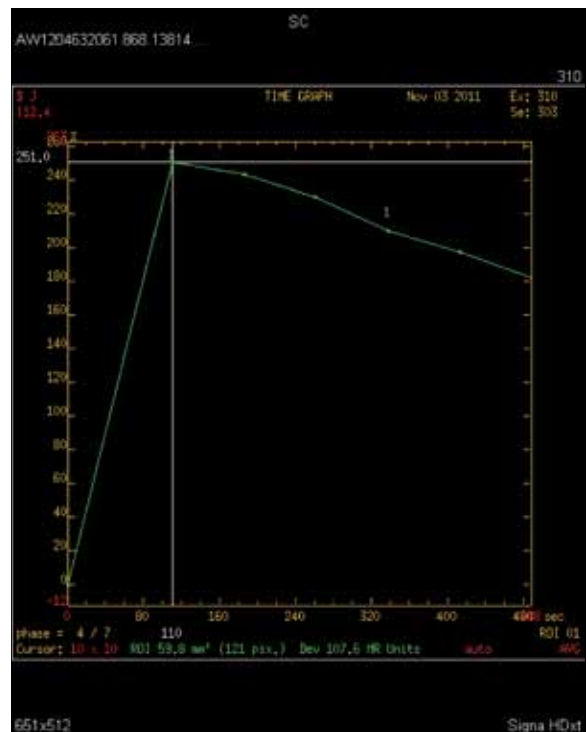


Figure 5. Gain curve type III. Strong, early contrast enhancement of up to 250% within 110 seconds of longitudinal study, noticeable wash-out effect down to 180%. Carcinoma invasivum NST G3. (WHO 2002: Carcinoma ductale invasivum NOS G3 mammae).

both meet the expectations of clinicians and provide information required for possible comparative assessment to other radiologists. The summary would read as follows: Scans were acquired using typical sequences to obtain T1- and T2-weighted images in transverse planes before and after i.v. administration of a contrast agent; dynamic and DWI scans were also performed. Patient was referred for MRI scan with the objective of disease staging. Previous ultrasound and mammography examinations revealed a lesion within the left breast and suspected lymph nodes within left axillary fossa – BI RADS 4. Adipose/glandular breast tissue. Within the left breast, at 2:00 hours, 75 mm from the mamilla, 15 mm deep under skin and 20 mm from the fascia, a single tumor lesion with no signs of fascia infiltration, sized 12×15×20 mm. The tumor has irregular, partially blurred contour and features of central necrosis. Non-homogenous enhancement of the focal lesion; irregular regions characterized by type III curve in the dynamic scan are visible. Areas of strongest vascularization feature strong early contrast enhancement of up to 220% within 160 seconds of the dynamic scan, followed by strong wash-out effect down to 153% in 490 seconds." The lesion features diffusion limitation suggestive of its malignant character, ADC of ca. $0.9 \times 10^{-3} \text{ mm}^2/\text{s}$. In the vicinity of the above focal lesion, also at 2:00 hours, peripherally and in a distance of 12 mm, a suspected intraglandular lymph node is visible, enlarged to ca. 9×7 mm. In level I of left axillary fossa there are several spherical lymph nodes featuring strong non-homogenous contrast enhancement and partial contour blurring; the largest node being ca. 14 mm in size. Two tiny lymph nodes with features as above and

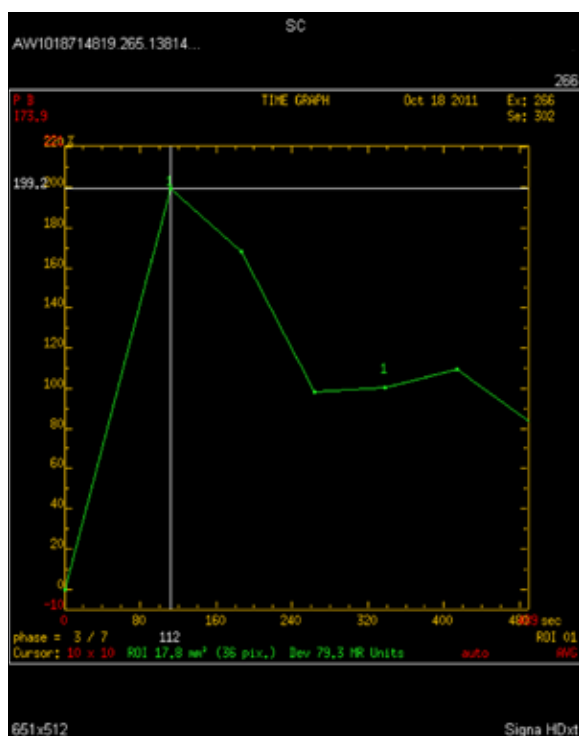


Figure 6. Gain curve type III. Strong, early contrast enhancement of up to 200% within 112 seconds of longitudinal study, strong wash-out effect down to 83%. Carcinoma invasivum NST G2. (WHO 2002: Carcinoma ductale invasivum NOS G2 mammae).

References:

1. Comstock CE, Tartar M: Local staging: imaging options and core biopsy strategies. In: Tartar M, Comstock CE, Kipper MS (eds.), *Breast Cancer Imaging*. Elsevier Urban & Partner, Wrocław, 2010; 79–170
2. Tacikowska M: Magnetic resonance imaging examinations. In: Dziukowa J, Wesolowska E (ed.), *Mammography in diagnostics of breast cancer*. MediPage, Warsaw, 2006; 112–22
3. Comstock CE, Tartar M: Unusual and problematic types of breast cancers: DCIS, intracystic papillary carcinoma, benign-appearing breast cancers, ILC, inflammatory breast cancer and breast cancer in implant cancer. In: Tartar M, Comstock CE, Kipper MS (eds.), *Breast Cancer Imaging*. Elsevier Urban & Partner, Wrocław, 2010; 170–234
4. Wang S: Artifacts. In: Birdwell RL, Morris EA, Wang S, Parkinson BT (eds.), *[Breast. Top 100 Diagnoses]*. MediPage, Warszawa, 2005; 76–78

sized about 6 mm each are also visible in level II – image of suspected meta lesions. Besides the above, both breasts include non-numerous, scattered simple cysts, largest cysts being ca. 10 mm in diameter. No other focal lesions detected. No suspected lymph nodes in level III of left axillary fossa as well as right axillary fossa. Parasternal lymph nodes not visible.

Conclusion: Tu mammae sin.– BI RADS 5. Suspected intraglandular lymph nodes and left axillary fossa level I and II lymph nodes.

Conclusions

Every lab and every radiologist prefer certain templates for summaries and vocabulary being used therein. However, I am positive that standardization of summaries may provide expected information to our clinician colleagues as well as help in the work of our fellow radiologists carrying out subsequent examinations. I hope that this short article will be helpful, particularly to my colleagues who are just starting their practice in the difficult and requiring much patience and courage area of the MRI diagnostics of breast, while providing food for reflection and discussion to more experienced doctors. I will gratefully accept all comments and suggestions.