

Received: 2013.11.12
Accepted: 2013.12.06
Published: 2014.02.09

Authors' Contribution:

- A** Study Design
- B** Data Collection
- C** Statistical Analysis
- D** Data Interpretation
- E** Manuscript Preparation
- F** Literature Search
- G** Funds Collection

Avascular necrosis of the lunate bone (Kienböck's disease) secondary to scapholunate ligament tear as a consequence of trauma – a case study

Dorota Kulhawik^{DEF}, Tomasz Szafaj^{BDE}, Monika Grabowska^{DE}

Department of Imaging Diagnostics, Independent Public Clinical Hospital, Otwock, Poland

Author's address: Dorota Kulhawik, Tomasz Szafaj, Monika Grabowska, Department of Imaging Diagnostics, Independent Public Clinical Hospital, Otwock, Poland, e-mail: zdo@spskgruca.pl

Background:

Avascular necrosis of the lunate bone (Kienböck's disease), is a condition in which lunate bone, loses its blood supply, leading to necrosis of the bone.

There is probably no single cause of Kienböck's disease. Its origin may involve multiple factors, such as the blood supply (arteries), blood drainage (veins), and skeletal variations. Trauma, either isolated or repeated, may possibly be a factor in some cases. This case presented with multifactorial etiology.

Case Report:

In the presented case, a patient with negative ulnar variant had injured her right wrist and presented at an orthopedic clinic due to nonspecific pain 6 months later. An arthro-MRI examination revealed necrosis of the lunate bone, scapholunate ligament tear and coexisting TFCC (triangular fibrocartilage complex) tear.

Conclusions:

Early diagnosis and treatment can prevent progression of necrotic lesions and bone collapse. MRI examination seems to be the key diagnostic method in the early stage of the Kienböck's disease with negative x-ray and CT images. Arthro-MRI examination also allows us to identify the underlying ligamentous injury. In cases of traumatic etiology, an additional CT test enables stating the final diagnosis.

Keywords:

Kienböck's disease • scapholunate ligament • MR/CT arthrography

PDF file:

<http://www.polradiol.com/download/index/idArt/890027>

Background

Avascular necrosis of lunate bone was first described by Robert Kienböck over 100 years ago. It most likely develops as a result of impaired blood supply to the lunate bone and no unequivocal answer has been given as to how such process might occur. Multiple theories on the cause of lunate bone ischemia have been proposed, including two major ones: injury-related (isolated or repeated microinjuries) or unrelated to injury. Possibly, the etiology may be multifactorial [1,2].

Lunate bone receives nutritional supply through the cartilage and supplying vessels.

According to Gelberman, in about 80% of cases vascular supply to the lunate comes from both the dorsal and

palmar surface. Below, we present three types of vessel anastomoses [3] (Figure 1).




Figure 1. Lunate bone vascular supply acc. to Gelberman [2].

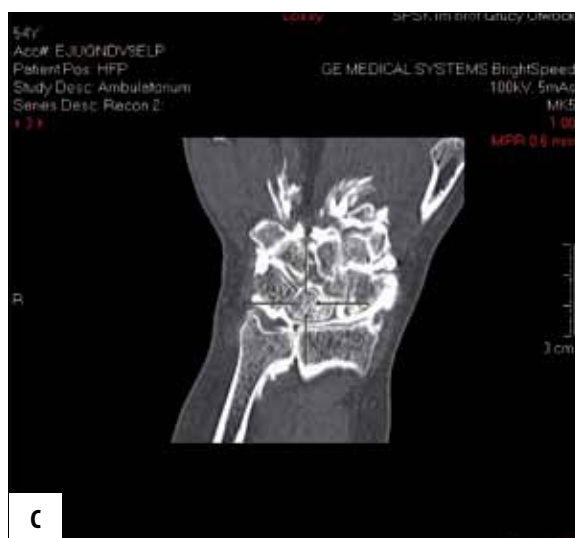
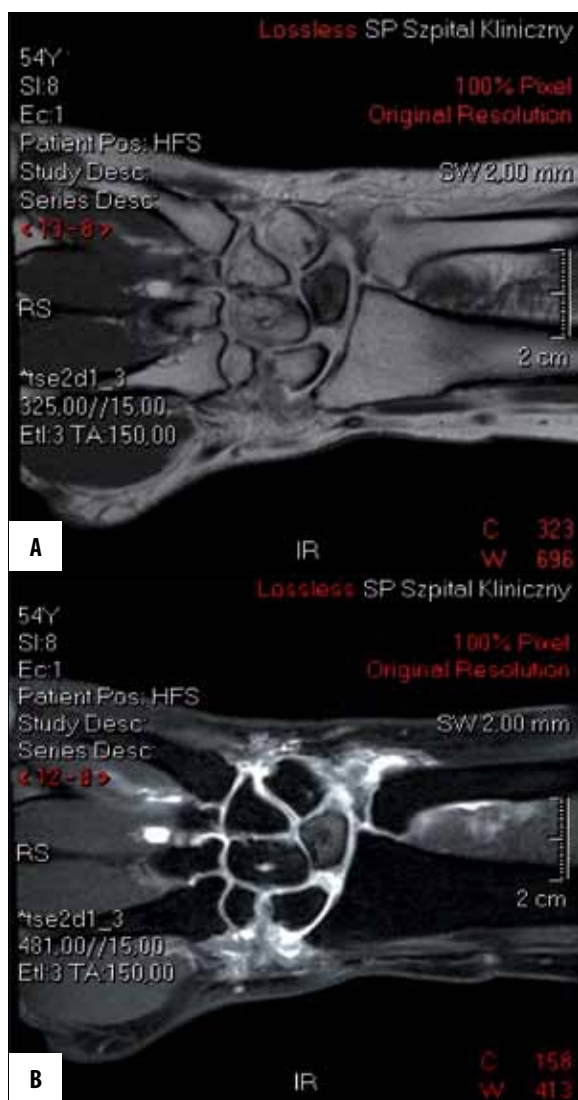
Figure 2. (A) MRI, T2-weighted image. (B) MRI arthrogram, T1-weighted image. (C) CT arthrogram.

X-ray examination demonstrated normal carpal bones and scapholunate dissociation. Negative ulnar variance was noted. Combined MRI/CT arthrography was performed in order to broaden the diagnostics (one intraarticular injection was used).

Under radiological guidance 3 ml of contrast mixture (1% lignocaine, iodine contrast (200 mg/mL), paramagnetic agent (in 1:200 proportion)) was injected into the radiocarpal joint. CT and MRI examinations (T1_tse, T1_fs, T2, PD_fs sequences) were subsequently performed.

Signal attenuation was noted in T1_tse sequences of MRI arthrograms and in T2 sequences revealed signal enhancement in the region of lunate bone, scapholunate ligament tear and associated damage to triangular fibrocartilage complex were visualized.

CT arthrogram confirmed scapholunate ligament dehiscence (interosseous distance – 4 mm), signs of lunate bone sclerosis with retention of its shape and size as well as the possibility of coexisting triangular fibrocartilage complex damage (Figure 2).

Discussion

Kienböck's disease (avascular lunate bone necrosis) most often involves the dominant hand in patients between 20 and 40 years of age. Clinical picture in the initial stages of the disease is nonspecific, as most common symptoms include: pain, edema, and limitation of wrist movement. Disease progression leads to bone destruction and collapse as well as secondary wrist osteoarthritis leading to disruption of its function. Early diagnosis and treatment may prevent progression of necrotic changes and bone collapse.

The most commonly used scale for radiological assessment of the severity of Kienböck's disease is Lichtman's modification (X-ray) of Stahl's classification (CT, MRI), consisting of four stages [5] (Table 1).

In 20% of cases vascular supply may come from one side only – either palmar or dorsal [3,4]. The risk of bone ischemia due to trauma is higher in case of single vascular supply.

A negative ulnar variance is observed in 75% of cases of Kienböck's disease. This predisposition may be related to the pressure exerted on the lunate by uneven articular surface resulting from length discrepancy between the radius and the ulna [2]. Multiple compression fractures and blood flow impairment occur as a result of lunate overloading.

Case Report

A 54-year-old patient was admitted to the Clinic due to chronic pain in the right wrist.

In October 2012 she suffered injury to the right wrist as a result of falling off the stairs. She presented at a doctor's office after 3 weeks and was treated conservatively with immobilization in a plaster cast for 6 weeks. After 6 months from injury severe pain persists on the dorsal side of the right wrist.

Table 1. Radiological assessment of the severity of Kienböck's disease – Lichtman's classification with Stahl's modification [5].

Stage	X-ray	CT	MRI
I	Normal	Normal	Focal/diffuse attenuation of signal from lunate bone in T1-weighted images with bone shape and size preservation
II	Lunate bone sclerosis with preservation of bone shape and anatomical relationships of the wrist	Lunate bone sclerosis with preservation of bone shape and anatomical relationships of the wrist	Progressive attenuation of signal from lunate bone in T1-weighted images (Type I)
IIIA	Noticeable decrease of lunate height, proximal displacement of capitate bone, no scaphoid dislocation	Noticeable decrease of lunate height, proximal displacement of capitate bone, no scaphoid dislocation	Partial destruction of scapholunate ligament with scaphoid rotation
IIIB	Noticeable decrease of lunate height, proximal displacement of capitate bone, scaphoid dislocation	Noticeable decrease of lunate height, proximal displacement of capitate bone, scaphoid dislocation	Total destruction of scapholunate ligament with scaphoid rotation
IV	Total destruction of lunate bone and secondary osteoarthritis of the distal radiocarpal joint	Total destruction of lunate bone and secondary osteoarthritis of the distal radiocarpal joint	IIIA/IIIB and total destruction of lunate bone and secondary osteoarthritis of the distal radiocarpal joint

Literature also proposes that there is a stage 0, only demonstrated in MR, with unremarkable x-ray and CT picture, which is an early indicator of beginning necrosis in the form of overload/post-traumatic, linear fracture in the central portion of the bone. T1-weighted image shows linear signal attenuation [6].

According to the literature data MRI arthrogram is the method of greatest sensitivity and specificity and should be used as a method of choice in the presence of uncertain post-traumatic clinical picture. The case described here proves that this method might be inadequate in stage II and III Kienböck's disease.

Ambiguous MRI picture (attenuation of lunate signal in T1-weighted images) requires differentiation between stage II or III Kienböck's disease and traumatic intraosseous contusion (correlating with history of trauma in this case). Broadening the diagnostics to include CT examination provides such possibility.

Combination of those studies allows for establishing the final diagnosis.

References:

- Kienböck R: Concerning traumatic malacia of the lunate and its consequences: Degeneration and compression fractures. *Clin Orthop Rel Res*, 1980; 149: 4-8
- Greenspan A: Diagnostyka obrazowa w ortopedii. 2011, wyd 2 PL; 7; 206-9 [in Polish]
- Gelberman RH, Panagis JS, Teleisnik J: The arterial anatomy of human carpus Part I: The extraosseous vascularity, *J Hand Surg*, 1983; 8: 367
- Lamas C: The anatomy and vascularity of the lunate: considerations applied to Kienböck's disease. *Chir Main*, 2007; 26: 13-20
- Lichtman DM, Degnan GG: Staging and its use in the determination of treatment modalities for Kienböck's disease, *Hand Clin*, 1993; 9: 409-16
- Mark H: Awh, Kienböck's Disease, *MRI Web Clinic*-April 2013

Conclusions

MRI examination seems to be the key test in the diagnosis of early stages of Kienböck's disease in the presence of unequivocal x-ray and CT examinations. When combined with MRI arthrography, it allows for validation of coexisting damage to ligamentous apparatus, resulting in minimization of surgical intervention and improving prognosis.

In case of traumatic etiology, MRI study alone may be equivocal. Complementing MRI examination with a CT study enables conducting comprehensive differential diagnosis and stating the final diagnosis.

Early application of a method characterized by high sensitivity and specificity, despite its high cost, allows for avoiding the necessity of performing additional diagnostic and medical procedures and, in fact, may reduce the cost and time of treatment.