



Received: 2015.07.16
Accepted: 2015.09.22
Published: 2015.12.09

Authors' Contribution:

- A** Study Design
- B** Data Collection
- C** Statistical Analysis
- D** Data Interpretation
- E** Manuscript Preparation
- F** Literature Search
- G** Funds Collection

Jejunal Diverticulosis Presented with Acute Abdomen and Diverticulitis Complication: A Case Report

Nurdan Fidan^{1AEE}, Esra Ummuhan Mermi^{1AEE}, Mehtap Beker Acay^{2EE},
Muammer Murat^{1BD}, Ethem Zobaci^{3ED}

¹ Department of Radiology, Hitit University, Training and Research Hospital, Corum, Turkey

² Department of Radiology, Afyon Kocatepe University, Faculty of Medicine, Afyonkarahisar, Turkey

³ Department of General Surgery, Hitit University Training and Research Hospital, Corum, Turkey

Author's address: Nurdan Fidan, Department of Radiology, Hitit University Training and Research Hospital, Corum, Turkey,
e-mail: kocak_nurdan@yahoo.com

Summary

Background:

Jejunal diverticulosis is a rare, usually asymptomatic disease. Its incidence increases with age. If symptomatic, diverticulosis may cause life-threatening acute complications such as diverticulitis, perforation, intestinal hemorrhage and obstruction. In this report, we aimed to present a 67-year-old male patient with jejunal diverticulitis accompanying with abdominal pain and vomiting.

Case Report:

A 67-year-old male patient complaining of epigastric pain for a week and nausea and fever for a day presented to our emergency department. Ultrasonographic examination in our clinic revealed diverticulum-like images with thickened walls adjacent to the small intestine loops, and increase in the echogenicity of the surrounding mesenteric fat tissue. Contrast-enhanced abdominal computed tomography showed multiple diverticula, thickened walls with showing contrast enhancement and adjacent jejunum in the left middle quadrant, increased density of the surrounding mesenteric fat tissue, and mesenteric lymph nodes. The patient was hospitalized by general surgery department with the diagnosis of jejunal diverticulitis. Conservative intravenous fluid administration and antibiotic therapy were initiated. Clinical symptoms regressed and the patient was discharged from hospital after 2 weeks.

Conclusions:

In cases of diverticulitis it should be kept in mind that in patients with advanced age and pain in the left quadrant of the abdomen, diverticular disease causing mortality and morbidity does not always originate from the colon but might also originate from the jejunum.

MeSH Keywords:

Diverticulitis • Jejunal Diseases • Multidetector Computed Tomography • Ultrasonography

PDF file:

<http://www.polradiol.com/abstract/index/idArt/895354>

Background

Diverticula while predominantly localized in the colon, might be found in any part of the digestive tract beginning from the esophagus [1]. Small intestine diverticula are very rare and the incidence ranges from 0.06% to 1.3% [2]. The most known diverticulum, Meckel diverticulum, is the most common congenital anomaly of the gastrointestinal system [3]. Except Meckel, other small intestine diverticula are very rarely acquired diverticula. They are most frequently seen in the proximal jejunum and the prevalence of diverticula in the proximal jejunum, distal jejunum and ileum are 75%, 20% and 5% respectively [4]. Prevalence increases with

age and reaches its peak in the 6th and 7th decades of life. Jejunal diverticulum is usually asymptomatic; however, it may cause abdominal pain, nausea, vomiting and malabsorption. It may also lead fatal acute complications such as perforation, intestinal hemorrhage and obstruction [5]. Early diagnosis is important to prevent the development of complications and thus avoid surgery.

Case Report

A 67-year-old male patient with the complaints of epigastric pain for a week and nausea and fever for a day presented to our emergency department. At physical examination,

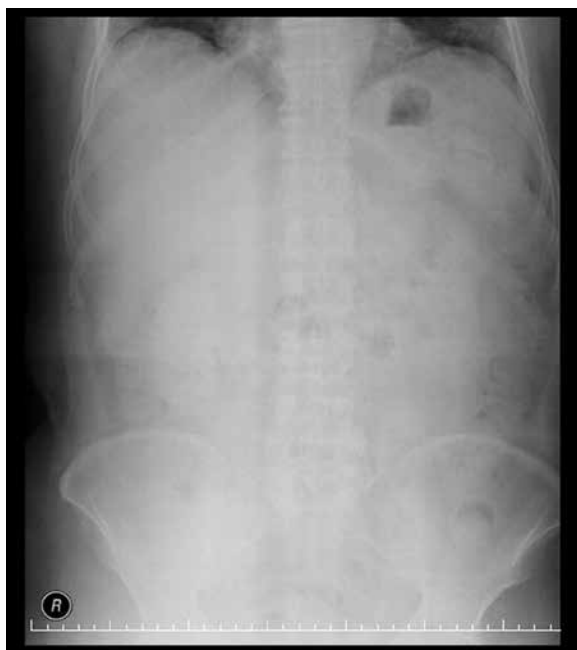

Figure 1. Abdominal plain radiography; there are no specific findings.

sensitivity in the left upper quadrant of the abdomen without defence and rebound was found. Laboratory investigations revealed high sedimentation, C-reactive protein (CRP), and leukocytosis. On upright plain abdominal radiography there was no evidence of free abdominal air, air-fluid levels or dilated intestinal loops (Figure 1).

Ultrasonographic examination in our clinic revealed diverticulum-like images with thickened walls adjacent to the

small intestine loops, and increase in the echogenicity of the surrounding mesenteric fat tissue (Figure 2). Contrast-enhanced abdominal computed tomography (CT) investigations showed multiple diverticula, the largest one being 43×23 mm in size, associated with jejunal loops, and contrast-air-fluid levels, 3 adjacent diverticula with thickened walls, showing contrast enhancement adjacent to the jejunum in the left middle quadrant, increased density of the surrounding mesenteric fat tissue and mesenteric lymph nodes (Figures 3–5). In this location and in the abdomen, no intraperitoneal free air or fluid suggestive of perforation were observed. No diverticulum was detected in colonic loops. The patient was hospitalized in the service of the general surgery with the diagnosis of jejunal diverticulitis and conservative intravenous fluid administration and antibiotic therapy were initiated. Clinical symptoms regressed and 2 weeks later the patient was discharged from hospital. Four weeks later control CT evaluation showed no extra findings suggesting Crohn disease, neoplasm or other pathologies other than diverticulosis (Figures 3–5).

Discussion

Small intestine diverticula other than Meckel are acquired. Pseudo pulsion diverticula, presenting mucosa and serosa in the pouch wall are most commonly found in the jejunum [6]. Jejunal diverticulosis is a rare, usually asymptomatic disease with increasing incidence with aging. Jejunal diverticulitis arises as a complication of diverticulosis. Clinical presentation is characterized with pain in the upper left quadrant of the abdomen, nausea, vomiting as well as fatal complications such as perforation, hemorrhage and obstruction may occur in severe cases [5]. In

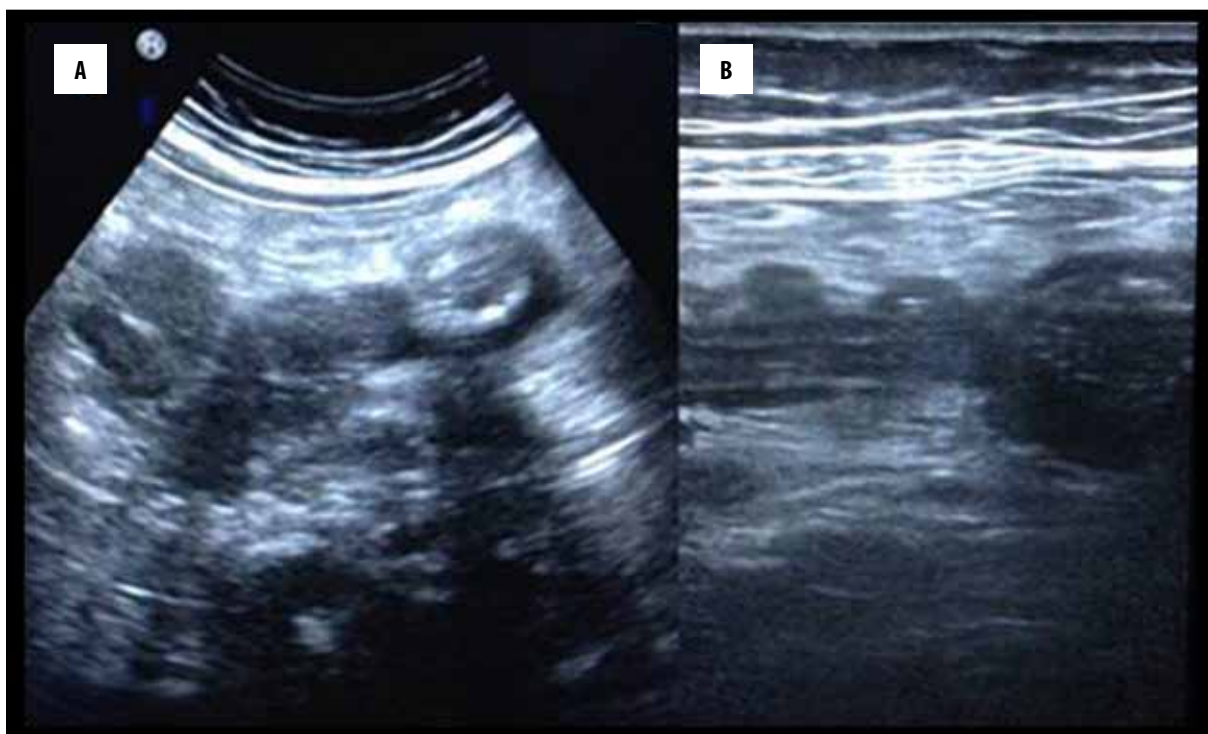


Figure 2. A 67-year-old man with jejunal diverticulitis (A, B). Abdominal US demonstrates thickened hypoechoic irregular formations with hyperechoic centre, connected to the jejunum and suggestive of diverticula.

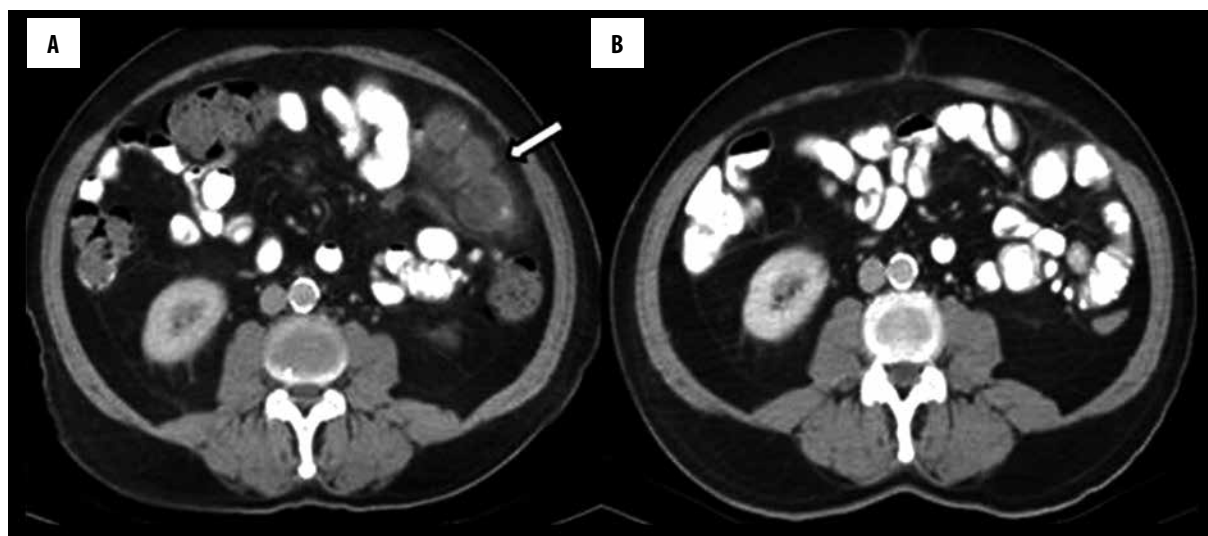


Figure 3. Contrast-enhanced abdominal CT, with oral contrast medium: axial images; (A) A segment of the jejunum with three diverticula is observed, with wall thickening and increased density of the surrounding mesenteric fat tissue (arrow); (B) Control CT axial image 4 weeks after healing at the same level of the abdomen showed that diverticulitis findings were regressed.

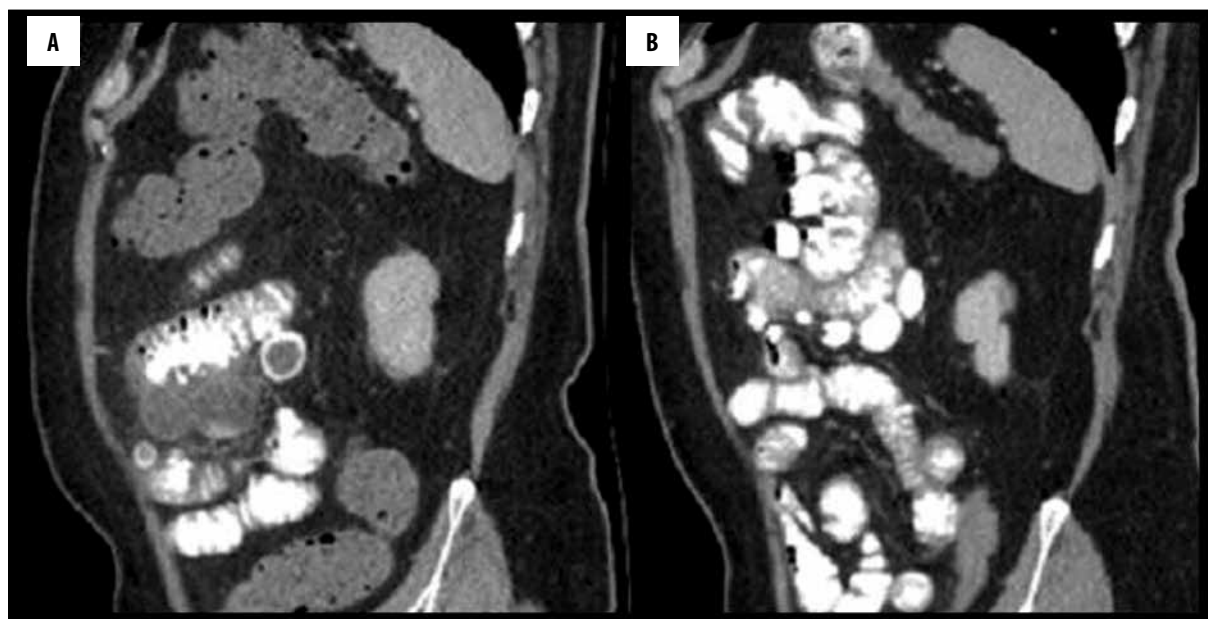


Figure 4. Contrast-enhanced abdominal CT, with oral contrast medium: sagittal reformatted images. Multiple diverticula are observed at the jejunum (A, B); (A) There is a segment of the jejunum with diverticula involved by an inflammatory process; (B) Control CT after medical treatment at the same level of the abdomen showed that diverticulitis findings were regressed.

our case, a male patient with advanced age had pain in the upper left quadrant of the abdomen, fever, nausea, and laboratory test results revealed inflammatory findings.

In diagnosis of diverticulitis and to demonstrate the complications, upright plain film of the abdomen, ultrasonography, and CT are used [7]. Upright plain film of the abdomen can give information about air-fluid levels, existence of free air and dilated intestinal loops in the abdomen. Ultrasound is an inexpensive and convenient imaging test that can be used as the first screening method for acute abdominal pain. It can reveal thickening of the walls of the intestinal loops in the upper left quadrant, increased echogenicity in the surrounding fat tissues, and diverticula.

Free fluids may also accompany to the findings. CT imaging shows ovoid diverticula containing contrast-air-fluid contents in the jejunal wall. In case of diverticulitis, thickening of the walls of the jejunum and the diverticulum, increased density of the surrounding mesentery resulting from the inflammation and mesenteric lymph nodes may be observed. If perforation occurs, intraperitoneal free air and fluid, if inflammation develops, loculated collection with high density and extraluminal air neighboring intestinal loops may be detected.

In our case no positive finding could be observed on direct abdominal radiography. US imaging revealed loops with thickened walls suggesting diverticulitis in the upper left

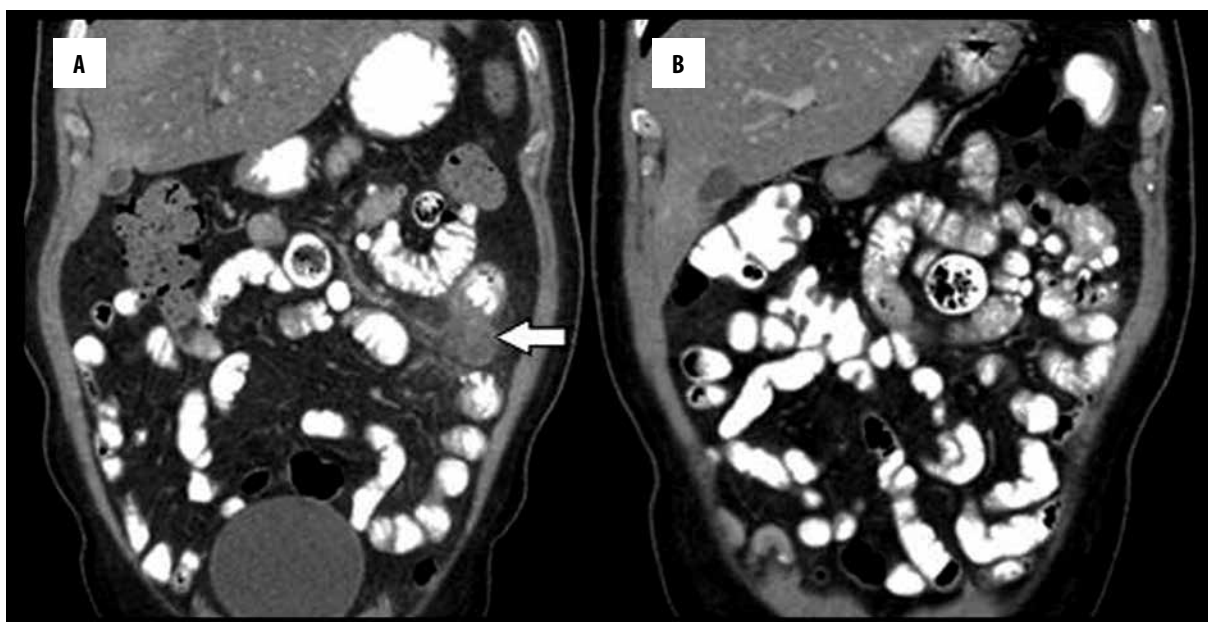


Figure 5. (A) Abdominal CT coronal reformatted images demonstrated the inflamed diverticulum (arrow); (B) Control CT 4 weeks after the medical therapy showed a jejunal diverticulum and no other pathological processes.

quadrant and CT examination revealed multiple diverticula in the jejunum and diverticulitis signs in the left middle quadrant (Figures 1–5).

In the literature, complicated jejunal diverticulitis cases with perforation, abscess or obstruction on and imaging findings comprise of localized mass, extraluminal air and loculated collections were reported [8–11]. Reports on early-diagnosed cases with localized inflammation are rare in the literature. As in our case, early diagnosis and prompt treatment decreases the complication incidence and the need for surgical interventions [8].

Small intestinal diverticulitis presenting with acute abdomen generally requires surgical treatment, whereas in cases with local inflammation, and in the absence of complications such as hemorrhage and perforation,

conservative treatment can be the treatment of choice [11]. While small intestinal diverticulitis causes nonspecific symptoms, perforated neoplasia, foreign body perforation, Crohn's disease and colonic diverticulitis should be considered in the differential diagnosis [12].

Conclusions

The diagnosis of diverticular disease should be kept in mind in patients with advanced age and pain in the left quadrant of the abdomen. Also, it should be noted that diverticular disease causing mortality and morbidity does not always originate from the colon but it may also originate from the jejunum. Ultrasound is the proper imaging test that can be used as the first screening method for acute abdominal pain. In order to avoid development of complications and thus to avoid surgery, prompt diagnosis is essential.

References:

- Ackerman NB: Perforated diverticulitis of the terminal ileum. *Am J Surg*, 1974; 128(3): 426–28
- Staszewicz W, Christodoulou M, Proietti S, Dermartines N: Acute ulcerative jejunal diverticulitis: Case report of an uncommon entity. *World J Gastroenterol*, 2015; 200: 6265–67
- Kamal E, Bani-Hani, Nawaf J, Shatnawi: Meckel's diverticulum: Comparison of incidental and symptomatic cases. *World J Surg*, 2004; 28(9): 917–20
- Singal R, Gupta S, Airon A: Giant and multiple jejunal diverticula presenting as peritonitis a significant challenging disorder. *J Med Life*, 2012; 5: 308–10
- Woods K, William E, Melvin W, Sharp K: Acquired jejunoileal diverticulosis and its complications: A review of the literature. *Am Surg*, 2008; 74: 849–54
- Dahnert W: *Radiology Review Manual*. 5th ed. Lippincot Williams & Wilkins, Philadelphia, 2003; 838
- Grana L, Pedraja I, Mendez R, Rodriguez R: Jejuno-ileal diverticulitis with localized perforation: CT and US findings. *Eur J Radiol*, 2009; 71(2): 318–23
- Macari M, Faustb M, Liangc H, Pachter HL: CT of jejunal diverticulitis: imaging findings, differential diagnosis, and clinical management. *Clin Radiol*, 2007; 62: 73–77
- França M, Certo M, Silva D et al: Elderly patient with acute, left lower abdominal pain: perforated jejunal diverticulitis. *Eur Radiol*, 2010; 20: 2541–45
- Coulier B, Maldague P, Bourgeois A, Broze B: Diverticulitis of the small bowel: CT diagnosis. 2007; 32(2): 228–33
- Veen M, Hornstra BJ, Clemens CH et al: Small bowel diverticulitis as a cause of acute abdomen. *Eur J Gastroenterol Hepatol*, 2009; 21: 123–25
- Macari M, Balthazar EJ: Review: Computed tomography of bowel wall thickening: significance and pitfalls of interpretation. *Am J Roentgenol*, 2001; 176: 1105–16