Signature: © Pol J Radiol, 2015; 80: 499-502
DOI: 10.12659/PJR.895126

Polish Journal of Radiology
www.PolRadiol.com
CASE REPORT

Received: 2015.06.24
Accepted: 2015.07.14
Published: 2015.11.09

Authors' Contribution:
A Study Design
B Data Collection
C Statistical Analysis
D Data Interpretation
E Manuscript Preparation
F Literature Search
G Funds Collection

Large Gastric Perforation Sealed by Splenic Lysis: Emphasis on Indirect Signs – A Rare Case Report

Lalit Garg[ABCDEF], **Mansi Jain**[ABCDEF], **Kishor Taori**[AEF], **Ajinky Patil**[E], **Anand Hatgaonkar**[E], **Jawhar Rathod**[E], **Swenil Shah**[E], **Darshan Patwa**[CE], **Akshat Kasat**[BE]

Department of Radiodiagnois, Government Medical College, Nagpur, India

Author's address: Lalit Garg, Department of Radiodiagnosis, Government Medical College, Nagpur, India, e-mail: drlalitgarg8@gmail.com

Summary

Background: Gastric perforation is a life-threatening condition, requiring early and reliable discovery. The delay before surgical treatment is a strong determinant of poor outcome, associated complications and hospitalization costs. By using ultrasound and multi-detector computed tomography (MDCT) we can further evaluate undiagnosed cases of silent gastric perforations presenting with non-specific acute abdomen.

Here we bring forth the role of a radiologist in cases of perforation which present with indirect signs involving the organs forming the stomach bed, like the spleen, pancreas and kidney.

Case Report: A 25-year-old male patient presented with an acute onset of severe upper abdominal pain radiating to the back and vomiting. MDCT of the abdomen was done which revealed atrophic pancreas with organized collection in the sub-capsular location indenting the superior pole of the left kidney. Spleen was not visualized. The most striking imaging finding in that case was destruction of the splenic parenchyma with protrusion of the remaining tissue into the stomach lumen. The hypothesis behind this was a cascade of events which started with gastric perforation, spillage of highly destructive gastric juice over the stomach bed and finally becoming silent with rapid sealing of the defect by the omentum and the spleen.

Conclusions: Acute abdomen is a diagnostic challenge to a clinician and radiologist with gastric perforation being a great mimicker of other urgent abdominal pathologies. To avoid a delayed diagnosis or a misdiagnosis, familiarity with typical and atypical imaging features is essential as in our case of splenic lysis. It acted as the 2nd policeman and provided a great clue to solve the diagnostic dilemma.

MeSH Keywords: **Abdomen, Acute • Multidetector Computed Tomography • Pancreatitis • Peptic Ulcer Perforation • Spleen**

PDF file: http://www.polradiol.com/abstract/index/idArt/895126

Background

Gastric perforation is a life-threatening condition, requiring early and reliable discovery, because it usually needs surgical intervention. Ulcer perforation incidence during the last decades has declined in the young and in men, and it has risen among the elderly and in women [1]. The most common cause of gastric perforation is peptic ulcer. The delay before surgical treatment is a strong determinant of poor outcome, associated complications and hospitalization costs.

It is most common in the first part of the duodenum and along the lesser curvature [2]. Erect X-ray of the chest and abdomen is the first line of investigation but it is useful in 75–80% of cases [1].

By the use of ultrasound and multi-detector computed tomography (MDCT) we can further evaluate undiagnosed cases of silent gastric perforations presenting with non-specific acute abdomen.

Table 1. Direct and indirect signs of gastric perforation on MDCT.

Direct signs	Indirect signs
• Pneumoperitoneum • Peritoneal collection with echogenic contents • Visualisation of a defect within the gastric wall • Contrast leak from the site of perforation	• Pancreatitis • Perinephric collection • Lesser sac collection • Loculated collection in the perigastric region • Splenic parenchymal destruction • Wall irregularity with visualisation of the mesentery or omentum adhered to the region • Extensive intra-abdominal fat stranding

Figure 1. X-ray of the abdomen and lower thorax not showing any significant abnormality.

Not every case presents with free intraperitoneal air or contrast leak (commonly used signs to diagnose any gastrointestinal perforation).

Here we bring forth the role of the radiologist in guiding the surgeon to make valuable decisions in cases of perforation which present with indirect signs (Table 1) involving the organs forming the stomach bed, i.e. the spleen, pancreas and kidney.

Case Report

A 25-year-old male patient presented in the emergency room with a history of an acute onset of a severe upper abdominal pain radiating to the back and vomiting following binge alcohol intake. On clinical evaluation there was

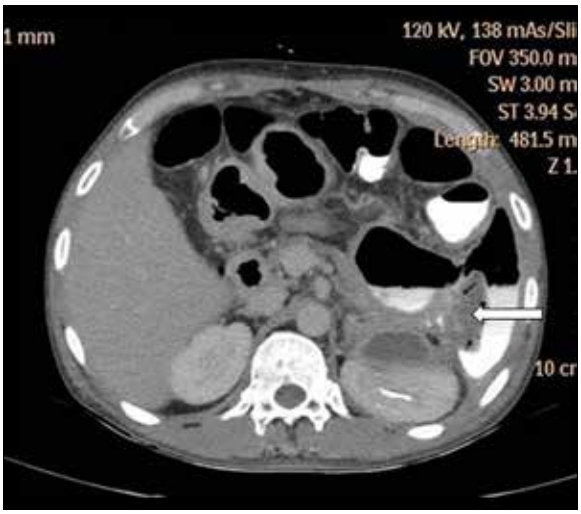

Figure 2. CT of the abdomen; axial image showing an atrophic pancreas with calcifications in the tail region.

tenderness in the epigastrium and the left hypochondrium. There was no h/o fever, hematemesis, jaundice, constipation, previous surgery or similar episodes in the past.

Clinically provisional diagnosis of acute pancreatitis was kept. Routine blood investigations along with serum lipase were done which revealed mildly elevated lipase levels, i.e. 300 U/L (normal range, 80–140 U/L).

X-ray of the chest and abdomen (Figure 1) was carried out which did not give any diagnostic clue. USG of the abdomen was performed which revealed multiple coarse calcifications in the pancreatic head (body and tail was obscured) with intra-abdominal fat stranding. The spleen was not visualised in the splenic fossa with mild collection in the left anterior para-renal space. The rest of the solid organs were normal. No visualisation of the spleen was viewed with great suspicion but no reason could be found behind it (except that the spleen could be atrophic or obscured by bowel gases). Even patient's symptoms could not be related to it.

On the basis of a clinical, laboratory and ultrasound correlation, the patient was managed conservatively for 3 days considering the most likely diagnosis of acute or chronic pancreatitis. As the symptoms worsened, clinical and ultrasound diagnosis was challenged and the patient was advised to undergo MDCT of the abdomen for further evaluation.

Abdominal MDCT was carried out and revealed atrophic pancreas with calcifications in tail region Figure 2), well-defined organized collection in the sub-capsular location indenting the superior pole of the left kidney (Figure 3) with extensive fat stranding in the perinephric space and peripancreatic region. The spleen was not visualized in the splenic fossa. However, the splenic artery was noted arising from the celiac trunk coursing along the tail of the pancreas up to a soft tissue density structure in relation to the posterior wall of the stomach measuring approximately 3.3×3×4 cm (Figure 4). The splenic vein was visualized only near the portal vein formation. The soft tissue density lesion showed moderate enhancement surrounded by

Figure 3. CT of the abdomen; coronal image showing a well-defined organized collection in the subcapsular location indenting the superior pole of the left kidney.

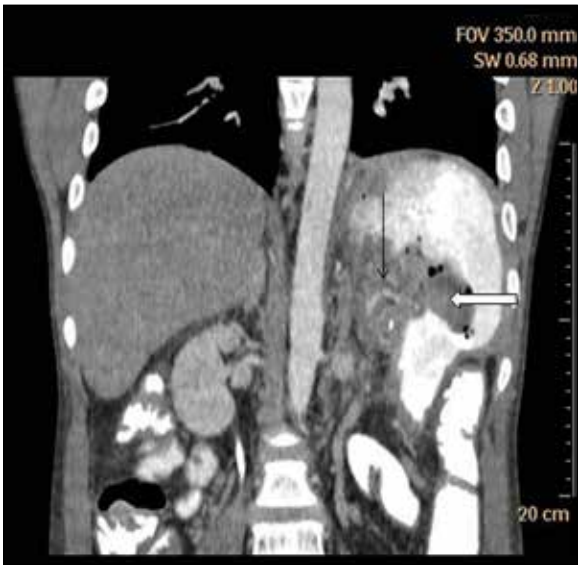

Figure 4. CT of the abdomen; coronal image showing the splenic artery (black arrow) arising from the celiac trunk coursing along the tail of the pancreas up to a soft tissue density structure (thick white arrow) in relation to the posterior wall of the stomach.

non-enhancing collection and a rim of air foci. It was protruding within the lumen of the stomach (Figures 5, 6). The surrounding stomach wall appeared thickened and oedematous with perigastric fat stranding. A soft-tissue structure protruding within the stomach lumen was the spleen as the splenic artery could be traced up to it with the tail of the pancreas in relation to it. The most striking imaging finding in this case which later led us to the final diagnosis was destruction of the splenic parenchyma with protrusion of the remaining tissue into the stomach lumen.

The hypothesis behind this was a cascade of events which started with gastric perforation, spillage of highly

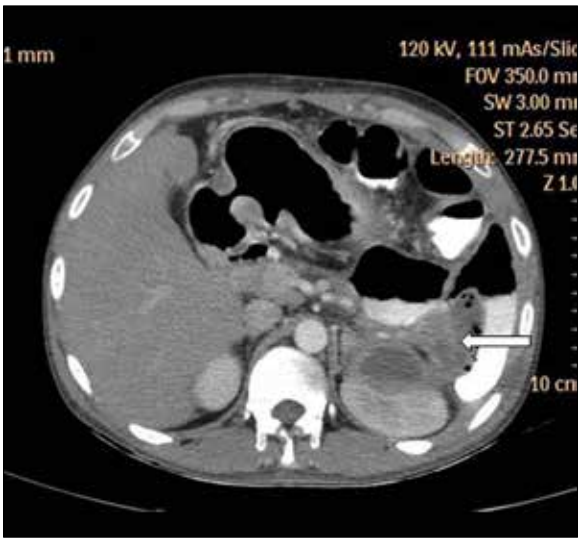

Figure 5. CT of the abdomen; axial section showing a soft-tissue density lesion protruding within the lumen of the stomach, showing moderate enhancement and surrounded by non-enhancing collection with a rim of air foci.

Figure 6. CT of the abdomen; sagittal section showing a soft-tissue density lesion (thick white arrow) protruding within the lumen of the stomach (black arrow) showing moderate enhancement and surrounded by non-enhancing collection with a rim of air foci.

destructive gastric juice over the stomach bed and finally becoming silent with rapid sealing of the defect by the omentum and the spleen.

The spleen was destroyed by continuous contact with gastric contents; however, perforation was diagnosed before it could give away. So the diagnosis of gastric perforation sealed by the spleen was kept.

The patient was operated on emergency basis with the following intra-operative findings – a) large rent along the greater curvature which was sealed by a soft-tissue structure and omentum b) bulky oedematous mesentery with collection in the right paracolic gutter.

Discussion

Gastric perforation though a common cause of acute abdomen [2] is sometimes under-diagnosed requiring a great degree of suspicion both clinically and radiologically. Radiologist plays a critical role in determining the sequential steps and investigation of choice in particular situation.

The perforation can occur freely into the abdominal cavity or sealed by adhesions of created pockets [2]. Spilled contents consist of air, liquid of gastric and duodenal secretion, food and bacteria. The free air gives rise to a characteristic radiographic sign of hollow viscous perforation. As gastric contents are acidic they cause chemical peritonitis. If they are sealed they give rise to localised collections.

Radiological findings in a typical gastric perforation are pneumoperitoneum on X-ray. USG is an initial modality advised for evaluating various acute abdominal cases. It would reveal intrapritoneal fluid collection (with air foci and echoes within), extensive mesenteric and omental fat stranding.

MDCT is very sensitive in detecting free intraperitoneal air after perforation when X-ray is negative or inconclusive. CT is also better in detecting fluid collections located in the lesser sac and retroperitoneum. In suspected cases of perforation where free air is not visible on classic native scans, we can give non-ionic contrast to accurately diagnose and localise the site. In cases where no obvious evidence of perforation could be seen or demonstrated, other signs in vicinity could give us a clue which includes sealing of a defect by stomach bed structures and omentum, splenic destruction, pancreatitis and collection in peritoneal spaces. Specific radiological signs of penetration were also described as loss of fascial planes between the stomach and pancreas with bands of soft-tissue density connecting these structures [3]. So in cases where X-ray and ultrasound findings are uncertain, we should take the help of MDCT.

Conclusions

Acute abdomen is a diagnostic challenge to clinicians and radiologists with gastric perforation being a great mimicker of other urgent abdominal pathologies. To avoid delayed diagnosis or misdiagnosis, familiarity with typical and atypical imaging features is essential as in our case of splenic lysis. It acted as the 2nd policeman apart from the omentum and provided a great clue to solve the diagnostic dilemma.

References:

1. Svanes C: Trends in perforated peptic ulcer: incidence, etiology, treatment, and prognosis. World J Surg, 2000; 24(3): 277–83
2. Sofić A, Bešlić Š, Linceder L, Vrcić D. Early radiological diagnostics of gastrointestinal perforation. Radiol Oncol, 2006; 40(2): 67–72
3. Glick SN, Levine MS, Teplick SK, Gasparaitis A: Splenic penetration by benign gastric ulcer: preoperative recognition with CT. Radiology, 1987; 163(3): 637–39