



Received: 2015.05.19
Accepted: 2015.05.24
Published: 2015.08.21

Authors' Contribution:

- A** Study Design
- B** Data Collection
- C** Statistical Analysis
- D** Data Interpretation
- E** Manuscript Preparation
- F** Literature Search
- G** Funds Collection

Congenital Epulis: A Rare Benign Jaw Tumour in a 2-Day-Old Male Baby

Rohan Bhoil^{1ABCDE}, Rohit Bhoil^{2ABCDE}, Rajesh Chopra^{3DEF}, Manika Sharma^{4CDEF},
Kewal Mistry^{5DE}

¹ Department of Dental Surgery, HP Government Dental College, Shimla, India

² Department of Radiology, Dr. Rajendra Prasad Government Medical College, Kangra, India

³ Department of Surgery, Indira Gandhi Medical College, Shimla, India

⁴ Department of Pathology, Indira Gandhi Medical College, Shimla, India

⁵ Department of Radiodiagnosis, Dr. Rajendra Prasad Government Medical College, Kangra, India

Author's address: Rohit Bhoil, Department of Radiology, Dr. Rajendra Prasad Government Medical College, Kangra, India,
e-mail: rohitbhoil@gmail.com

Summary

Background:

Congenital epulis is a rare benign jaw tumor. It is a reactive or degenerative lesion having a mesenchymal origin; presenting as an obvious mass arising from the gingival mucosa of the maxilla or mandible, presenting in neonates. Its etiology, histopathogenesis and natural history are still not well established. It is seen usually in the female gender and mostly involves the maxillary alveolar ridge.

Material/Methods:

We report a case of a 2.7 kg male baby born with growth on his mandibular ridge which was excised and was proved to be epulis on histopathology.

Results:

Congenital epulis is often misdiagnosed before surgery because of its rarity and a lack of awareness of the condition by clinicians. It is important for the attending pediatricians, pediatric surgeon to be aware of this rare but benign congenital tumor.

Conclusions:

Congenital epulis is often misdiagnosed before surgery because of its rarity and a lack of awareness of the condition by clinicians. As the clinical presentation of this congenital tumor can be distressing due to its size and aggressive appearance, it is important for the attending pediatricians, pediatric surgeon to be aware of this rare but benign congenital tumor.

MeSH Keywords:

Congenital Abnormalities • Gingival Neoplasms • Granuloma, Giant Cell • Ultrasonography • Ultrasonography, Doppler

PDF file:

<http://www.polradiol.com/abstract/index/idArt/894698>

Congenital epulis also known as 'Neumann's Tumour' is a rare benign jaw tumour of neonates, first described by Neumann in 1871, hence its alternative name [1]. It is a reactive or degenerative lesion of mesenchymal origin. It presents as an obvious mass arising from the gingival mucosa of the maxilla or mandible, found in neonates, although prenatal diagnosis with ultrasound was reported as early as 26 weeks gestation [2,3].

Its aetiology, histopathogenesis and natural history are still not well established. Dash et al. [4] reported that congenital epulis is predominantly seen in females, being 10 times

more common than in males, with a 3:1 incidence at maxillary alveolar sites. Due to its high incidence in females, an endogenous (intrauterine) hormonal stimulus was proposed but this theory fell out of favour due to the absence of receptors for estrogen and progesterone. The lesions occur sporadically and no familial tendencies have been described [3]. Usually congenital epulis presents as a single lesion; however, it may be multiple in 10% of the cases [5]. This lesion is often pedunculated, flesh-pink colored, firm, with a smooth or lobulated surface, ranging in size from a few mm to up to 9 cm. In cases with large or multiple lesions, mechanical oral obstruction can occur, impairing

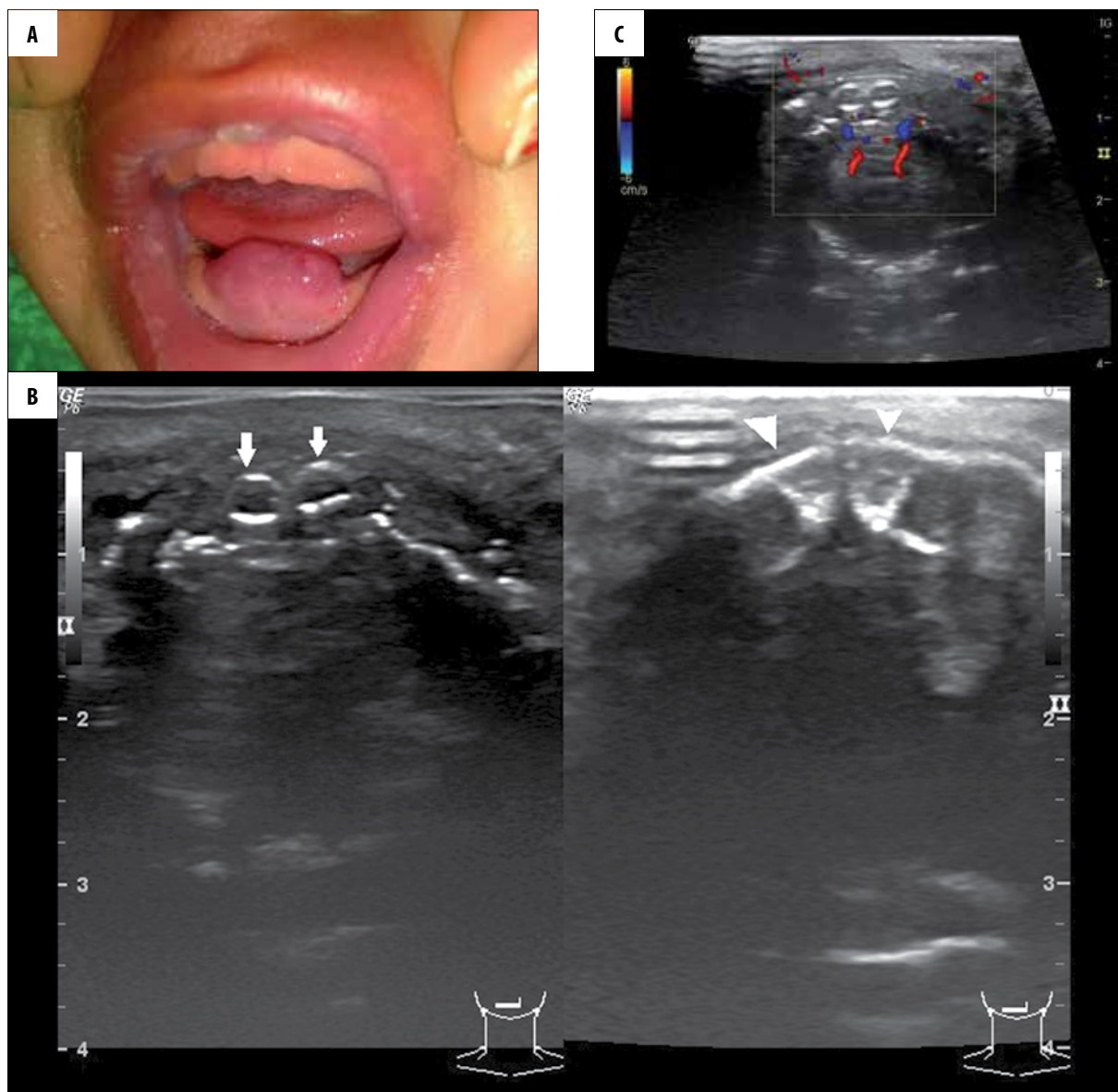


Figure 1. Congenital epulis in a 2-day-old male infant. (A) Lobulated mass arising from the lower jaw; (B) gray scale ultrasound image of the mass showing an encapsulated hypoechoic area containing two well-defined cystic masses in the mandibular alveolar ridge (arrows); inferiorly the underlying teeth buds were seen (arrowhead); (C) no flow was seen on color Doppler imaging; (D) histopathological examination of the excised tissue revealed layers of closely packed polygonal cells with abundant eosinophilic granular cytoplasm and small nuclei.

fetal deglutition and neonatal respiratory efforts, resulting in polyhydramnios prenatally or respiratory impairment postnatally [2]. Diagnosis is generally based on clinical grounds alone, although difficulties may arise when the size of the lesion is small, or the index of suspicion is low. Although few cases of spontaneous regression have been reported [6,7], the recommended treatment is surgical excision under local or general anaesthesia [8], but surgery should not be radical to minimize the danger of damaging underlying alveolar bone and developing tooth buds [9].

There are no reports of recurrence, or malignant change. The lesion rarely interferes with future dentition.

We report a case of a 2.7-kg neonate born at term by vaginal delivery at a peripheral centre. He was referred to our hospital due to the presence of a lobulated swelling in his lower jaw. According to the mother of the baby, the lesion caused difficulty in feeding but did not interfere with respiration. On examination, an approximately 3×2-cm bilobulated, smooth, pink-coloured soft-tissue mucosal swelling was arising from the mandibular alveolar ridge (Figure 1A). The mass was firm in consistency, non-compressible and was not tender on palpation. Adjacent tissues appeared normal on examination. No history of fever was present.

There was history of similar but smaller, solitary mass measuring 1×1 cm arising from the maxillary incisor region in patient's elder sister when she was born. However, unlike the present case, it did not cause any problems and regressed spontaneously at the age of 5 months with normal subsequent dentition.

As the mass in the present case was causing difficulty in feeding, the parents opted against observation and wanted the mass to be removed as soon as possible. Accordingly surgical excision was planned but to rule out any vascularity, an ultrasound was advised. The ultrasound was done using an 11-MHz linear probe, placing the transducer externally over the chin of the patient. It revealed presence

of an encapsulated hypoechoic area containing two well-defined cystic masses (Figure 1B) measuring approximately 0.5×0.7 cm each in the mandibular alveolar region. No vascularity was noted on color Doppler flow imaging (Figure 1C). On sweeping the probe slightly inferior to these, the underlying buds of incisor teeth were visualised (Figure 1B). Subsequently the mass was excised under general anaesthesia. Post-operative recovery was uneventful and the child was discharged after two days. Histopathological examination of the excised tissue revealed layers of closely packed polygonal cells with abundant eosinophilic granular cytoplasm and small nuclei (Figure 1D). This microscopic appearance was consistent with that of congenital epulis similar to the granular cell tumours due to which it is also known as gingival granular cell tumour of the newborn. However, congenital epulis is negative when immunostained with S-100 protein compared to adult granular cell tumours, which are derived from Schwann cells [10].

Presently the child is 10 months old, having normal eruption of teeth with no complaints.

Congenital epulis is often misdiagnosed before surgery because of its rarity and a lack of awareness of the condition by clinicians. As the clinical presentation of this congenital tumour can be distressing due to its size and aggressive appearance, it is important for the attending paediatricians and paediatric surgeons to be aware of this rare but benign congenital tumour.

References:

1. Neumann E: Ein fall von congenitaler epulis. *Arch Heilk*, 1871; 12: 189-90
2. Shaw L, Al-Malt A, Carlan SJ et al: Congenital epulis: three-dimensional ultrasonographic findings and clinical implications. *J Ultrasound Med*, 2004; 23: 1121-24
3. Dzieniecka M, Komorowska A, Grzelak-Krzyszowska A, Kulig A: Multiple congenital epuli (congenital granular cell tumours) in the newborn: a case report and review of literature. *Pol J Pathol*, 2011; 1: 69-71
4. Dash JK, Sahoo PK, Das SN: Congenital granular cell lesion "congenital epulis" – Report of a case. *J Indian Soc Pedo Prev Dent*, 2004; 22: 63-67
5. Godra A, D'Cruz CA, Labat MF, Isaacson G: Pathologic quiz case: a newborn with a midline buccal mucosa mass. *Arch Pathol Lab Med*, 2004; 128: 585-86
6. Ritwik P, Brannon RB, Robert J, Musselman RJ: Spontaneous regression of congenital epulis: a case report and review of the literature. *J Med Case Reports*, 2010; 4: 331
7. Jenkins HR, Hill CM: Spontaneous regression of congenital epulis of the newborn. *Arch Dis Child*, 1989; 64: 145-47
8. Hasanov A, Musayev J, Onal B et al: Gingival granular cell tumor of the newborn: A case report and review of literature. *Turkish J Pathol*, 2011; 27: 161-63
9. Messina M, Severi FM, Buonocore G et al: Prenatal diagnosis and multidisciplinary approach to the congenital gingival granular cell tumor. *J Pediatr Surg*, 2006; 41: E35-38
10. Lack EE, Worsham GF, Callihan MD et al: Gingival granular cell tumor of the newborn (congenital "epulis"): a clinical and pathologic study of 21 patients. *Am J Surg Pathol*, 1981; 5: 37-46