



Received: 2015.02.20
Accepted: 2015.04.01
Published: 2015.06.13

Authors' Contribution:

- A** Study Design
- B** Data Collection
- C** Statistical Analysis
- D** Data Interpretation
- E** Manuscript Preparation
- F** Literature Search
- G** Funds Collection

Thyrolipomas – Prevalence in Computed Tomography and Suggestions for Pragmatic Management

Johannes Gossner^{ABCDEF}

Department of Clinical Radiology, Evangelisches Krankenhaus Göttingen-Weende, Göttingen, Germany

Author's address: Johannes Gossner, Department of Clinical Radiology, Evangelisches Krankenhaus Göttingen-Weende, Göttingen, An der Lutter 24, 37074 Göttingen, Germany, e-mail: johannesgossner@gmx.de

Summary

Background:

Thyrolipomas seem to be a rare occurrence and until now their prevalence has only been reported in two studies. Because of the known significant geographic variations of thyroid disease, generalizability of these findings is uncertain as well as the management of found thyrolipomas.

Material/Methods:

Retrospective study of 107 computed tomography scans of the chest of a European inpatient population. A literature review was performed and considerations for pragmatic management were proposed.

Results:

Thyrolipomas were found in 2.8% of patients. All thyrolipomas were smaller than 15 mm. In all patients these were incidental findings unrelated to patients symptoms. No secondary signs of malignancy could be detected.

Conclusions:

Thyrolipomas are a common finding on cross sectional imaging. Like in this study they seem to be incidental findings lacking clinical relevance. Because of the rare possibility of an thyroid cancer with inclusion of mature fat, sonographic follow-up of incidentally discovered thyrolipomas larger than 15 mm should be suggested.

MeSH Keywords:

Cross-Sectional Studies • Decision Support Systems, Management • Lipoma • Tomography, Spiral Computed

PDF file:

<http://www.polradiol.com/abstract/index/idArt/893916>

Background

Thyroid nodules are a common incidental finding in patients undergoing cross-sectional imaging. For example, in patients undergoing computed tomography (CT) of the chest, incidental thyroid nodules can be found in up to 25.1% [1]. We occasionally noticed small thyroid nodules with fat density, presumably thyrolipomas or adenolipomas. Thyrolipomas have only been rarely described in the literature [2]. The prevalence of these thyrolipomas has only been studied in two studies [3,4]. In a computed tomography study of Asian patients undergoing cervical CT scans, a prevalence of 1.2% was reported. An older autopsy study reported a prevalence of 0.98% in Italian patients [4]. It is unknown whether these prevalence rates can be generalized to other populations, especially as there are significant geographic differences in thyroid diseases [5]. To obtain more data on this topic, the prevalence of thyrolipomas in a sample of European patients undergoing

computed tomography (CT) of the chest was studied. On the other hand, there are no guidelines for the management of small thyrolipomas. In this paper, pragmatic management considerations based on a literature review were proposed.

Material and Methods

This retrospective study was performed in accordance with the statute of the ethics committee of the affiliated University of Göttingen. All chest CT scans performed at our radiology department during may 2014 were retrospectively examined by a single consultant radiologist with 10-year expertise in body cross-sectional imaging (JG). The patients were examined for different indications (pulmonary embolism, infection, interstitial lung disease, cancer, emphysema). Contrast media were not mandatory. CT scans with marked motion artefacts as well as scans with severe streak artefacts were not considered for inclusion. The sample consisted of 107 patients (66 male and 41 female

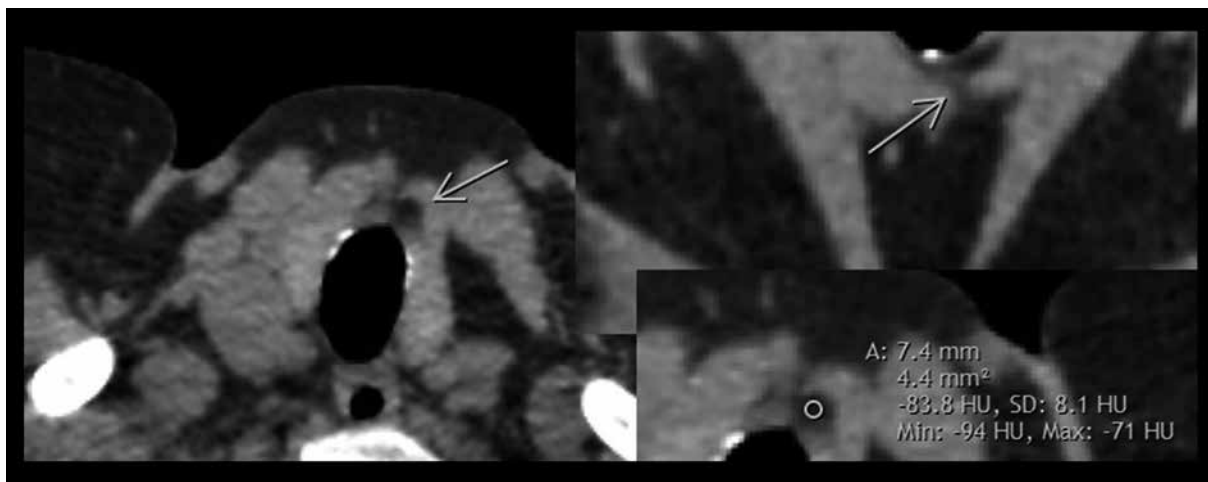


Figure 1. Thyrolipoma on computed tomography of the chest in a 61-year-old woman undergoing imaging because of chronic cough and suspected chronic obstructive pulmonary disease. The found thyrolipoma is connected to the surrounding fat tissue via a fatty band, a finding named the “scoop sign”. Density measurements showed fat isodensity (-83.8 HU).

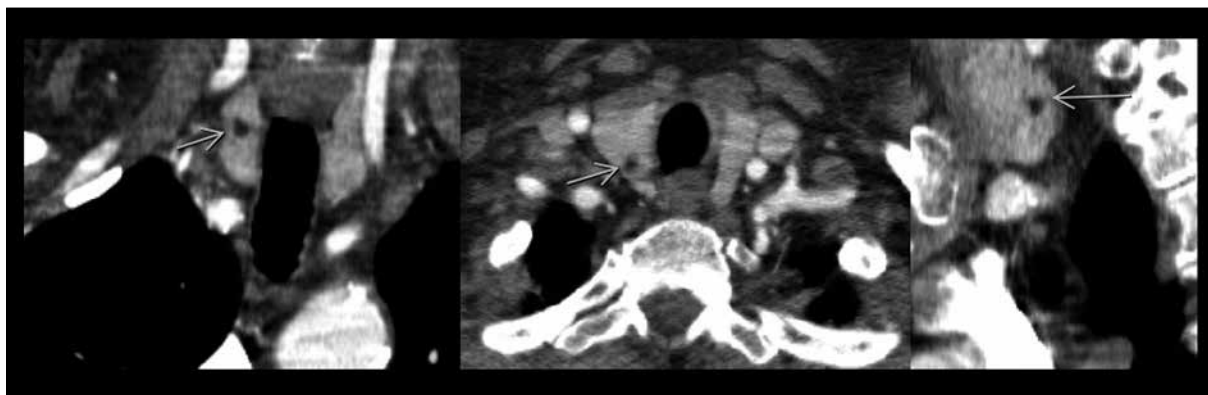


Figure 2. Thyrolipoma on computed tomography of the chest in a 70-year-old woman undergoing imaging because of a suspected pulmonary embolism. There is a well-circumscribed fatty mass in the right lobe of the thyroid (arrows).

patients) with a mean age of 68.6 years (range 24–91 years). All patients were scanned with a 16-slice CT scanner (Activion, Toshiba Medical Systems, Tokyo, Japan) using spiral CT scanning with a slice thickness of 1 mm. The primary axial slices were transferred to a medical workstation and reviewed in a standard soft-tissue window setting using the departmental PACS (SynedraView 3, Synedra Information Technology, Innsbruck, Austria). The diagnosis of a thyrolipoma was made if a well-circumscribed mass located inside the thyroid with a fat density of less than -30 Hounsfield units (HU) could be found (Figure 1). A descriptive statistic was performed. The literature review was conducted using PubMed and Google Scholar.

Results

In this series, 3 patients showed a thyrolipoma (2.8%). The lipomas measured 7, 8, and 13 mm. All patients with a lipoma were older than 61 years. Thyrolipomas were only found in women. All thyroid lipomas were incidental findings unrelated to patients' symptoms. Only one of the three lipomas was reported in the initial report of the scan. One of the thyrolipomas showed a small fatty band connecting it to the adjacent fat tissue (Figure 1), the other two of the lipomas were completely surrounded by thyroid

tissue (Figure 2). One patient received three CT scans, the thyrolipoma did not show any growth or change in appearance from 2013 to 2015. No secondary findings suggestive of cancer, like lymphadenopathy or signs of infiltrative growth, were found.

Discussion

The found prevalence of thyrolipomas is in accordance with the findings of Kim et al. and Autelitano et al. In their large study of 1205 patients, Kim et al. reported about 13 patients with thyrolipomas, i.e. a prevalence of 1.2% [3]. Autelitano et al. reported a prevalence of 0.98% in an autopsy study of 507 Italian patients [4]. In our study, the prevalence was slightly higher, i.e. 2.8%. The most obvious explanation is a statistical effect due to a smaller sample size. The autopsy study may also have missed smaller thyrolipomas due the dissection technique. A more speculative explanation could be the sample of our German inland population itself: in contrast to Korean and Italian populations, patients from the studied region are known to be iodine-deficient and to have more thyroid pathologies. Taking the data of the three studies together, it seems that thyrolipomas are a frequent finding in different patient populations (Asians vs. Southern Europeans vs. Northern Europeans).

A relatively small number of case reports in the literature is in contrast to these findings [2,3,6,7]. One explanation is the fact that the fatty nature of these small lesions is judged as a benign finding, not worth further mentioning. Small lipomas can also be hard to recognize on thick sliced reconstructions (5 mm), which are routinely used in many departments for reporting, because of volume-averaging effects. And as there is only sparse literature on this topic, the radiologists may simply be unaware of the entity of thyroliipomas and not include them in their differential diagnoses. It has also been discussed that the thyroid on CT of the chest or neck is normally not the focus of the examination and small lesions may be simply overlooked [8]. In accordance with this explanations, in our sample, only one of the lipomas was initially reported.

Lipomas are small mesenchymal tumors containing mature fatty tissue, which are lined by a capsule. In contrast to this explanation of a true fatty neoplasm, some authors argue that mature fat inside the thyroid may result from inclusion of mesenchymal fat during embryologic development [3,9]. This explanation was favored by Kim et al. because in their study, 9 of the found 12 lesions showed small fatty bands connecting the lipomas with the adjacent fat, a finding they called the "scoop"-sign [3]. In contrast, in this study, only 1 of the 3 found lipomas showed such a fatty band. Therefore, it may be speculated that there are two different forms of intrathyroid fatty lesions (true fatty neoplasm vs. developmental inclusion of fat tissue).

The fatty nature of the lesion can be confirmed using measurements of fat-isodense HU on CT and with in-phase and out-of-phase MR imaging. Like with other lipomas, the findings of a well-circumscribed purely fatty mass on imaging is diagnostic and histological confirmation is usually not needed [3,6,10]. Small calcifications have been reported [11]. Unfortunately, thyroid malignancies can rarely contain mature fat [10]. In a case series of 17 fatty tumorous lesions, Gnepp et al. reported 7 malignant lesions (6 papillary and 1 follicular cancer) [7]. That report did not comment on imaging findings, but in all lesions, large amounts of mature fat were found and described. Liposarcoma and teratoma of the thyroid gland have also been reported [10–12]. In such cases usually large heterogeneous masses with some parts containing fat density can be seen. Therefore, hypothetically, there is a small chance of malignancy, and follow-up of small incidentally-found thyroliipomas needs to be discussed. According to the current guidelines, which do not comment on incidentally found nodules on CT, further work-up is dependent on the size. Nodules smaller than 1 cm should not be further examined [13]. Interestingly, micro-carcinomas (smaller than 1 cm) are a common finding on autopsy and have a very favourable prognosis with a disease-specific survival of 99.3% after 15 years. [13,14]. Nguyen et al. reported that selection of further work-up of incidentally found thyroid nodules on CT scans based on three parameters (age <35 years, size >15 mm, and aggressive appearance) did not reduce sensitivity in the detection of malignancy.

However, compared to the control of all nodules larger 1 cm, the number of follow-up examinations was significantly reduced [15]. The safety of this approach was replicated in a recently published study [16]. Low density of incidental thyroid nodules on CT seems also to be a feature of benignancy (only densities >50 HU on unenhanced or >130 HU on contrast-enhanced CT scans were associated with malignancy) [17,18]. Therefore, it seems to be justified to suggest a sonographic follow-up only for incidentally found thyroliipomas larger than 15 mm. Given the fact that usually a larger classic lipoma does not show any suspicious features on imaging, it may be categorized as probably benign. In this case a follow-up in 6–18 months' time should be obtained and if the lesion is stable, the control interval is extended to 3–5 years [13]. Interestingly, in a recent study by Lee et al., no benefit of a follow-up longer than 3 years for a benign thyroid nodule could be shown [19]. Pragmatically, a thyroliipoma larger than 15 mm should be controlled 12 and 24 months after its discovery and, if stable, the follow-up may be ceased. The suggestions of a follow-up should also be adapted individually to the patient's situation; for example, it is not justified in patients with a terminal illness or in the very old. If signs of malignancy like rapid growth, clinical symptoms, lymphadenopathy, or infiltrative appearance can be found, a histological work-up is needed. Another differential diagnosis of fat accumulation of the thyroid is thyroliipomatosis, which can be morphologically distinguished by diffuse gland enlargement and fat accumulation [9].

There are several limitations of this study. First, there is the relatively small sample size. However, as the purpose of the study was to confirm the generalizability of the reported prevalence rates of the larger studies by Kim et al. and Autelitano et al. to other populations, and not to establish the prevalence rates *per se*, the small sample size is in our opinion justifiable. The second shortcoming is, that there was no histological confirmation of the found lipomas. However, as it is unethical to obtain fine-needle aspiration cytology in benign-appearing small thyroid nodules, imaging features seem to be diagnostic of lipoma. In this study, CT scans of the chest were used. The thyroid gland was sometimes not fully included in the used CT scans, which means that the prevalence may have been even higher.

Conclusions

Thyroliipomas are quite a common finding and can be found in up to 2.8% of patients undergoing CT of the chest. In most patients they seem to be incidental findings lacking clinical relevance. Because of the hypothetical possibility of thyroid cancer with inclusion of mature fat tissue, sonographic follow-up (after 12 and 24 months) of an incidentally discovered thyroliipoma larger than 15 mm should be suggested.

Conflict of interest

There is no conflict of interest to declare.

References:

1. Ahmed S, Johnson PT, Horton KM et al: Prevalence of unsuspected thyroid nodules in adults on contrast-enhanced 16- and 64-MDCT of the chest. *World J Radiol*, 2012; 4: 311-17
2. Ge Y, Luna MA, Cowan DF et al: Thyrolipoma and thyrolipomatosis: 5 case reports and historical review of the literature. *Ann Diagn Pathol*, 2009; 13: 384-89
3. Kim KH, Seo HS, Lee YH et al: Study of intrathyroid fat containing lesions using CT imaging with literature review. *Neuroradiology*, 2013; 55: 1405-11
4. Autelitano F, Santeusiano G, Mauriello A et al: [Latent pathology of the thyroid: an epidemiological and statistical study of thyroids sampled during 507 consecutive autopsies.] *Ann Ital Chir*, 1992; 63: 761-81 [in Italian]
5. Hedinger C: Geographic pathology of thyroid disease. *Pathol Res Pract*, 1981; 171: 285-92
6. Rollins SD, Flinner RL: Thyrolipoma: diagnostic pitfalls in the cytologic diagnosis and review of the literature. *Diagn Cytopathol*, 1991; 7: 150-54
7. Gnepp DR, Ogorzalek JM, Heffess CS: Fat containing lesions of the thyroid gland. *Am J Surg Pathol*, 1989; 13: 605-12
8. Shetty SK, Maher MM, Hahn PF et al: Significance of incidental thyroid lesions detected on CT: correlation among CT, sonography, and pathology. *Am J Roentgenol*, 2006; 187: 1349-56
9. Sanuvada RV, Chowhan AK, Rukmangadha N et al: Thyrolipomatosis: an inquisitive rare entity. *Gland Surg*, 2014; 3(4): E6-E9
10. Borges A, Catarino A: Case 53: Adenolipoma of the thyroid gland. *Radiology*, 2002; 225: 746-50
12. Mitra A, Fisher C, Rhys-Evans P, Harmer C: Liposarcoma of the thyroid. *Sarcoma*, 2004; 8: 91-96
13. Zaimine R, Sellami M, Abid W et al: Thyroid teratoma: a case report. *Tunis Med*, 2014; 92: 286-87
14. Cooper DS, Doherty GM, Haugen BR et al: Revised American Thyroid Association management guidelines for patients with thyroid nodules and differentiated thyroid cancer. *Thyroid*, 2009; 19: 1167-214
15. Yu XM, Wan Y, Sippel RS, Chen H: Should all papillary thyroidmicrocarcinomas be aggressively treated? An analysis of 18,445 cases. *Ann Surg*, 2011; 254: 653-60
16. Nguyen XV, Choudry KR, Eastwood JD et al: Incidental thyroid nodules on CT: evaluation of 2 risk-categorization methods for work-up of nodules. *Am J Neuroradiol*, 2013; 34: 1812-17
17. Bahl M, Sosa JA, Eastwood JD et al: Using the 3-tiered system for categorization workup of incidental thyroid nodules detected on CT, MRI, or PET/CT: how many cancers would be missed? *Thyroid*, 2014; 24: 1772-78
18. Lee JH, Jeong SY, Kim YH: Clinical significance of incidental thyroid nodules identified on low-dose CT for lung cancer screening. *Multidiscip Respir Med*, 2013; 8: 56
19. Yoon DY, Chang SK, Choi SK et al: The prevalence and significance of incidental thyroid nodules identified on computed tomography. *J Comput Assist Tomogr*, 2008; 32: 810-15
20. Lee S, Skleton TS, Zheng F et al: The biopsy proven benign nodule: is long term follow up necessary? *J Am Coll Surg*, 2013; 217: 81-89