



Received: 2015.03.16  
Accepted: 2015.04.04  
Published: 2015.06.10

**Authors' Contribution:**

- A** Study Design
- B** Data Collection
- C** Statistical Analysis
- D** Data Interpretation
- E** Manuscript Preparation
- F** Literature Search
- G** Funds Collection

## MRI of Residual Red Bone Marrow in the Distal Femur of Healthy Subjects

Gozde Arslan<sup>1ABCFE</sup>, Evrim Ozmen<sup>2ACD</sup>, Mehmet Soyuturk<sup>1AEF</sup>

<sup>1</sup> Department of Radiology, Erzincan Mengucek Gazi Training-Research Hospital, Erzincan, Turkey

<sup>2</sup> Department of Radiology, Cerrahpasa Medical School, Istanbul, Turkey

**Author's address:** Gozde Arslan, Department of Radiology, Erzincan Mengucek Gazi Training- Research Hospital, Erzincan, Turkey, e-mail: gunesgozde@gmail.com

**Background:**

The purpose of our study is to examine the correlation of the residual red bone marrow areas of distal femoral metaphysis with the age, gender, weight and hemoglobin (hgb) values; evaluate the results, and comprehend the importance of these residual areas in the light of the results.

**Material/Methods:**

140 nonsmoking patients between the ages of 26 and 72 (92 women, 48 men) who had knee MR examinations were included in the study. The residual red bone marrow areas in the distal femoral metaphysis in MR images were examined by a radiologist. The areas were separated into grades according to their sizes. The hemoglobin values of the cases were measured. The size of the residual red bone marrow area and the age, gender, weight and hemoglobin values of the cases were compared by using the Tukey and Chi-Square Tests.

**Results:**

Although no significant differences were observed between the mean ages, weights and hemoglobin values of the grades, a significant difference was detected between the gender distribution. The male group had less residual red bone marrow in the distal femoral metaphysis than the female group ( $p=0.003$ ).

**Conclusions:**

We observed that the hypointensities due to residual red bone marrow observed in the T1WS of the distal femoral metaphysis are not related with the age, weight and hemoglobin values. No grade 2 and grade 3 patient was detected in male group. We observed that these hypointense areas showed difference according to the gender variable; however, were not affected by the hemoglobin values over certain levels.

**MeSH Keywords:**

**Bone and Bones • Bone Marrow • Magnetic Resonance Imaging**

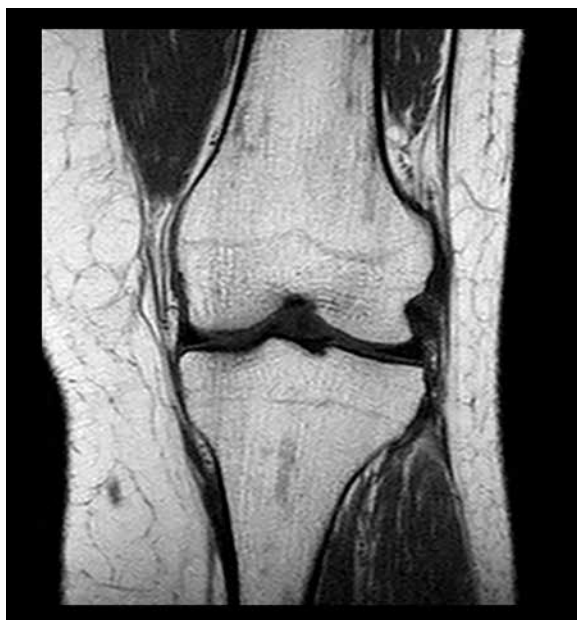**PDF file:**

<http://www.polradiol.com/abstract/index/idArt/894118>

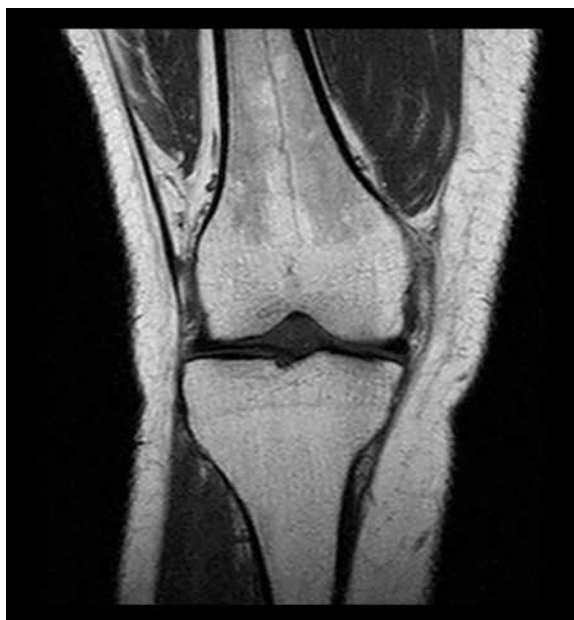### Background

We frequently observe the patchy residual red bone marrow areas in the distal femoral metaphyses in routine knee MR examinations [1]. Radiologists have a dilemma on whether or not to report these areas as physiological or pathological. The red bone marrow which dominates all of the bones at birth becomes yellow with age. These areas in the femoral metaphysis are accepted as physiological red bone marrow areas below the age of 25. Over the age of 25, the residual dotted and patchy red bone marrow areas may be observed [2,3]. In the literature, signal patterns and typical distribution of residual red marrow is explained. Knowledge of these characteristics helps

avoiding misdiagnosis [4]. Due to physiological or pathological causes, reconversion from yellow to red bone marrow occurs and hypointensity in T1WS and hyperintensity in the STIR (Short TI Inversion Recovery) sequence is observed [5-7]. Smoking might affect reconversion. In the previous publications, smoking and nonsmoking cases were compared [8]. We know that anemia causes reconversion and increase in the number of red bone marrow areas, but as far as we know, there are no studies on the comparison of hemoglobin values and residual red bone marrow areas in healthy individuals. Our purpose in this study was to evaluate the effects of gender, age, weight, and hemoglobin values – i.e. causes other than pathological – on the bone



**Figure 1.** The T1WS coronal sequence of knee MRI in a 36-year-old female weighing 80 kg. The residual red bone marrow areas were of grade 1 (Hgb level: 12.9 g/dL).



**Figure 2.** The T1WS coronal sequence of knee MRI of a 36-year-old female weighing 66 kg. The residual red bone marrow areas were of grade 3 (Hgb level: 15.1 g/dL).

marrow with the help of MR images, and discuss the usefulness of reporting these areas in daily routine.

## Material and Methods

### Patient population

Our study is a single-center prospective clinical study and was conducted in accordance with ethical principles set by the World Medical Association Declaration of Helsinki. Our patient group consisted of 92 women between the age of 26 and 70, and 48 men between the age of 27 and 72, who had lived in the city of Erzincan (altitude: 1185 m, 3887 ft) for the last decade. The knee MRIs of the cases were taken, their blood tests were performed simultaneously, and the hemoglobin values were measured. The correlation of the areas measured on the MR images was made with the age, gender, weight, and hemoglobin values.

### Imaging and imaging analysis

The knee MR exams were conducted with a (Philips brand) 1.5 Tesla MR device by using an 8-channel knee coil. Coronal T1, coronal T1, sagittal-axial T2, and sagittal proton-weighted sequences were taken without giving contrast agent. The following parameters were used for the T1-weighted coronal spin-echo sequence: TR/TE 450/20; matrix size 256×192; section thickness 3 mm; FOV 16 cm; bandwidth 16. The following parameters were used for the stir coronal sequence: TR/TE 746/7, matrix size 256×192; section thickness 4 mm; FOV 16 cm; bandwidth 19 cm. The size of the patchy areas compatible with residual red bone marrow in the distal femoral metaphyses, hypointense relative to the neighboring bone tissue but hyper-isointense relative to the neighboring muscle tissue in T1WS, were evaluated qualitatively. Those areas were confirmed as being hyperintense in the STIR sequence. The lesions that

are more hypointense than the neighboring muscle tissue are accepted as pathological (malignancy etc.) and were not included in the study. The measurements were repeated twice at different times in order to increase the accuracy of the grading system.

The patchy areas were defined as grade 1 if mild and covering less than 30% of the metaphysis, grade 2 if moderate and covering between 30% and 60% of the metaphysis, and grade 3 if diffuse and covering more than 60% of the metaphysis (Figures 1, 2).

### Exclusion criteria

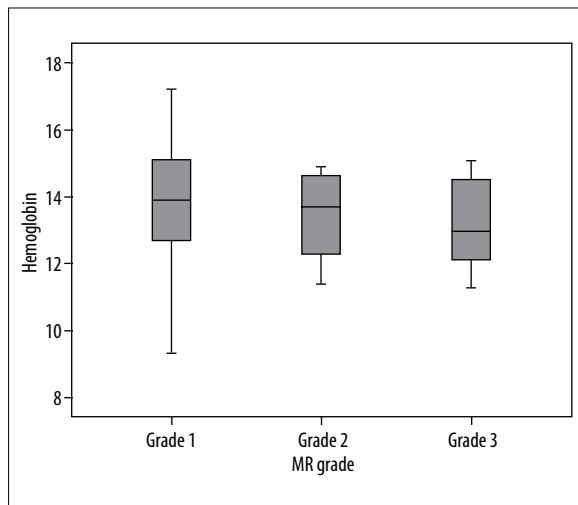
- 1 – Cases under the age of 25 (since the adult bone marrow pattern is not formed until then);
- 2 – Cases who smoked (8);
- 3 – Athletes;
- 4 – Patchy areas which were hypointense when compared with the neighboring muscle tissue [9];
- 5 – Cases with marrow edema due to contusion;
- 6 – History of steroid use, osteonecrosis and fracture;
- 7 – Cases with malignant or systemic diseases that might have affected the bone marrow.

### Statistical analysis

The statistical analysis in this study was carried out using the NCSS (Number Cruncher Statistical System) 2007 Statistical Software (Utah, USA) package program. In evaluating the data, the descriptive statistical methods (average, standard deviation) were used. The One-Way Analysis of Variance was used in comparisons among the groups; the Tukey's Multiple Comparison Test was used in comparisons of the sub-groups; and the Chi-Square Test was applied to compare the qualitative data. In the differential diagnosis of signal increase for hemoglobin, the area under the ROC

**Table 1.** The demographic information of grade 1, grade 2, and grade 3 groups.

		Grade 1 n: 121		Grade 2 n: 10		Grade 3 n: 9		P
Age		48.09±12.88		51.3±10.59		40.22±11.98		0.137
Gender	Male	48	39.67%	0	0.00%	0	0.00%	0.003
	Female	73	60.33%	10	100.00%	9	100.00%	
Weight (kg)		74.88±13.65		78.1±8.77		72±13.49		0.609
Hemoglobin (g/dL)		13.8±1.61		13.44±1.31		13.17±1.38		0.434

**Figure 3.** The boxplot showing the distribution of hemoglobin values (g/dL) according to the grades.

curve, sensitivity, specificity, positive and negative predictive value, LR (likelihood ratio) (+) value and predictive value were measured. The results were evaluated at significance level of  $P < 0.05$ .

## Results

A total of 152 patients were analyzed. The demographic data of the cases are summarized in Table 1. Smokers and young patients were excluded right from the beginning. One patient with leukemia, 10 patients with marrow edema and bone contusion, one patient with sickle cell anemia were excluded from the study. We had 140 patient to be included.

There were 48 (39.6%) male and 92 (60.4%) female patients. A statistically significant difference was observed in gender distribution of grade 1, grade 2, and grade 3 cases. No male cases were observed in grade 2 and grade 3 groups ( $P = 0.003$ ). Among female cases, there were 78 grade 1, 10 grade 2, and 9 grade 3 cases. (Table 1).

**Table 2.** Hemoglobin cut-off points for grade 2 and 3 groups.

	Cut-off point	Sensitivity	Specificity	PPV*	NPV*	LR (+)*
Grade 2	<14.9 g/dL	100.00	27.27	10.2	100.0	1.37
Grade 3	<13.1 g/dL	66.67	62.81	11.8	96.2	1.79

\* PPV – positive predictive value; \* NPV – negative predictive value, \* LR – likelihood ratio.

No statistically significant difference was detected between the mean age values of grade 1, grade 2, and grade 3 cases ( $P = 0.137$ ).

No statistically significant difference was detected between the average weight values of grade 1, grade 2, and grade 3 cases ( $P = 0.609$ ). The weights ranged between 52 and 104 kgs.

No statistically significant difference was detected between the average hemoglobin values of grade 1, grade 2, and grade 3 cases ( $P = 0.434$ ). The hemoglobin values in male patients fell between 12 and 16.5 g/dL; and in female patients between 9.3 and 15.6 g/dL (Figure 3).

The area under the curve and cut-off points of hemoglobin levels in grade 2 and grade 3 groups compared to grade 1 group were detected (Table 2).

## Discussion

The blood vessels, nerve cells, phagocytes and stem cells in bone marrow consist of water and fat. The main duty is to provide blood cells according to the need of the body. There are two types of the marrow: red and yellow. There are active hematopoietic cells in the red bone marrow and they contain 40% of water. The yellow bone marrow, on the other hand, does not play a role in active hematopoiesis and contains 80% of fat [10]. While almost the whole bone marrow in a newborn consists of the red bone marrow, conversion into the yellow bone marrow with age occurs. The conversion follows from the peripheral to the center, and from the diaphysis into the metaphysis [10]. The conversion is mostly completed until the age of 25, and only some residual red bone marrow remains in some areas such as the sternum, vertebra, ribs, pelvis, proximal femur, and humerus [6,11]. These residual red bone marrow areas may show differences in each individual. With ages, according to the need for blood cells of the body, the yellow bone marrow may be converted into the red bone marrow again from the proximal to the distal, and this is called «reconversion».

The situations that may cause reconversion include:

- Physiological (in order to cover the increasing hemoglobin requirements);
- In people who fly to high altitudes;
- In professional sportsmen;
- In smokers;
- In diseases like thalassemia, sickle cell anemia;
- Pathological;
- Infiltrative diseases (leukemia, lymphoma, monoclonal gammopathy, metastasis).

Of the imaging methods, MRI is the best one in evaluating the bone marrow. Fatty marrow appears hyperintense on T1-weighted sequences since lipid protons have short T1 relaxation times. Red marrow contains more water and has an intermediate T1 relaxation time, and appears to have a lower signal than subcutaneous fat, but a higher one than intervertebral discs or muscles. The physiological reconversion and pathological situations may easily be followed with MR imaging. In case of reconversion, the increase in the form of patchy T1WS hypointensities limited with the distal femoral metaphysis and not reaching the epiphysis is detected.

According to the results of our study, there were no correlations between the age and those hypointense areas. If we had included patients under the age of 25 in our study, an increase would have been observed without doubt because of the immature bone marrow [12]. We observed that there were no differences in the patients who were above that age. We did not detect any effect of the weight in our study, as some previously reported studies [13].

The fact that no grade 2 or grade 3 cases were detected in the male group (even in those with lower hemoglobin values), and the fact that grade 2 and grade 3 images were detected in the female group (even in those with higher hemoglobin values) was surprising. For example, we had a case with a hemoglobin value of 15 g/dL in grade 3 group. We also had many cases with low hemoglobin values, like 11 g/dL, in grade 1 group. We believe that anemia does not cause an increase in residual red bone marrow areas until hemoglobin values drop below a certain level. Until now, we, as radiologists, have not reported any grade 1 cases in knee exam reports in our clinic. We only found grade 2 and grade 3 cases, and recommended the cases to be examined

in terms of any pathologies that might cause red bone marrow reconversion, like anemia. We could still follow the same pattern when it comes to male patients because we did not observe any grade 2 or 3 patients in the male group in our study, whereas, in female cases we observed grade 2 and grade 3 cases without any hematological pathologies. We consider those grade 2 and grade 3 cases as benign structural variants which might be influenced by sex hormone levels. Earlier; we thought that this might be caused by mild blood loss of women during menstruation. However, in our study we did not observe an inverse correlation of these patchy areas with hemoglobin levels.

The fact that it is not hypointense when compared with the neighboring muscle, the fact that it does not reach the epiphysis and diaphysis, it does not have an accompanying soft tissue lesion and cortical destruction support that it is not pathological [14–16].

The limitation of our study is the evaluation of the red bone marrow areas qualitatively but not quantitatively. Our initial purpose was to carry out volumetric measurements. However, since these areas are not in a distinct mass form, and their borders are unclear, their volumes could not be measured. For this reason, this kind of evaluation might be considered as subjective, and the grading was carried out in such a manner. However, in order to increase the reliability, the measurements were made twice at different times. Another limitation was the fact that the lowest hemoglobin value was 9 g/dL in both of the groups. In the values below a certain level perhaps the prevalence of the hypointense areas increases in a more rapid manner than in the values above it. Better results could be obtained in the future by overcoming these limitations.

## Conclusions

In conclusion; we believe that knowing the typical location of this structural variant and its pattern in MRI will prevent the radiologists from over-diagnosing and will avoid unnecessary tests.

## Conflicts of interest

The authors declared no conflicts of interest.

## References:

1. Lang P, Fritz R, Majumdar S et al: Hematopoietic bone marrow in the adult knee: spin-echo and opposed-phase gradient-echo MR imaging. *Skeletal Radiol*, 1993; 22: 95–103
2. Malkiewicz A, Dziedzic M: Bone marrow reconversion – imaging of physiological changes in bone marrow. *Pol J Radiol*, 2012; 77(4): 45–50
3. Richardson ML, Patten RM: Age-related changes in marrow distribution in the shoulder: MR imaging findings. *Radiology*, 1994; 192: 209–15
4. Stacy GS, Dixon LB: Pitfalls in mr image interpretation prompting referrals to an orthopedic oncology clinic. *Radiographics*, 2007; 27(3): 805–26
5. Ricci C, Cova M, Kang YS et al: Normal age-related patterns of cellular and fatty bone marrow distribution in the axial skeleton: MR imaging study. *Radiology*, 1990; 177(1): 83–88
6. Vande Berg BC, Malghem J, Lecouvet FE et al: Magnetic resonance imaging of normal bone marrow. *Eur Radiol*, 1998; 8(8): 1327–34
7. Acosta Batlle YJ, Hernandez Muñiz S, Palomino Aguado B et al: The role of MRI in the assessment of bone marrow. *ECR*. 2010; C-2180, Educational Exhibit
8. Poulton TB, Murphy WD, Duerk JL et al: Bone marrow reconversion in adults who are smokers: MR imaging findings. *Am J Roentgenol*, 1993; 161(6): 1217–21
9. Daffner RH, Lupetin AR, Dash N et al: MRI in the detection of malignant infiltration of bone marrow. *Am J Roentgenol*, 1986; 146: 353–58
10. Vogler JB III, Murphy WA: Bone marrow imaging. *Radiology*, 1988; 168(3): 679–93
11. De Bruyn PP, Breen PC, Thomas TB: The microcirculation of the bone marrow. *Anat Rec*, 1970; 168: 55–68

12. Moore SG, Dawson KL: Red and yellow marrow in the femur: age-related changes in appearance at MR imaging. *Radiology*, 1990; 175(1): 219-23
13. Pouiton TB, Murphy WD, Duerk JL et al: Bone marrow reconversion in adults who are smokers: MR Imaging findings. *Am J Roentgenol*, 1993; 161(6): 1217-21
14. Ziólko E, Kwiatkowska-Pamula A, Adamczyk T et al: Usefulness of magnetic resonance imaging as a prognostic variable in myelodysplastic syndromes. *Med Sci Monit*, 2014; 20: 1634-40
15. Roemer FW, Frobell R, Hunter DJ et al: MRI-detected subchondral bone marrow signal alterations of the knee joint: terminology, imaging appearance, relevance and radiological differential diagnosis. *Osteoarthritis Cartilage*, 2009, 17(9): 1115-31
16. Shah GL, Rosenberg AS, Jarboe J et al: Incidence and evaluation of incidental abnormal bone marrow signal on Magnetic Resonance Imaging. *ScientificWorldJournal*, 2014; 380814