



Received: 2015.02.18
Accepted: 2015.03.05
Published: 2015.06.04

Authors' Contribution:

- A** Study Design
- B** Data Collection
- C** Statistical Analysis
- D** Data Interpretation
- E** Manuscript Preparation
- F** Literature Search
- G** Funds Collection

Reorganization of Language Areas in Patient with a Frontal Lobe Low Grade Glioma – fMRI Case Study

Katarzyna Kośła^{1ABCDEF}, Bartosz Bryszewski^{2BDE}, Dariusz Jaskólski^{2BD},
Nina Błasiak-Kołacińska^{1E}, Ludomir Stefańczyk^{1ACD}, Agata Majos^{1ACDEF}

¹ Department of Radiology and Diagnostic Imaging, Medical University of Łódź, Łódź, Poland

² Department of Neurosurgery, Medical University of Łódź, Łódź, Poland

Author's address: Katarzyna Kośła, Department of Radiology and Diagnostic Imaging, Medical University of Łódź, Łódź, Poland, e-mail: katarzyna_kosla@wp.pl

Source of support: This work was supported by the Medical University of Łódź, research task No. 502-03/1-136-01/502-14-171

Background:

Functional magnetic resonance (fMRI) studies results in case of an adult patient with low grade glioma (LGG) in dominant hemisphere suggest brain plasticity process with acquisition of language functions by the non-dominant hemisphere speech regions.

Case Report:

A 36-years old right-handed woman was admitted to the Department of Neurosurgery for surgical treatment of brain tumor. An MRI examination revealed a pathological mass in the left frontal lobe, in close topographical relationship to the Broca's area. A left fronto-parietal craniotomy was performed, with an intraoperative awake language mapping procedure. A total resection of the pathological mass was achieved. The tumor was examined histologically as LGG. In the follow-up MRI exam 32 months after the operation a tumor recurrence was suggested. The fMRI exams performed preoperative and 3, 32 and 41 months after the operation showed changes in language regions activation patterns, with a progressive right-sided activation of Broca's and Wernicke's areas. Pre- and postoperative cognitive evaluation by a neuropsychologist did not detect any language impairment. We present a running process of reorganization of language areas in a patient after brain tumor resection, from strong left-sided to symmetrical lateralization.

Conclusions:

1. fMRI results in comparison with the psychological status of the patient proved contribution of functional reorganization to the preservation of language performance. 2. A slow growing LGG as well as the recurrence of the tumor near the left Broca's area might be the factors leading to reorganization of language-related areas by recruiting the right hemisphere.

MeSH Keywords:

Brain Neoplasms • Language Disorders • Magnetic Resonance Imaging

PDF file:

<http://www.polradiol.com/abstract/index/idArt/893897>

Summary

Background

We present a case study of an adult right-handed patient with a tumor in the left frontal lobe, influencing the language functions. In pre- and postoperative fMRI studies, changes in language activation patterns were observed, with progressive right-sided activity of Broca's and Wernicke's areas. Our fMRI results, compared with the neuropsychological status of the patient, strongly suggest brain plasticity with acquisition of language functions by the non-dominant hemisphere speech regions.

Case Report

A 36-year-old right-handed woman was admitted to the Department of Neurosurgery for surgical treatment of a brain tumor. The first symptom of the disease was a simple partial seizure for the first time in her life. Three months before hospital admission, MRI examination was performed which revealed a pathological mass with a volume of 2.63 cm³ in the left frontal lobe in close topographical relationship to the Broca's area. That is why the first preoperative fMRI study

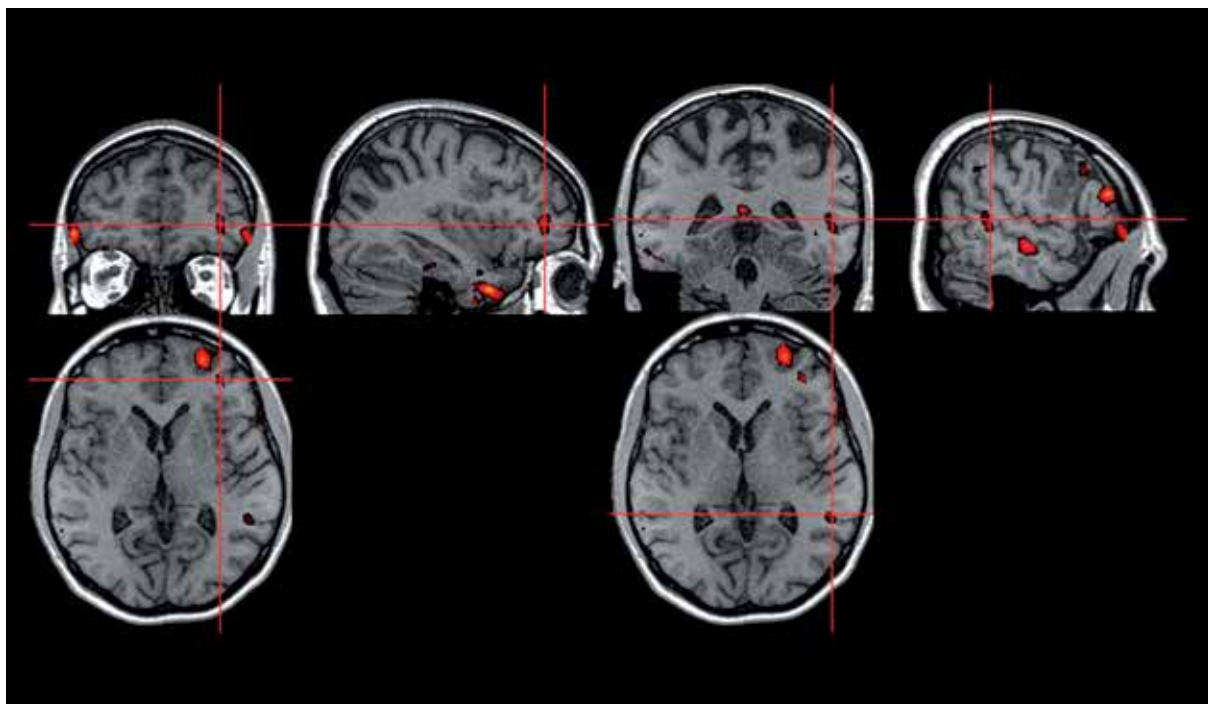


Figure 1. Sagittal, coronal and axial views of the left Broca's and Wernicke's area activation in the preoperative fMRI study.

was performed before the operation, as the identification of language-related areas was necessary.

What is more, the neuropsychological tests were administered by the neuropsychologist several times. The first evaluation was performed prior to the operation and was based on the Boston Naming Test: naming of visually presented objects. After the operation, language skills were assessed during scheduled visits to the Clinic, based on an unstructured interview with the patient.

A left fronto-parietal craniotomy was performed, with intraoperative awake language mapping during which the picture-naming task was used. Cortical stimulation was carried out with bipolar electrodes by progressively increasing the current amplitude by 0.5-mA increments, beginning at 2 mA, and up to 10 mA.

A total resection of the pathological mass was achieved. The patient was discharged home within 9 days after the operation with no neurological or neuropsychological deficits.

The tumor was examined histologically and classified as astrocytoma fibrillare – in WHO scale grade II.

Further MRI examinations performed 3, 11, and 20 months after surgery showed no evidence of recurrent tumor. Within two years after surgery the patient still had seizures with a frequency of one every few months. The attacks were simple partial with transient motor aphasia. In the third year after the operation the type of the seizures remained the same, but they became more frequent – 1–2 a month. The patient had no other neurological deficits. The follow-up MRI examination at 32 months after the operation showed slight oedema and a diffusion signal abnormality near the postoperative area in the inferior part of the

prefrontal gyrus. Tumor recurrence was suggested. Because still no other or new neurological deficits occurred, no reoperation was performed.

The fMRI examinations were performed several times in that period: at 3, 32, and 41 months after the operation.

All fMRI examinations, including the preoperative session, were approved by the local ethics committee (decision no. RNN/123/09/KE) and patient informed consent was obtained.

FMRI task design

The patient was informed about the exact course of each study at 30 minutes before it started. Word generation (WG) task was used as a paradigm in all examinations but of different type. The study was divided into five blocks, each containing 10 acquisitions. The pattern of stimulation proceeded in the ABABABABAB block diagram, where A was rest (control), and B represented stimuli.

In the preoperative and first postoperative fMRI study the patient was ordered to pronounce in periods of stimulation non-repetitive male and female names, for example "John, Mary". The signals for stimulation and rest were shown to the patient respectively as the text: "NAME" and the sign "X". In the third and fourth fMRI examination the patient was asked to pronounce in periods of stimulation nouns from a given category. The signals for stimulation were shown to the patient, for example the word "FURNITURE". The signal for rest remained the same – the sign "X".

FMRI data acquisition

An fMRI was performed using a 1.5 T scanner (Siemens, Avanto). Morphological, three-dimensional T1-weighted

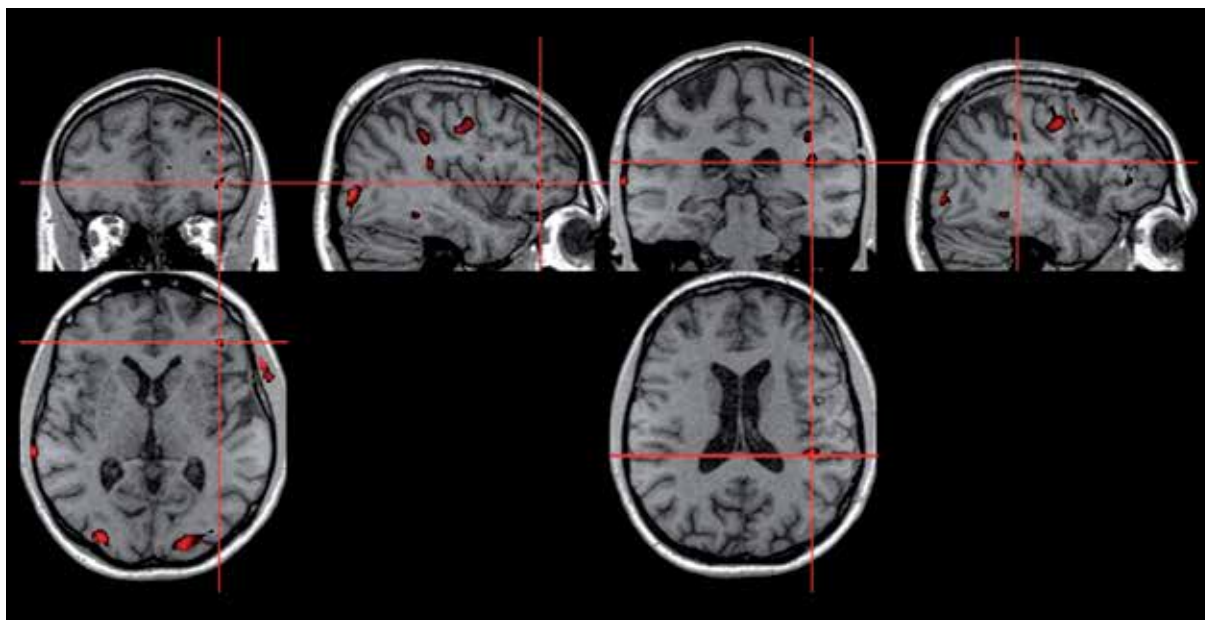


Figure 2. Sagittal, coronal and axial views of the left Broca's and Wernicke's area activation in the fMRI study 3 months after the operation.

sequences were obtained according to the following protocol: FOV=256×256 mm, matrix=512×512, TR=8.8 ms, TE=4.8 ms, TA=5'07. Each volume acquired contained 160 slices of 1 mm thick. The functional examination included echoplanar imaging (EPI) sequences: TR=3000 ms, TE=50 ms, FOV=1680×1680 mm, matrix 64×64, TA=5'11, thirty-eight slices 3 mm thick.

Imaging data analysis

The analysis of the data was conducted using the statistical program SPM 2, running in MATLAB (<http://www.fil.ion.ucl.ac.uk/spm/>). Data were analyzed for $P=0.05$.

Using radiological anatomy atlases, four regions of interest (ROIs) responsible for language functions were designated: a. Broca's area in the left inferior frontal gyrus (Brodmann area, BA 44, BA 45), b. the area anatomically homologous to this region in the right hemisphere, c. Wernicke's area in the left superior temporal gyrus (BA 22) and adjacent: superior temporal sulcus, middle temporal gyrus (BA 21), angular gyrus (BA 39), and supramarginal gyrus (BA 40), d. the area anatomically homologous to the region c located in the right hemisphere [8]. The lateralization index (LI) was calculated on the basis of the number of activated voxels in the four areas defined above, as it was determined in the literature before [9,10]. That enabled to avoid an analysis of non-specific activity or activity of non-linguistic areas, activated as a consequence of sensory or motor stimuli [9]. The lateralization index was calculated according to the formula: $LI=(L-R)/(L+R)$, separately for the Broca's and Wernicke's area and their right-sided homologous regions [11].

fMRI analysis results

In the first, preoperative fMRI, the increase of the signal was present only in the left Broca's and Wernicke's areas (Figure 1).

In the fMRI study 3 months after the operation the activation in both speech regions decreased but remain left-sided (Figure 2). In the third fMRI study 32 months after surgery the signal increased in the left-sided regions, but additionally activation in the right-sided Broca's and Wernicke's areas appeared (Figure 3). The lateralization index remained left-sided. In the fourth fMRI, the LI for both Broca's and Wernicke's areas became symmetrical. (Figure 4) The results are shown in Table 1.

Neuropsychology

Preoperative cognitive evaluation by a neuropsychologist based on the Boston Naming Test did not detect any defined language deficit. Further neuropsychological evaluation based on an interview did not detect any language impairment either. The patient reported that in her daily life there were no difficulties in word finding or understanding.

Intraoperative stimulations (IOS)

Intraoperative stimulations were performed only in the left hemisphere in agreement with practical surgical needs. During surgery, IOS close to the anterior aspect of the tumor caused naming performance problems.

Discussion

Our study demonstrates a case of activation changes in language areas in a patient after resection of a low-grade glioma in the left frontal lobe. In the preoperative study, only the left-sided Broca's and Wernicke's areas were active and normal language skills were kept with no change. Only a single seizure with transient motor aphasia was noticed and explained by the location of the pathological mass. In the first fMRI exam, the objective of the study was to determine the location of the Broca's area, which was important for the neurosurgeons in preoperative planning.

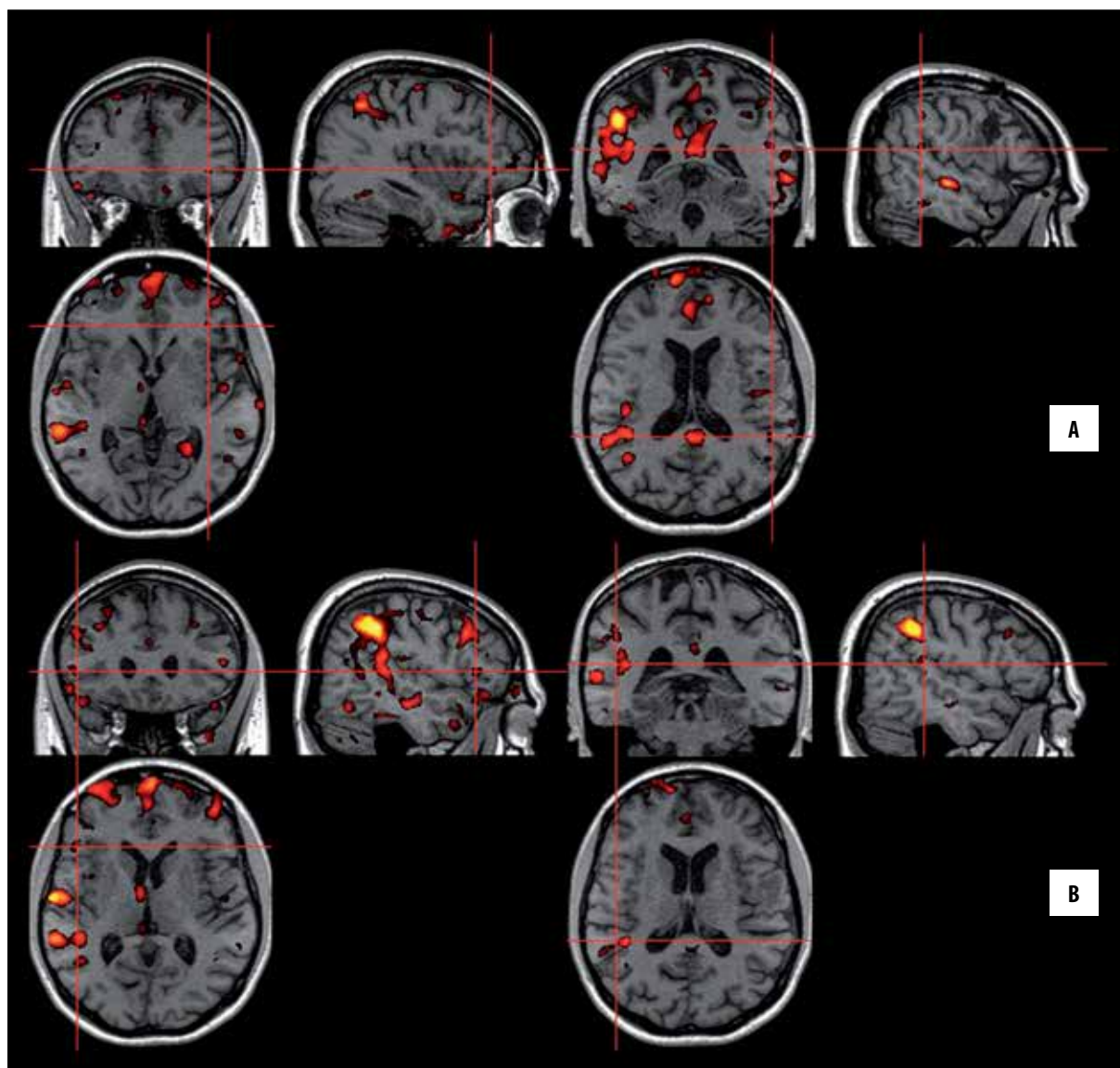


Figure 3. Sagittal, coronal and axial views of the Broca's and Wernicke's area activation in the fMRI study 32 months after the operation. (A) Activation in the left hemisphere, (B) activation in the right hemisphere.

Studies on healthy volunteers showed that 92.5–97% of right-handed people have left-sided lateralization for language functions [12–14]. Our patient who was also right-handed had strong left-sided lateralization in the preoperative fMRI. The small volume of the tumor indicating a rather short duration of the pathological process explains the lack of reorganization of language functions.

In the second fMRI, 3 months after the operation, there was no activity of language areas in the right hemisphere. What is more, the number of activated voxels within each cluster for the left-sided Broca's and Wernicke's areas decreased. As we used the same paradigm, the language abilities of the patient stayed unchanged, which might be explained by the presence of the postoperative changes in the brain tissue which in turn might affect the blood supply and the BOLD effect itself [7,15,16].

Two years after the operation the seizures became more frequent and recurrence of the tumor was suggested in the control MRI examination. In the third fMRI study, 31 months after the operation, the right-sided Broca's and Wernicke's areas were found to be active additionally, but the lateralization index remained left-sided. It is possible that the recurrence of the tumor initiated reorganization of the speech centers [17].

Plasticity is the ability of the brain to modify itself. Structural and functional neural networks might be modified by different factors including surgical resection of brain tissue or growing tumor of the central nervous system [1,2]. The two concepts of brain plasticity – redundant region and regional degenerative are well known [18].

Slow-growing brain tumors may induce functional reorganization. It is believed that this is the explanation for why neurological deficits do not appear immediately with

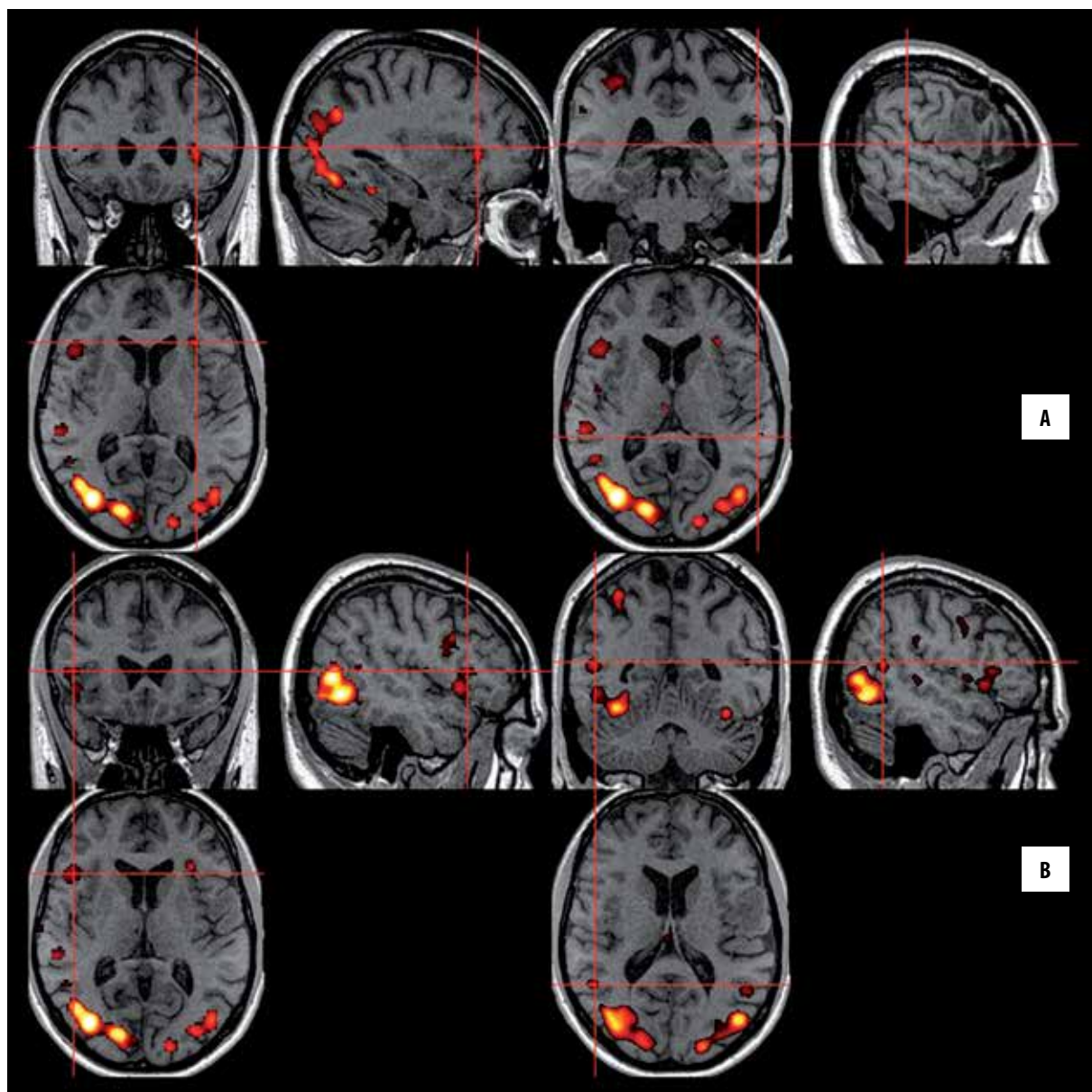


Figure 4. Sagittal, coronal and axial views of the Broca's and Wernicke's area activation in the fMRI study 41 months after the operation. (A) Activation in the left hemisphere, (B) activation in the right hemisphere.

Table 1. The comparison of the activity of the Broca's and Wernicke's areas in both hemispheres in the preoperative and postoperative fMRI studies.

fMRI study	Broca's area					Wernicke's area				
	Left hemisphere		Right hemisphere			Left hemisphere		Right hemisphere		
	T	ke	T	ke	LI	T	ke	T	ke	LI
Preoperative	4.83	53	–	–	1	4.39	66	–	–	1
Postoperative 3 months	3.66	7	–	–	1	4.73	22	–	–	1
Postoperative 32 months	7.09	109	6.97	29	0.58	7.9	180	5.90	7	0.93
Postoperative 41 months	4.64	180	4.77	275	–0.21	5.90	244	7.96	450	–0.14

T – values of t-statistics; ke – number of clusters; LI – lateralization index.

the onset of pathological lesions, even though they lie within the so-called eloquent areas [19,20]. Our patient had no new neurological deficits during the 42 months of observation, the language abilities did not change and her communication in everyday life was not disturbed. Only the frequency of seizures increased. In the fourth fMRI study the activation in both the left- and the right-sided Broca's and Wernicke's areas increased. We think that such a long time was needed to induce activation of language areas in the non-affected hemisphere. It is also possible that the recurrence of the tumor was a dominant factor that led to reorganization. Brain plasticity is a dynamic process, language networks can evolve from surgery to surgery or any other changed factor [20,21].

Our study had one limitation. Two different paradigms were used during the procedure. In the first and second fMRI, the patient had to name nouns from the same category, while in the next two fMRI studies, there were 5 different categories. The two tasks might have had a different difficulty level, and the second one was more complicated. Studies conducted in healthy volunteers showed that with increasing difficulty of the task, the activity of homologous non-dominant hemisphere areas increases as

well [22]. Although the activity in the right-sided hemisphere appeared in the third fMRI study, it kept increasing in the fourth study, which proves that it was a continuous process.

In adult patients the capability of the brain for functional recovery is much more limited than in the childhood, and studies on language plasticity in such groups are rare. Additionally, the lack of pre-lesional lateralization for language areas is a common limitation in interpretation of such studies [3,4,7]. What is unique, we presented a running process of reorganization of language areas in a patient after brain tumor resection, from strong left-sided to symmetrical lateralization.

Conclusions

1. fMRI results in comparison with the psychological status of the patient proved contribution of functional reorganization to the preservation of language performance.
2. A slow-growing LGG as well as the recurrence of the tumor near the left Broca's area might be the factors leading to reorganization of language-related areas by recruiting the right hemisphere.

References:

1. Kleim JA, Jones TA: Principles of experience-dependent neural plasticity: implications for rehabilitation after brain damage. *J Speech Lang Hear Res*, 2008; 51: 225–39
2. Duffau H. Brain plasticity: From pathophysiological mechanisms to therapeutic applications. *J Clin Neurosci*, 2006; 13(9): 885–97
3. Thulborn KR, Carpenter PA, Just MA. Plasticity of language-related brain function during recovery from stroke. *Stroke*, 1999; 30(4): 749–54
4. Vicari S, Albertoni A, Chilosi AM et al: Plasticity and reorganization during language development in children with early brain injury. *Cortex*, 2000; 36(1): 31–46
5. Satz P, Strauss E, Whitaker H: The ontogeny of hemispheric specialization: Some old hypotheses revisited. *Brain Language*, 1990; 38(4): 596–614
6. Rosenberg K, Liebling R, Avidan G et al: Language related reorganization in adult brain with slow growing glioma: fMRI prospective case-study. *Neurocase*, 2008; 14(6), 465–73
7. Holodny AI, Schulder M, Ybasco A, Liu WC: Translocation of Broca's area to the contralateral hemisphere as the result of the growth of a left inferior frontal glioma. *J Comput Assist Tomogr*, 2002; 26(6): 941–43
8. Duffau H: Lessons from brain mapping in surgery for low-grade glioma: insights into associations between tumour and brain plasticity. *Lancet Neurol*, 2005; 4: 476–86
9. Rutten GJ, Ramsey NE, van Rijen PC et al: Reproducibility of fMRI-determined language lateralization in individual subjects. *Brain Lang*, 2002; 80(3): 421–37
10. Benson RR, FitzGerald DB, LeSueur LL et al: Language dominance determined by whole brain functional MRI in patients with brain lesions. *Neurology*, 1999; 52(4): 798–809
11. Lehericy S, Cohen L, Bazin B et al: Functional MR evaluation of temporal and frontal language dominance compared with the Wada test. *Neurology*, 2000; 54(8): 1625–33
12. Kapsalakis IZ, Kapsalaki EZ, Gotsis ED et al: Preoperative Evaluation with fMRI of Patients with Intracranial Gliomas. *Radiol Res Pract*, 2012; 2012: 727810
13. Stippich C, Rapps N, Dreyhaupt J et al: Localizing and lateralizing language in patients with brain tumors: feasibility of routine preoperative functional MR imaging in 81 consecutive patients. *Radiology*, 2007; 243(3): 828–36
14. Rutten GJ, Ramsey NE, van Rijen PC, van Veelen CW: Reproducibility of fMRI-determined language lateralization in individual subjects. *Brain Lang*, 2002; 80(3): 421–37
15. Schreiber A, Hubbe U, Ziyeh S, Hennig J: The influence of gliomas and nonglial space-occupying lesions on blood-oxygen-level-dependent contrast enhancement. *Am J Neuroradiol*, 2000; 21(6): 1055–63
16. Gupta SS: fMRI for mapping language networks in neurosurgical cases. *Indian J Radiol Imaging*, 2014; 24(1): 37–43
17. Desmurget M, Bonnetblanc F, Duffau H: Contrasting acute and slow-growing lesions: a new door to brain plasticity. *Brain*, 2007; 130: 898–914
18. Tononi G, Sporns O, Edelman GM: Measures of degeneracy and redundancy in biological networks. *Proc Natl Acad Sci*, 1999; 96(6): 3257–62
19. Niu C, Zhang M, Min Z et al: Motor network plasticity and low-frequency oscillations abnormalities in patients with brain gliomas: a functional MRI study. *PLoS One*, 2014; 9(5): e96850
20. Duffau H, Capelle L, Denvil D et al: Functional recovery after surgical resection of low grade gliomas in eloquent brain: hypothesis of brain compensation. *J Neurol Neurosurg Psychiatry*, 2003; 74(7): 901–7
21. Fakhri M, Oghabian MA, Vedaie F et al: Atypical language lateralization: an fMRI study in patients with cerebral lesions. *Funct Neurol*, 2013; 28(1): 55–61
22. Mattay VS, Weinberger DR: Organization of the human motor system as studied by functional magnetic resonance imaging. *Eur J Radiol*, 1999; 30(2): 105–14