



Received: 2014.07.16  
Accepted: 2014.08.12  
Published: 2015.03.22

Authors' Contribution:

- A** Study Design
- B** Data Collection
- C** Statistical Analysis
- D** Data Interpretation
- E** Manuscript Preparation
- F** Literature Search
- G** Funds Collection

## Embolization of a True Giant Splenic Artery Aneurysm Using NBCA Glue – Case Report and Literature Review

Maciej Guziński<sup>ABCDEF</sup>, Jacek Kurcz<sup>ADEF</sup>, Monika Kukulska<sup>EF</sup>, Małgorzata Neska<sup>EF</sup>, Jerzy Garczarek<sup>ACDE</sup>

Department of General and Interventional Radiology and Neuroradiology, Chair of Radiology, Wrocław Medical University, Wrocław, Poland

Author's address: Maciej Guziński, Department of General and Interventional Radiology and Neuroradiology, Wrocław Medical University, Borowska 213 Str., 50-556 Wrocław, Poland, e-mail: guziol@wp.pl

### Summary

**Background:**

Although splenic artery aneurysms (SAAs) are common, their giant forms (more than 10 cm in diameter) are rare. Because of the variety of forms and locations of these aneurysms, there are a lot of therapeutic methods to choose. In our case of a giant true aneurysm we performed an endovascular embolization with N-butyl-cyano-acrylate (NBCA) glue. To our knowledge it is the first reported case of this method of treatment of true giant SAA.

**Case Report:**

A 74-year-old male patient with symptomatic giant SAA (13 cm) was urgently admitted to our hospital for the diagnostic and therapeutic procedures. Due to the general health condition, advanced age and the large size of the aneurysm we decided to perform an endovascular treatment with N-butyl-cyano-acrylate (NBCA) glue.

**Conclusions:**

The preaneurysmal part of splenic artery was occluded completely with exclusion of the aneurysm. No splenectomy was needed. The patient was discharged in good general condition. Embolization with NBCA can be an efficient method to treat the giant SAA.

**MeSH Keywords:**

Adhesives • Aneurysm • Balloon Occlusion • Spleen

**PDF file:**

<http://www.polradiol.com/abstract/index/idArt/891405>

### Background

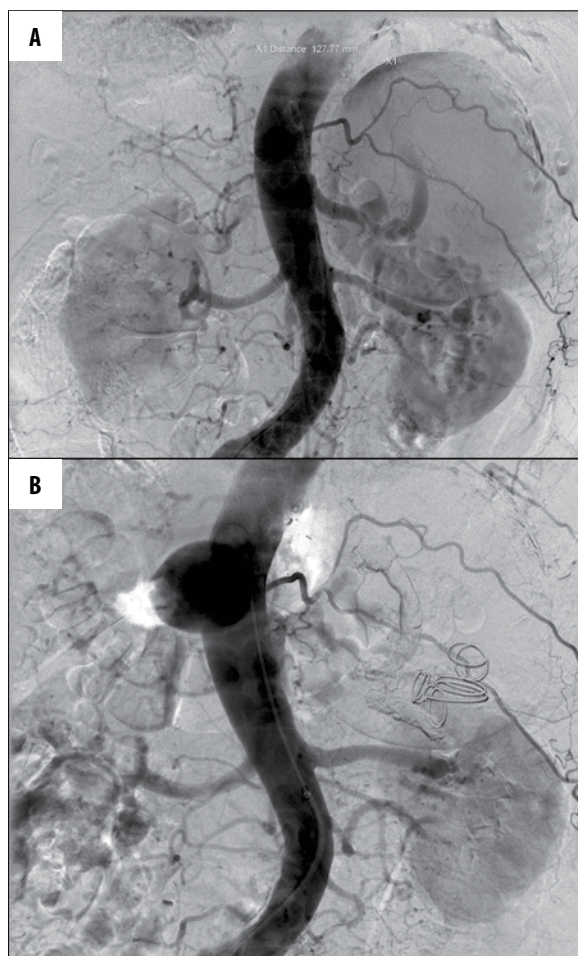
Splenic artery aneurysms (SAAs) constitute 60% of all visceral aneurysms. Only a few cases of giant SAAs, exceeding 10 cm in diameter, were reported on. In spite of high incidence, the algorithm of SAA treatment has not been established so far. The methods of SAA treatment include open or laparoscopic surgery as well as endovascular procedures (transcatheter embolization or stent-graft implantation). The incidence of endovascular techniques in the treatment of SAA has significantly increased in recent years. However, this refers to small aneurysms. Due to rare incidence of giant SAAs, no routine way of treatment has been established.

In our case of a giant SAA, we decided to implement endovascular treatment using a mixture of N-butyl-2-cyanoacrylate and Lipiodol.

### Case Report

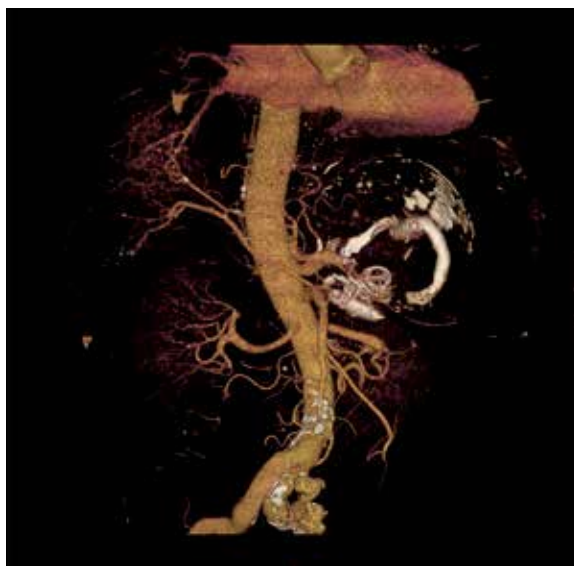
A 74-year-old male, treated earlier for prostate tumor (adenocarcinoma T3 NxMx), was admitted to our hospital due to abdominalgia. On the basis of ultrasound (US) examination the diagnosis of giant splenic artery aneurysm (SAA) was established. The patient's medical history included a chronic non-specific abdominal pain and subfebrile body temperature. The preinterventional blood cell count showed non-significant anaemia (RBC – 4.16 mln/uL, HGB – 12.1 g/dL, HCT 37.4%). Because of patient's advanced age, large SAA diameter, and coexisting cardio-vascular disorders (arrhythmia and arterial hypertension) – after consultation with a vascular surgeon and an interventional radiologist – a less invasive endovascular procedure was recommended as the method of choice.

Arteriography demonstrated a dilated splenic artery with a giant non-clotted high-flow true aneurysm of 13 cm



**Figure 1.** (A) Pre-embolization DSA presenting a giant SAA. (B) Post-embolization DSA demonstrating no contrast flow in the aneurysmal sac. Note the glue material and embolization coils in the lumen of the sac and a round artifact (on the level of the coeliac trunk) arising from the intestinal gas.

in diameter located in the middle portion of the artery. (Figure 1A) We began the interventional procedure with an attempt to close the lumen of the aneurysm with four Inconel coils (two coils of 350×10×15 mm, one coil of 350×10×12 mm, one coil of 350×15×20 mm in size) (MReye®, Cook Medical, Bloomington, IN, USA) and using an 8-mm balloon catheter (Cordis Europa N.V.) introduced into the preaneurysmal portion of the splenic artery, which was ineffective because of high flow in the artery and a wide-necked aneurysmal sac. After closure of inflow into the aneurysmal lumen with an 8×20-mm balloon catheter (Cordis Europa N.V.) we endeavored to close the aneurysmal lumen using 800 I.U. of thrombin (Biomed, Lublin, PL) injected directly into the aneurysmal lumen, which was also inefficient probably because of a high volume of the aneurysm. Finally, the 7-Fr sheath Flexor® Touhy-Borst Side-Arm Introducer Ansel Modification (Cook Medical, Bloomington, IN, USA) was used to catheterize the proximal portion of the splenic artery, and the blood flow was slowed down using an 8×20-mm balloon catheter (Cordis Europa N.V.). Simultaneously, 1.5 mL of Histoacryl® (N-butyl-2-cyanoacrylate, B.Braun Corporation, USA) mixed with 3.0 mL of Lipiodol® (Laboratoire Guerbet, Roissy, France)



**Figure 2.** VR reconstruction CT angiography after embolization with a mixture of NBCA glue and Lipiodol. Occlusion of the distal portion of the splenic artery. The giant aneurysm does not fill with contrast medium. Glue deposits in the splenic artery.

(cumulative concentration 33% and total volume 4.5 mL) was rapidly (3–4 seconds) injected via the Cobra 5-Fr catheter (Cordis, South Ascot, UK) inserted parallelly into the preaneurysmal portion of the splenic artery. Follow-up arteriography demonstrated complete closure of the preaneurysmal portion of the splenic artery. (Figure 1B) Abdominal CT-angiography (CTA) performed 72 hours after the procedure showed clot and embolization material in the aneurysmal sac; no residual opacification was visualized. Upper and lower poles of the spleen demonstrated slight contrast enhancement (most probably via small collateral arterial supply). Proximal 3 cm of the splenic artery showed patency, next portions (embolized with a mixture of histoacryl glue and Lipiodol) and the distal part of the splenic artery did not show contrast enhancement. (Figure 2)

After five days, the patient was released home in a good general health condition. The fact that needs to be stressed is that the patient did not require splenectomy – the arterial supply of the spleen via collaterals proved to be sufficient to avoid splenectomy. Follow-up Doppler US after 3 months demonstrated no flow through the aneurysmal sac.

## Discussion

Aneurysms of the splenic artery, which are predominantly true, are the most common visceral artery aneurysms [1]. SAAs are mostly small (do not exceed a diameter of 3 cm); giant aneurysms (more than 10 cm in diameter) are observed very rarely. Generally, in every age-group SAAs are detected in 0.8% of nonselective angiographies [2]; in autopsy series they are reported in 0.02–0.1%. However, in the age group of over 60 the incidence of SAAs rises up rapidly, even up to 10.4% [3]. In 20% of cases, multiple SAAs are observed. SAAs are in general asymptomatic until a rupture that results in a severe abdominal pain and hypovolemic shock [4]. The estimated rate of SAA rupture is 3%

**Table 1.** Giant SAAs – review of literature.

Author	Year	Diameter (cm)	Age	Sex	Method of treatment
Becker et al. [7]	1973	18	74	M	No data – death
Glover et al. [8]	1982	14	27	F	Ligation
Tam et al. [2]	1988	30	64	M	Laparotomy and splenectomy
Osawa et al. [9]	1991	16	61	F	No data – death
Long et al. [10]	1993	16	78	M	Ligation
Kehagias et al. [11]	1998	12	37	F	Laparotomy and splenectomy
Bornet et al. [12]	2000	11	68	M	Ligation
Qiu et al. [13]	2004	13	73	M	Laparotomy + splenectomy + partial pancreatectomy
Pescarus et al. [6]	2005	15	67	M	Ligation and splenectomy

and rupture-related mortality is 17% [5]. SAAs are located mostly in the distal 1/3 portion of the artery whereas giant aneurysms present more often in middle 1/3 portion – as in our patient [6]. The available data from 1970, related to true giant (>10 cm in diameter) SAAs are presented in Table 1 [7–13]. SAAs were observed most commonly in the sixth and seventh decade of life, predominantly in male patients (7 of 10 cases). None of them was treated only endovascularly.

The decision on the method of treatment is made on the basis of estimation of procedure-related risk. An interventional procedure should also be performed when a splenic aneurysm is found: in every patient with an aneurysmal sac larger than 2 cm (>1 cm in pregnant women or women in childbearing age), in patients with an aneurysm increasing in size, or with indications for liver transplantation, and last but not least, in case of false aneurysms. The clinical sign of symptomatic SAA is left epigastric pain that occasionally radiates to the left subscapular area [5]. The diagnosis should be made on the basis of imaging modalities such as Doppler US, CTA, or alternatively conventional angiography. It should be added that a calcified aneurysmal sac wall can be visualized (like in our patient) with plain abdominal X-rays in 2/3 of patients. It should be also stressed that Doppler US examination is in most cases good enough to establish the diagnosis of aneurysms larger than 2 cm in patients of normal size. However, in case of obese patients, or those not well prepared for US, the small and medium-sized aneurysms can be overlooked.

Nowadays laparotomy is the primary method of SAA treatment in most of the centers. Another commonly used method is laparoscopy. By means of laparoscopic procedure the aneurysm may be excised or excluded from the circulation by splenic artery ligation. This kind of treatment is performed in case of middle-sized aneurysms (2–6 cm in diameter). Laparoscopy is preferably carried out when the aneurysm is localized distally in the splenic artery [14].

Thanks to development of invasive radiology techniques, endovascular SAA embolization has become more popular in recent years. The method can be implemented in most cases of SAA. When portal hypertension (associated with

increased risk of SAA development) coexists, endovascular intervention is recommended. The effectiveness of the method is high and amounts to 80–92% [4]. The most efficient results are achieved in the treatment of small and middle-sized saccular aneurysms using stent-grafts [1]. In case of giant aneurysms there is a high risk of stent-graft migration into the aneurysmal sac. Moreover, in giant SAAs it can be difficult or even impossible to catheterize the distal (postaneurysmal) portion of the splenic artery and the catheterization-related risk of aneurysmal sac rupture is increased. Nowadays, the use of vascular occluders constitutes the most popular method of endovascular treatment of giant SAAs. However, we do not have sufficient experience with occlusion of giant high-flow SAAs by means of occluders, and that is why we decided to use an alternative method of endovascular embolization. Another technique is embolization with the use of free metal coils. This constitutes an efficient method of treatment of aneurysms with a narrow neck and without a high-flow aneurysmal sac. When treatment of proximally located giant aneurysms is being performed, the risk of coil migration into the lumen of other arteries (with potentially dangerous vascular complications) should be taken into account [5].

Embolization with a mixture of histoacryl glue and Lipiodol seems to be a good alternative technique when complete occlusion of the aneurysmal sac using only metal coils is impossible, like in case of giant high-flow aneurysms. The first SAA embolization with histoacryl glue was reported on in 2003 by Lupatelli et al., who performed secondary occlusion of a 4-cm SAA in a patient with a liver transplant [3].

The procedure should be carried out by experienced interventional radiologists. Firstly, it is necessary to slow down the hyperkinetic flow in a dilated artery in a proper way and secondly to select the proper density of the mixture of N-butyl-2-cyanoacrylate and Lipiodol to avoid such complications as migration of the mixture of glue from the injection site resulting in embolization of additional vessels (in case of weakened mixture) or intracatheter embolization (in case of dense mixture) or pasting the balloon to the arterial wall. It is also essential to flush the catheter

accurately with a minimum of 5 mL of 5% solution of glucose each time before glue injection.

## Conclusions

Embolization of a giant SAA in the presented patient was a difficult procedure because of both the size of the

aneurysm and the hyperkinetic flow in the aneurysmal sac. Nevertheless, the treatment proved successful without peri- or post-procedure complications. Particular attention should be paid to the fact that despite complete aneurysmal sac occlusion, the patient avoided splenectomy thanks to the small collateral circulation supplying the spleen.

## References:

1. Croner RS, Anders K, Uder M, Lmag W: Aneurysmen viszeraler Arterien. *Dtsch Arztebl*, 2006; 103(20): 1367-71 [in German]
2. Tam TN, Lai KH, Tsai YT et al: Huge splenic artery aneurysm after portocaval shunt. *J Clin Gastroenterol*, 1988; 10: 565-68
3. Lupattelli T, Garaci FG, Sandhu C et al: Endovascular treatment of giant splenic aneurysm that developed after liver transplantation. *Transpl Int*, 2003; 16: 756-60
4. Guillon R, Garcier JM, Abergel A et al: Management of Splenic Artery Aneurysms and False Aneurysms with Endovascular Treatment in 12 Patients. *Cardiovasc Intervent Radiol*, 2003; 26(3): 256-60
5. Halloul Z, Meyer F, Grote R et al: Selective embolization of splenic artery aneurysm – case report. *Eur J Surg*, 2005; 37(1): 59-62
6. Pescarus R, Montreuil B, Bendavid Y: Giant splenic artery aneurysms: Case report and review of the literature. *J Vasc Surg*, 2005, 42: 344-47
7. Becker JA, Twersky J, Kinkhabwala M: Giant aneurysm of the splenic artery. *Br J Radiol*, 1973; 46: 419-23
8. Glover SG, Smith CC, Engeset J, Koruth NM: Unusual presentation of giant splenic artery aneurysm. *Br J Surg*, 1982; 69: 247
9. Osawa M, Masui M, Wakasugi C: Rupture of a giant splenic artery aneurysm. Report of an autopsy case. *Am J Forensic Med Pathol*, 1991; 12: 337-39
10. Long CD, Bakshi KR, Kahn MB, Roberts AB: Giant splenic artery aneurysm. *Ann Vasc Surg*, 1993; 7: 474-78
11. Kehagias DT, Tzalonikos MT, Mouloupoulos LA et al: MRI of a giant splenic artery aneurysm. *Br J Radiol*, 1998; 71: 444-46
12. Bornet P, Medjoubi SA, Tissot A et al: Giant aneurysm of the splenic artery – a case report. *Angiology*, 2000; 51: 343-47
13. Qiu JF, Xu L, Wu ZY: Diagnosis and surgical treatment of giant splenic artery aneurysms with portal hypertension: report of 4 cases. *Hepatobiliary Pancreat Dis Int*, 2004; 3: 526-29
14. Pietrabissa A, Ferrari M, Berchiolli R et al: Laparoscopic treatment of splenic artery aneurysms. *J Vasc Surg*, 2009; 50(2): 275-79