



Received: 2016.07.02
Accepted: 2016.09.04
Published: 2017.05.16

Authors' Contribution:

- A** Study Design
- B** Data Collection
- C** Statistical Analysis
- D** Data Interpretation
- E** Manuscript Preparation
- F** Literature Search
- G** Funds Collection

Delayed Small Bowel Perforation with Findings of Severe Ischemia Following Blunt Abdominal Trauma

Sehnaz Evrimler^{1A,EF}, Irfan Okumuser^{1D}, Deniz Delibas^{2G}

¹ Department of Radiology, Kutahya Tavsanlı State Hospital, Kutahya, Turkey

² Department of Radiology, Medical Park Tarsus Hospital, Mersin, Turkey

Author's address: Sehnaz Evrimler, Department of Radiology, Kutahya Tavsanlı State Hospital, Kutahya, Turkey,
e-mail: drsehnaz@gmail.com

Background:

Isolated small bowel perforation following blunt abdominal trauma (BAT) is an uncommon situation with high morbidity and mortality rates, and delayed small bowel perforation is even rarer. The pathophysiology of this condition is not clear in all cases. To the best of our knowledge, this is the first case report of delayed small bowel perforation following BAT with extensive portomesenteric vein gas.

Case Report:

A 33-year-old male patient was admitted to the emergency department after a car accident. His initial abdominal CT showed no signs of posttraumatic injury. However, follow-up CT, performed after deterioration in his general condition, showed jejunal dilatation, intestinal intramural gas, portomesenteric vein gas, extensive intraperitoneal gas and intraabdominal free fluid. CT findings and emergent laparotomy findings were both compatible with small bowel ischemia-necrosis and perforation.

Conclusions:

Delayed small bowel perforation following BAT is thought to occur secondary to mesenteric hematoma formation or mesenteric tear complications. Our patient did not have any mesenteric injury or hematoma on initial abdominal CT. We are not aware of any other case report of delayed small bowel perforation following BAT without signs of intraabdominal injury on initial imaging and extensive portomesenteric vein gas on follow-up imaging. Ischemic bowel necrosis was the main cause of portomesenteric vein gas in our case. Posttraumatic patients should be kept under medical observation and abdominal CT should be preferred for imaging in case of a deterioration in the general condition and laboratory findings or appearance of new abdominal complaints.

MeSH Keywords:

Abdominal Injuries • Intestinal Perforation • Ischemia • Multidetector Computed Tomography

PDF file:

<http://www.polradiol.com/abstract/index/idArt/900382>

Background

Isolated small bowel perforation following blunt abdominal trauma (BAT) is an uncommon situation in comparison to a penetrating injury and it has comparatively high morbidity and mortality rates. A blow-out perforation at the antimesenteric site due to a sudden increase in intraluminal pressure explains the pathophysiology [1–4]. A delayed small bowel perforation following BAT is even rarer. So far, only 10 case reports (12 patients) have been reported in the English literature. Most of them occurred after motor vehicle accidents. The mechanism of intestinal perforation was not clear in all of these cases. Mesenteric hematoma or mesenteric tear was depicted in only 5 of the 12 cases.

Postoperative findings included intestinal ischemia features such as intestinal wall edema and necrosis. The presentation delay ranged from 8 hours to 77 days [4–13].

To the best of our knowledge, this is the first case report of delayed isolated small bowel perforation with ischemia and extensive portomesenteric vein gas. We aim to remind physicians of the importance of medical observation of posttraumatic patients in order not to omit delayed isolated small bowel ischemia and perforation following BAT, which is associated with high morbidity and mortality rates.

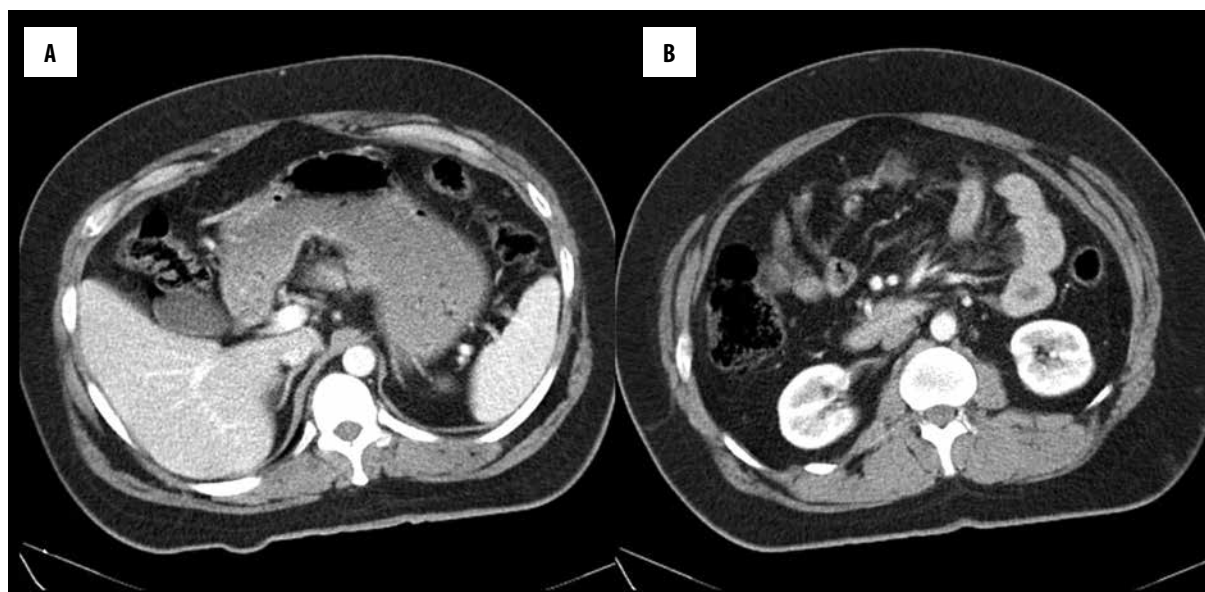


Figure 1. There is no sign of parenchymal organ or mesenteric injury, intraperitoneal free fluid or gas on axial images on the initial contrast-enhanced abdominal CT at the level of portal vein (A) and superior mesenteric vein branches (B).

Case Report

A 33-year-old male patient was admitted to the emergency department after a car accident. His initial complete blood count and biochemistry results were normal. His general condition and physical examination were normal except for a tibial fracture. Non-enhanced cranial computerized tomography (CT) as well as thoracic and abdominal CT with intravenous (iv) nonionic iodinated contrast material (100cc, 5 cc/sec through 18 gauge iv catheter) were acquired in the portal venous phase using 16-sliced MDCT (Siemens Somatom Emotion). There was no sign of posttraumatic injury in these examinations. There was no intraabdominal free fluid or gas, mesenteric injury or parenchymal intraabdominal organ injury on abdominal CT images (Figure 1). The patient was put under medical observation in the orthopedics ward because of the tibial fracture. Twenty hours after admission, another abdominal CT scan was performed because of a deterioration in the general condition. Jejunal dilatation, intestinal intramural gas, portomesenteric vein gas, intraperitoneal-extramural gas and intraabdominal fluid were detected on the second abdominal CT (Figures 2, 3). The findings were compatible with small bowel ischemia-necrosis and perforation. The patient was sent for an emergent laparotomy. The postoperative findings showed jejunal wall necrosis and perforation. During the postoperative observation in an intensive care unit, the values of CRP, BUN and creatinine were increased to 430 mg/dl, 55 mg/dl, 2.18 mg/dl, respectively, in five days. The patient died on the 5th day since the accident.

Discussion

The occurrence of the rare instances of isolated small bowel perforation following BAT is explained as a blow-out perforation at the antimesenteric site due to a sudden increase in intraluminal pressure [1–3]. However, this mechanism does not adequately explain the cause of delayed small bowel ischemia and perforation after BAT.

Posttraumatic mesenteric injury can cause bleeding and ischemia. Mesenteric tear and secondary hematomas can result in ischemia because of decreased blood supply. As regards delayed cases, fibrosis during the healing period is considered as a cause of obstruction and perforation due to stricture formation [5,14]. Mesenteric hematomas or mesenteric tear were depicted in only 5 of the 12 cases published in the literature and were confirmed postoperatively as intestinal wall necrosis, ischemia and perforation. The presentation delay ranged from 8 hours to 77 days. The earliest delay was in seen the case reported by Bas et al. (8 hours) [4–13].

Our case is the second earliest presentation and occurred within 20 hours of admission. In our case, the initial abdominal CT scan showed no signs of mesenteric injury or mesenteric hematoma. However, severe mesenteric ischemia findings – portomesenteric vein gas, jejunal intramural gas and intestinal obstruction as well as perforation findings – jejunal dilatation, intraabdominal free gas and fluid were detected on the second abdominal CT. We are not aware of any other case report of delayed small bowel perforation following BAT without signs of intraabdominal injury on initial imaging and extensive portomesenteric vein gas on follow-up imaging. Intestinal wall alterations (ischemic bowel necrosis, perforated gastric carcinoma or ulcer, ulcerative bowel diseases), bowel distention and sepsis are the main causes of portomesenteric vein gas, but approximately 15% of cases are idiopathic. Mesenteric ischemia is the major cause in most adult patients [15,16]. Ischemic bowel necrosis was the main cause of portomesenteric vein gas in our case.

If there is no direct bowel injury or serious mesenteric injury, surgery is not necessary in patients in a stable general condition, and conservative treatment with a close follow-up is generally sufficient [5]. Conventional radiography can be used for follow-up imaging of pneumoperitoneum. Ultrasonography can detect free fluid and parenchymal

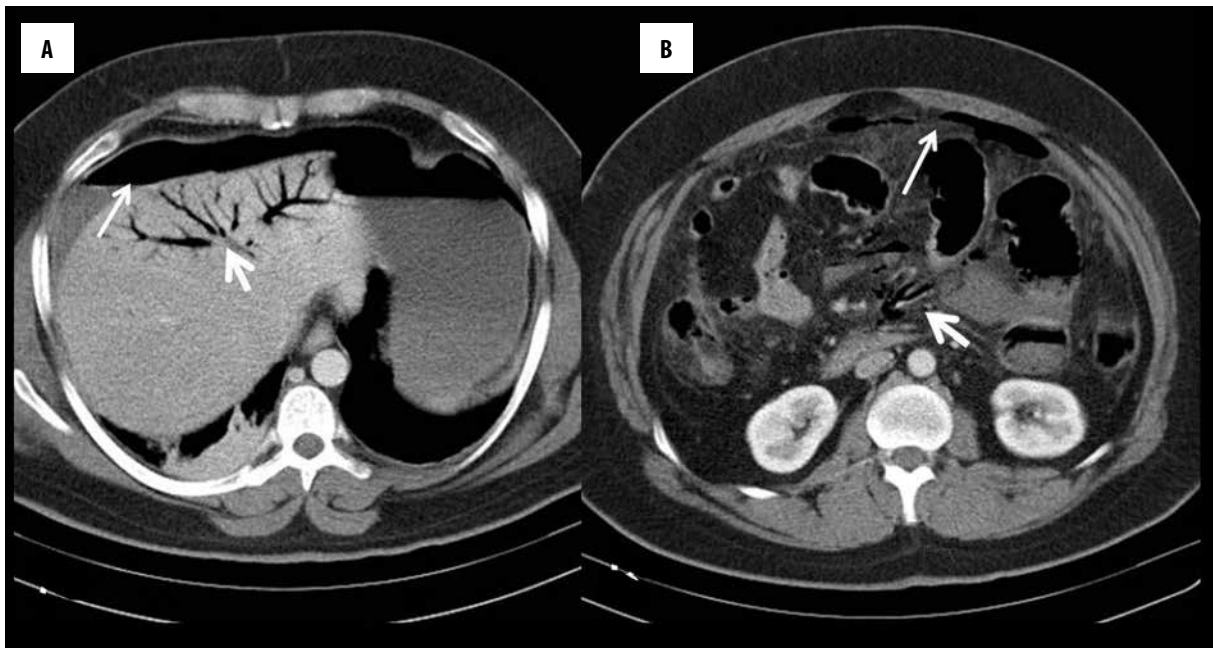


Figure 2. Axial images from the second contrast-enhanced abdominal CT scan show portal vein gas (thick arrow) and intraperitoneal free gas (long arrow) (A). Superior mesenteric vein gas (thick arrow) and pneumoperitoneum (long arrow) are seen (B).

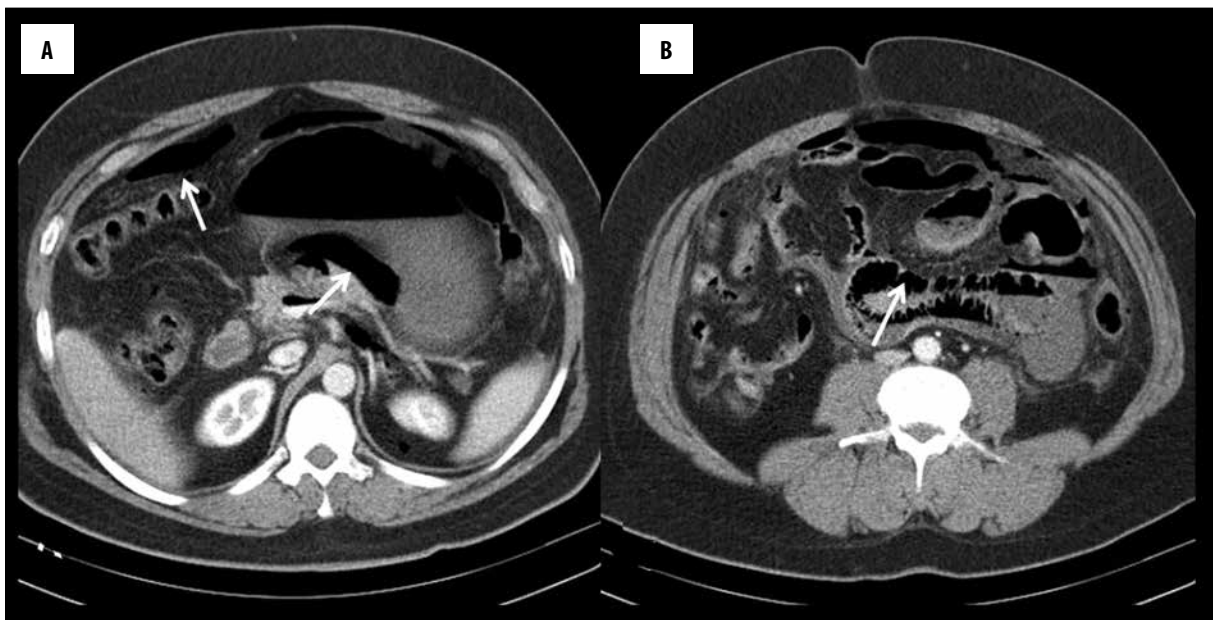


Figure 3. Pneumoperitoneum (arrow) (A), jejunal dilatation and intramural air (arrow) are detected on axial images from the second contrast-enhanced abdominal CT (B).

organ injury, but mesenteric injury and bowel injuries cannot be visualized directly [18]. Abdominal CT is more sensitive for both pneumoperitoneum and portomesenteric vein gas detection [15–18]. Therefore, abdominal CT can be preferred as the imaging modality of choice for posttraumatic patients under observation who have a deterioration in the general condition and laboratory findings or develop new abdominal complaints.

Conclusions

In conclusion, physicians should keep in mind that delayed isolated small bowel ischemia and perforation with high morbidity and mortality rates can occur following BAT. Therefore, posttraumatic patients should be kept under medical observation.

Acknowledgments

We gratefully acknowledge Burcu Erbay for her contributions.

References:

1. Watts DD, Fakhry SM, EAST Multi-Institutional Hollow Viscus Injury Research Group: Incidence of hollow viscus injury in blunt trauma: An analysis from 275,557 trauma admissions from the East multi-institutional trial. *J Trauma*, 2003; 54: 289–94. Erratum in: *J Trauma*, 2003; 54: 749
2. Fakhry SM, Watts DD, Luchette FA, EAST Multi-Institutional Hollow Viscus Injury Research Group: Current diagnostic approaches lack sensitivity in the diagnosis of perforated blunt small bowel injury: Analysis from 275,557 trauma admissions from the EAST multi-institutional HVI trial. *J Trauma*, 2003; 54: 295–306
3. Goyal S, Goyal S, Garg MK: Single jejunal blowout perforation following blunt abdominal trauma: Diagnostic dilemma. *J Mahatma Gandhi Inst Med Sc*, 2013; 18(2): 144–46
4. Bas K, Besim H: Delayed diagnosis of isolated jejunal perforation following blunt abdominal trauma. *Cumhuriyet Tıp Derg*, 2013; 35: 120–23
5. Jahromi AH, Johnson I, Youssef AM: Delayed small bowel perforation following blunt abdominal trauma: A case report and review of the literature. *Asian J Surg*, 2016; 39: 109–12
6. How PD, Feddo H, Woo E, Huang A: Delayed ileal perforation secondary to traumatic stricture presenting as pyrexia of unknown origin. *Ulus Travma Acil Cerrahi Derg*, 2009; 15: 185–87
7. Subramanian V, Raju RS, Vyas FL et al: Delayed jejunal perforation following blunt abdominal trauma. *Ann R Coll Surg Engl*, 2010; 92: W23–24
8. Coats TJ: Delayed presentation of perforation of the ileum following seat belt trauma. *Arch Emerg Med*, 1991; 8: 144–46
9. Maull KI, Rozycki GS: Delayed presentation of traumatic blunt small bowel perforation. *J Tenn Med Assoc*, 1986; 79: 287–88
10. Winton TL, Girotti MJ, Manley PN, Sterns EE: Delayed intestinal perforation after nonpenetrating abdominal trauma. *Can J Surg*, 1985; 28: 437–39
11. Ross WB, Bickerstaff DR: Late jejunal perforation following blunt injury. *Injury*, 1985; 16: 481
12. Fleishman HA, Griffith GL, Bivins BA: Delayed perforation of small bowel following blunt abdominal trauma. *J Ky Med Assoc*, 1979; 77: 294–95
13. Burrell M, Toffler R, Lowman R: Blunt trauma to the abdomen and gastrointestinal tract. Plain film and contrast study. *Radiol Clin North Am*, 1973; 11: 561–78
14. Northcutt A, Hamidian Jahromi A, Johnson L, Youssef AM: Unusual late occurrence of bowel obstruction following blunt abdominal trauma. *J La State Med Soc*, 2011; 163: 305–7
15. Liebman PR, Patten MT, Manny J et al: Hepatic-portal venous gas in adults: Etiology, pathophysiology and clinical significance. *Ann Surg*, 1978; 187: 281–87
16. Sebastia C, Quiroga S, Espin E et al: Portomesenteric vein gas: Pathologic mechanisms, CT findings, and prognosis I. *Radiographics*, 2000; 20: 1213–24
17. Earls JP, Dachman AH, Colon E et al: Prevalence and duration of postoperative pneumoperitoneum: Sensitivity of CT vs. left lateral decubitus radiography. *Am J Roentgenol*, 1993; 161: 781–85
18. Fakhry SM, Watts DD, Luchette FA, EAST Multi-Institutional Hollow Viscus Injury Research Group: Current diagnostic approaches lack sensitivity in the diagnosis of perforated blunt small bowel injury: Analysis from 275,557 trauma admissions from the EAST multi-institutional HVI trial. *J Trauma*, 2003; 54: 295–306