



Received: 2016.07.11
Accepted: 2016.07.14
Published: 2017.05.10

Authors' Contribution:

- A** Study Design
- B** Data Collection
- C** Statistical Analysis
- D** Data Interpretation
- E** Manuscript Preparation
- F** Literature Search
- G** Funds Collection

Imaging Diagnosis of a Rare Presacral Tumour

Hemal Grover^{1ABCDEF}, Amrit Pal Ahluwalia^{2ACDEF}, Sanjay Sethi^{2DE}

¹ At the time of study: Postgraduate Resident, Department of Radiology & Imaging, Government Medical College and Rajindra Hospital, Patiala, Punjab, India; Currently, Department of Neuro-Radiology, New York Medical University, New York, NY, U.S.A.

² Department of Radiology and Imaging, Government Medical College and Rajindra Hospital, Patiala, Punjab, India

Author's address: Hemal Grover, Apartment no 6J, 30 Water side Plaza, New York, NY 10010, U.S.A.,
e-mail: hemalgrover@gmail.com

Summary

Background:

Primary tumors in the presacral (retrorectal) space are extremely rare in adults, with an estimated incidence of 0.0025 to 0.014 in large referral centers. Congenital varieties are most common and comprise two thirds of these tumors. Primary retroperitoneal sarcomas in the pelvic region are extremely rare. We report the ultrasound and the corresponding Computed Tomography (CT) features of a rare presacral fibrosarcoma in an adult woman, in whom the diagnosis was confirmed by a CT-guided biopsy.

Case Report:

A 54-year-old woman presented with a history of lumbar and perineal pain and painful defecation. Rectal examination revealed a hard mass in the retrorectal space. The patient was referred for imaging and a laboratory evaluation with a clinical diagnosis of a presacral mass. An abdominal ultrasound was followed by laboratory evaluation of routine hematological and hepato-renal parameters, abdomino-pelvic CT and a CT-guided biopsy.

The imaging studies showed a presacral solid mass with nodular calcifications. There was conspicuous absence of cystic or adipose contents and of sacral erosion/destruction. However, hepatic metastasis was present. All imaging features suggested a retroperitoneal sarcoma in the pelvic region with metastases to the liver. The diagnosis was confirmed by CT-guided biopsy.

Conclusions:

We are reporting a new case of a very rare entity, a presacral fibrosarcoma. The imaging approach and the analysis leading to an appropriate differential diagnosis and final diagnosis is highlighted in our case report.

MeSH Keywords:

Adult • Fibrosarcoma • Computed Tomography • Presacral Region • Ultrasound

PDF file:

<http://www.polradiol.com/abstract/index/idArt/900522>

Background

Common diseases of the pelvic retroperitoneum include lymphadenopathy and extension of an abscess or infection from the rectal area [1]. Primary tumors in the presacral (retrorectal) space are extremely rare in adults, with an estimated incidence of 0.0025 to 0.014 in large referral centres [2]. In this compartment, tumors are diverse due to the different types of tissues from which they can originate [2]. The retrorectal compartment contains not only the embryologic hindgut but also the neuroectoderm and bony pelvis [2]. Presacral tumors are classified as being of congenital, neurogenic, osseous or miscellaneous origin [2,3]. Congenital varieties are most common and comprise two

thirds of tumors in this location. They include the dermoid and epidermoid cysts, duplication cysts, anterior meningoceles, chordomas, teratomas and adrenal rest tumors [2,3]. The majority of these are benign, however, malignant transformation has been reported in duplication and epidermoid cysts [2,3]. The less common primary retroperitoneal tumors in the pelvic region include chordomas and the tumors arising from neural elements such as neurofibromas, paragangliomas and schwannomas as well as extraintestinal gastrointestinal stromal tumors (GIST) and primary bone tumors [1,3,4]. Primary retroperitoneal sarcomas in the pelvic region are extremely rare and are listed amongst the miscellaneous group of presacral tumors in most reports [3,5,6]. The characteristic nature of retrorectal

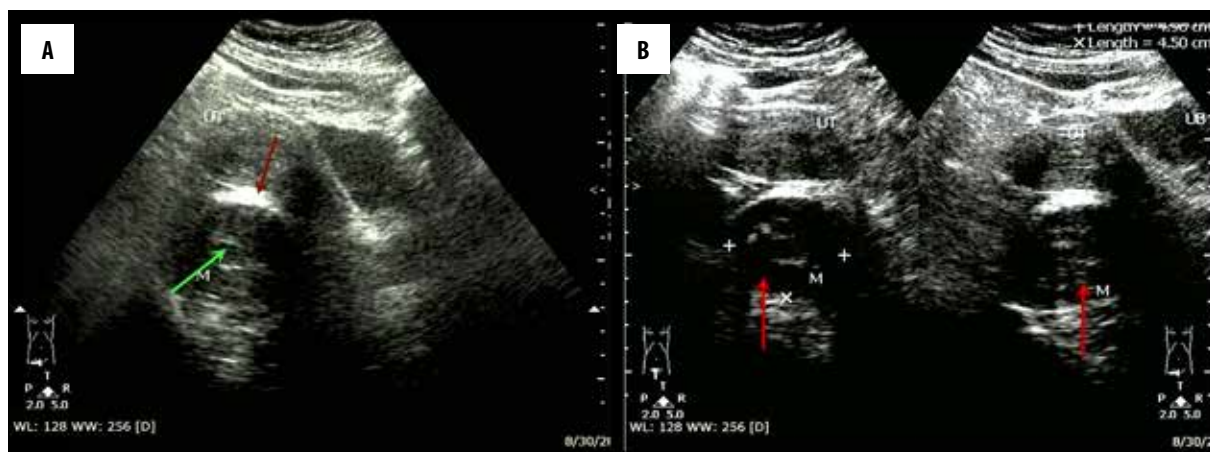


Figure 1. (A) Ultrasound examination of the pelvic region reveals a homogeneously hypoechoic solid mass in the presacral region, which compresses the rectum (echogenic rectal air denoted by red arrow) and showing foci of nodular calcifications (green arrow). (B) Ultrasound examination of the pelvic region reveals a homogeneously hypoechoic solid mass in the presacral region (red arrows), which measures 4.6×4.9 cm in size (measurements shown in the upper right corner).

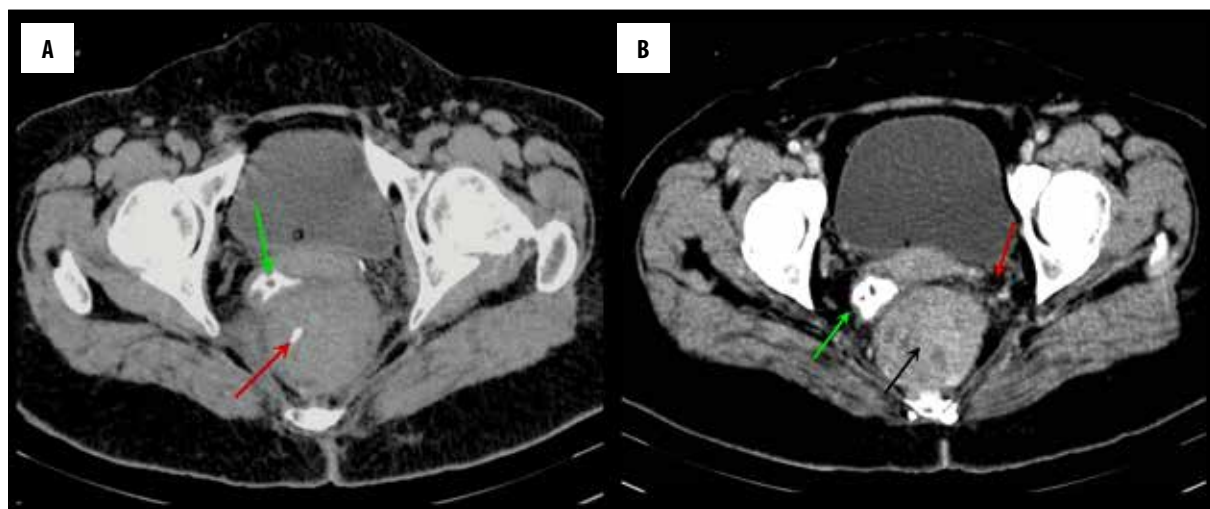


Figure 2. (A) Non-contrast-enhanced CT scan of the pelvis reveals a solid presacral tumour with foci of calcifications, (red arrow), which compresses and displaces the contrast-filled rectum (green arrow) to the right side. (B) Contrast-enhanced CT scan of the pelvis reveals a moderately enhancing presacral tumour with necrotic foci (black arrow) and peri-tumoral infiltration (red arrow). The rectum is compressed and displaced to the right side (green arrow).

tumors is that they are either asymptomatic or present with nonspecific symptoms, which delays the diagnosis in majority of patients [2,3]. We report the ultrasound and correlating Computed Tomography (CT) appearances of a rare pre sacral fibro-sarcoma in an adult female, the diagnosis was confirmed by CT guided biopsy in this patient. The imaging approach and the analysis leading to an appropriate differential diagnosis is presented in our report, as we describe the signature signs of the more frequent presacral tumors, which were all excluded in our patient.

Case Report

A 54-year-old female patient presented with a lower back pain, obstipation, painful defecation and severe pain in the pelvic and perineal regions. Rectal examination revealed a hard mass in the retrorectal space. The patient was referred for ultrasound with a clinical diagnosis of a presacral mass. An abdominal ultrasound was followed by a routine

laboratory evaluation of hematological and hepato-renal parameters, abdomino-pelvic CT and a CT-guided biopsy.

Results

Abdominal ultrasound revealed a sharply defined, solid tumor in the presacral region, measuring 4.9×4.6 cm in size, showing foci of calcifications and negligible vascularity (Figure 1A, 1B). The rectal air (seen as a linear echogenic structure) was markedly compressed between the presacral tumor and the uterus (Figure 1A, 1B). The urinary bladder, uterus and sacrum, however, appeared normal. Multiple liver metastases were seen. The ultrasound findings suggested a solid tumor in the presacral region with liver metastasis. A CT scan was performed for further evaluation, which was obtained with both rectal and intravenous contrast enhancement. The CT appearance was similar to that found on the ultrasound examination, and revealed a moderately enhancing presacral tumor with necrotic foci and

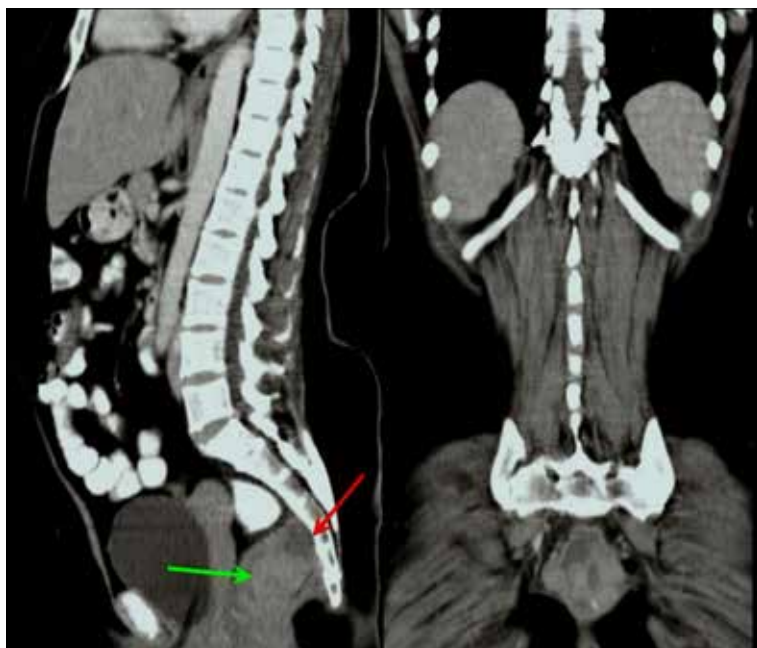

Figure 3. Contrast-enhanced CT scan of the pelvis in sagittal and coronal reformats reveals a solid, moderately enhancing presacral tumour (green arrow) causing mild scalloping of the sacrum (red arrow).

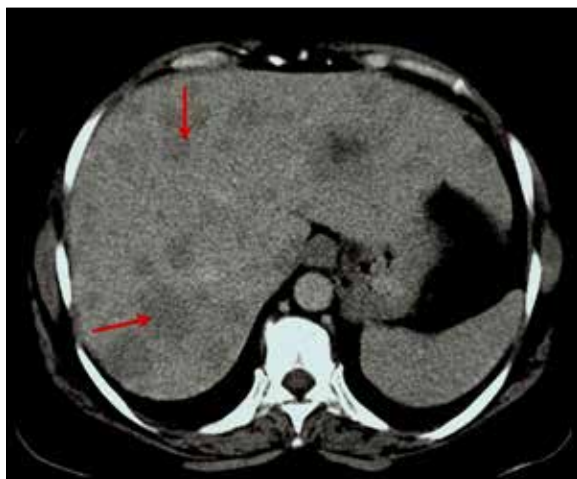

Figure 4. Contrast-enhanced CT scan of the upper abdomen shows multiple non-enhancing metastases (red arrows).

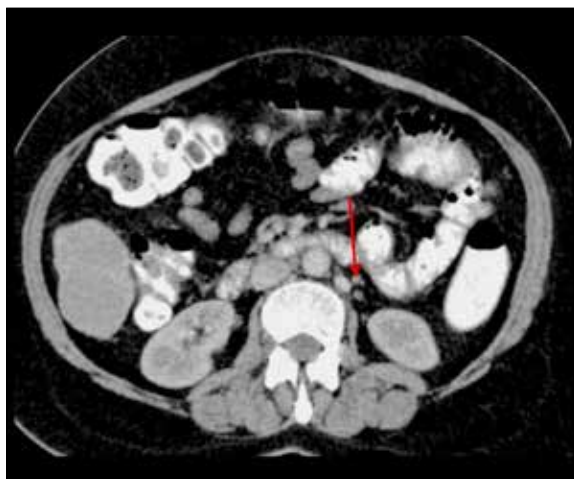

Figure 5. Contrast-enhanced CT scan of the upper abdomen shows multiple subcentimeter paraaortic lymph nodes (red arrow).

surrounding infiltration. The rectum (opacified with rectal contrast) was seen to be markedly compressed and deviated to the right lateral location (Figure 2A, 2B). The tumor was abutting the sacral surface and the sacrum revealed scalloping due to a long-standing compression (Figure 3). Multiple liver metastases (Figure 4), paraaortic and iliac lymph node metastases (Figures 5, 6) were seen. The imaging findings of a presacral solid mass with nodular calcifications, the conspicuous absence of cystic or adipose contents and of sacral erosion and the presence of hepatic and lymph node deposits at initial presentation, all suggested a retroperitoneal sarcoma in the pelvic location. The laboratory tests showed mildly elevated hepatic parameters and prolonged prothrombin time. After 48 hours of Vitamin K therapy, a CT-guided biopsy was performed through the gluteal approach, which revealed a presacral fibrosarcoma. The final diagnosis was that of a retroperitoneal fibrosarcoma in presacral region, with lymph node and liver metastases. The patient and her family refused any treatment, including chemotherapy and

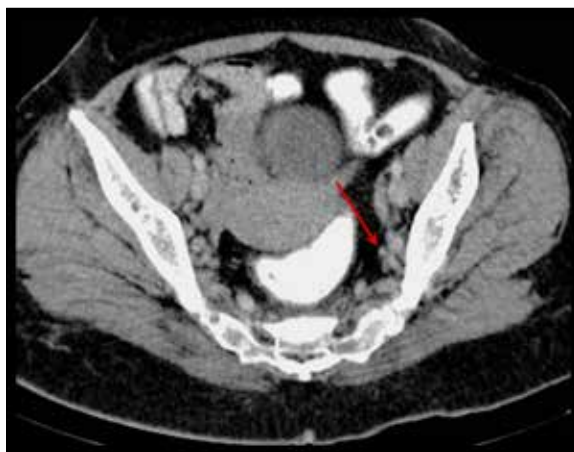

Figure 6. Contrast-enhanced CT scan of the lower abdomen shows multiple subcentimeter internal iliac lymph nodes (red arrow).

surgery. An informed consent for publication of this report was however given by the patient, who was then lost to follow-up.

Discussion

The retrorectal space or the presacral region is part of the pelvic retroperitoneum [1]. The boundaries of the presacral region are the posterior wall of rectum and the anterior surface of sacrum [1–3]. The superior margin is the peritoneal reflection and the inferior margin is the supralelevator space. On its lateral aspect, there are ureters, iliac vessels and sacral nerve roots as well as the endopelvic fascia forming the lateral ligaments [2,3]. As symptoms are usually delayed, tumors may attain a large size and malignant ones may even metastasize prior to diagnosis. Our patient had multiple liver metastases at initial diagnosis. When symptoms do occur, they include a long-standing low back or perineal pain, altered bowel habits or dysuria [2,3].

Imaging not only confirms the location of the disease and shows its nature (cystic or solid), but also further characterizes it based on the involvement/invasion of the surrounding structures or an extension beyond the pelvic cavity. The treatment plan, including surgery, is based on the imaging results [2,3]. CT and MRI are complementary techniques, as CT is superior in demonstrating cortical bone destruction, detecting calcific components and also the distant metastases. MRI on the other hand remains superior in delineating all soft tissue structures and neural relationships [2,5]. The case reported by us, highlights the vital role of imaging in narrowing down the differential diagnosis and finally confirming the diagnosis by imaging guided biopsy. Imaging, therefore is vital in planning the treatment. We enumerate below, the characteristic imaging features of the more frequent presacral tumors and also discuss the differential diagnosis of this rare presacral tumor.

The presacral region contains structures derived from the embryonic neuroectoderm, notochord and hindgut, and many tumors arise from these embryonic remnants [2,3]. The tumors arising from the embryonic remnants are developmental cysts (dermoid and epidermoid), duplication cysts and anterior meningoceles [2,3]. Imaging features are invaluable in characterizing the origin of these tumors. The “H” value of fluid on CT and a hypointense appearance on T1-W MRI with hyperintensities in T2-W sequences are characteristic of cystic tumors. It is known that dermoid and epidermoid cysts are usually unilocular, whereas tail gut cysts appear multilocular in the form of multiple conglomerate small cysts adjoining a large cyst [2]. Anterior sacral meningocele and myelo-meningocele are known to reveal on conventional radiographs, a unilateral sacral defect named as the “Scimitar sign” (sacrum with a rounded concave border), without bony destruction [3]. On MRI, the fluid-filled cyst of the meningocele is seen to communicate with the thecal sac through a stalk [2].

Solid tumors in the pre-sacral region include tumors of a neurogenic origin, chordomas and other osseous tumors [2–4]. A neural origin of a tumor is suggested when there is a neural foraminal widening or erosion. Any tumor of a neurogenic origin appears as a nodular extension of the

mass along the expected course of the nerve with stretching of the nerve [5]. Neurogenic tumors show a low signal in T1-W sequences and a high signal on T2-W MRI scans as well as a whorled pattern of enhancement [5].

On imaging, chordomas typically show sacral destruction with intra sacral (bony) components, along with the pre- and post sacral components. This tumor type shows a mixed signal intensity on T2W sequences [4]. Other osseous tumors extending into the retrorectal region are osteomas, osteogenic sarcomas, giant cell tumors and the Ewing’s sarcomas of sacral origin [3,4,6]. Radiography and CT exquisitely display the characteristic bone abnormalities in all these tumors, which is vital for arriving at an accurate diagnosis. The soft tissue component of bone tumors is better evaluated by MRI and therefore both CT and MRI are complimentary to each other in this clinical setting [5,6]. The soft tissue component is usually of a low signal on T1 W MR and hyperintense in T2-W MR sequences due to both hemorrhage and necrosis. MRI remains unparalleled for evaluating the invasion of the surrounding pelvic organs regardless of the nature of the primary tumor [6].

Uncommon etiologies of presacral tumors in adults are gastrointestinal stromal tumors (GIST), extraadrenal pheochromocytomas, lymphangiomas and pelvic arterio-venous malformations (AVM) [1]. Gastrointestinal stromal tumors in the retrorectal space may arise from the rectal wall or from the retroperitoneum. These tumors show a low signal on T1-W scans and an intermediate to high signal on T2-W images as well as a significant enhancement after gadolinium [1]. Pheochromocytomas are solid tumors associated with hypertension and characteristically show an intense contrast enhancement on CT or MRI [1]. Pelvic arterio-venous malformations are seen as cystic masses with phleboliths on CT and show flow voids on MR Imaging [1].

Tumors of a sarcomatous origin are classified as the extremely rare “miscellaneous” group by most investigators [3,6]. Fibrosarcomas are even rarer, as most sarcomas described in previous reports, were lipomatous [5,6]. One of the remarkable early reports on the primary retroperitoneal fibrosarcomas is that by McNamara et al., who described 8 primary retroperitoneal fibrosarcomas amongst 2500 routine adult autopsies and concluded that these tumors were exceedingly rare [7]. Later reports, from Japan and Spain, each described single cases of presacral fibrosarcomas in adult patients [8,9]. The patient, described by Isobe et al. from Japan, was a 34-year-old woman with a retroperitoneal fibrosarcoma that had metastasized to the liver [8]. The clinical presentation in the latter report was similar to that seen in our patient. A solitary presacral fibro sarcoma has also been described in a child from Thailand [10]. In this pediatric patient, the tumor was aggressive and invaded the spinal canal, mimicking a tumor of neurogenic origin [10].

Our patient showed a solid presacral mass without any cystic component. Therefore, epidermoid and tail gut cysts as well as meningocele were excluded. There was no rectal abnormality, significant enhancement, neural foramina or bone involvement. Therefore, we excluded a retroperitoneal GIST, neural tumors and primary bone tumors in the

presacral region. The absence of serpiginous enhancement and of phleboliths excluded a vascular malformation in our patient. The lack of adipose elements excluded a liposarcoma. The presence of focal nodular calcification in the tumor, along with early metastases in the liver and lymph nodes, all led to the diagnosis of a sarcoma consisting most likely of fibrous elements. This was confirmed by a CT-guided biopsy. Pre operative biopsy is however contraindicated when a sacral meningocele or vascular malformations are the suspected aetiologies in the pre sacral compartment.

The recommended treatment of presacral tumors is extensive surgical resection and adjuvant chemotherapy [3,6,11]. Recently, the role of hyperthermic intraperitoneal chemotherapy (HIPEC) has been described for the treatment of recurrent retroperitoneal sarcomas [11]. There have been specific chemotherapy regimens described for patients with hepatic metastases at initial presentation [8]. Radiotherapy has a limited role in the majority of presacral masses, except for sarcomas where it is used as an adjuvant treatment modality [11]. Unfortunately, a high rate of recurrence is known in retroperitoneal sarcomas in spite of aggressive therapy [9].

References:

1. Shanbhogue AK, Fasih N, Macdonald DB et al: Uncommon primary pelvic retroperitoneal masses in adults: A pattern-based imaging approach. *Radiographics*, 2012; 32: 795-817
2. Yang BL, Gu YF, Shao WJ et al: Retrorectal tumors in adults: Magnetic Resonance Imaging findings. *World J Gastroenterol*, 2010; 16(46): 5822-29
3. Dunn KB: Retrorectal tumors. *Surg Clin N Am*, 2010; 90(1): 163-71
4. Wetzel LH, Levine E: Pictorial essay. MR Imaging of sacral and presacral lesions. *Am J Roentgenol*, 1990; 154(4): 771-75
5. Brennan C, Kajal D, Khalili K, Ghai S: Solid malignant retroperitoneal masses – a pictorial review. *Insights Imaging*, 2014; 5: 53-65
6. Hassan I, Wietfeldt ED: Presacral tumors: Diagnosis and management. *Clin Colon Rectal Surg*, 2009; 22(2): 84-93
7. Mcnamara WL, Smith HD, Boswell CS: Retroperitoneal fibrosarcoma – report of 8 cases *Am J Cancer*, 1940; 38: 63
8. Isobe H, Wada Y, Ryo J et al: An effective chemotherapy regimen for liver metastasis from retroperitoneal fibrosarcoma – report of a case. *Surg Today*, 1997; 27(5): 463-65
9. Sotolongo Vergo I, Suarez Cabrera RE, Arencibia Garcia J: [Retroperitoneal fibrosarcoma – Apropos of a case.] *Arch Esp Urol*, 2003; 56(4): 421-24 [in Spanish]
10. Virayavanich W, Sirikulchayanonta V, Jaovisidha S et al: Pre sacral fibro sarcoma in childhood: A case report. *J Med Assoc Thai*, 2010; 93(2): 252-56
11. Mullinax JE, Zager ZS, Gonzalez RJ: Current diagnosis and management of retroperitoneal sarcoma. *Cancer Control*, 2011; 18(3): 177-87

Conclusions

Primary retroperitoneal tumors in the presacral/retrorectal compartment are rare, and primary sarcomas in this location are found to be even rarer. The most common sarcomas in the presacral region are liposarcomas, whereas fibrosarcomas have been described in only a few reports. We are reporting a new case of a very rare entity, a presacral fibrosarcoma. Imaging techniques are vital for making the diagnosis. Not only do they confirm the location of the disease, but also further characterize it and document the invasion of the surrounding structures and an extension beyond the pelvic cavity. The treatment plan, including surgery, is therefore based on the imaging results [2]. The imaging features that help in the differential diagnosis of presacral tumors are cystic versus solid masses, nature of cysts, presence/absence of fat, bone and neural foramina erosion or destruction, tumor enhancement and its extent and invasion of the contiguous structures. We have highlighted the imaging features and analytical imaging approach, which had led us to the accurate diagnosis. The clinical presentation of our patient is informative for radiologists who may encounter similar patients with a disease/mass in the presacral region.