



Received: 2016.03.12
Accepted: 2016.03.30
Published: 2016.10.22

Authors' Contribution:

- A** Study Design
- B** Data Collection
- C** Statistical Analysis
- D** Data Interpretation
- E** Manuscript Preparation
- F** Literature Search
- G** Funds Collection

Spontaneous Cholecysto-Cutaneous Fistula Draining Through an Old Abdominal Surgical Scar

Mukesh Surya^{ABEF}, Pawan Soni^{ABF}, Kshama Nimkar^{AEF}

Department of Radiodiagnosis, Dr. Rajendra Prasad Government Medical College, Kangra at Tanda, Himachal Pradesh, Kangra, India

Author's address: Mukesh Surya, Department of Radiodiagnosis, Dr. Rajendra Prasad Government Medical College, Kangra at Tanda, Himachal Pradesh, Kangra, India, 176001, e-mail: mukeshsurya27@yahoo.com

Background:	Though cholelithiasis and cholecystitis are common clinical problems, spontaneous cholecysto-cutaneous fistula is a rare complication of cholelithiasis in present-day practice. Very few cases have been reported in literature after 1950s.
Case Report:	A 60-year-old male presented with pain and discharging sinus in the upper abdomen. Ultrasonography and computed tomography confirmed the presence of perforation of the gall bladder and cholecysto-cutaneous fistula. External opening of the fistula was overlying an old surgical scar. Less than five cases of spontaneous cholecysto-cutaneous fistula draining through an old surgical scar have been reported in literature. Initially, the patient was managed conservatively, followed by elective open cholecystectomy and excision of the fistula tract.
Conclusions:	Though very rare in the present era of advanced medical care, cholecysto-cutaneous fistula as a potential diagnosis should be kept in mind in patients presenting with acute upper abdomen pain and discharging sinus. High degree of suspicion is required for early diagnosis and treatment of this condition.
MeSH Keywords:	Biliary Fistula • Cholecystitis • Cholelithiasis • Multidetector Computed Tomography
PDF file:	http://www.polradiol.com/abstract/index/idArt/898464

Background

Cholecystitis, biliary pancreatitis, choledocolithiasis, biliary colic, pancreatitis are common complications of cholelithiasis. Rarely there can be free or localized perforation of the gall bladder wall leading to peritonitis and peri-cholelithiasis. However, spontaneous perforation of the gall bladder into skin leading to a cholecysto-cutaneous fistula is exceedingly rare. Very few cases have been reported in literature in the last 60 years. We present a rare case of spontaneous cholecysto-cutaneous fistula draining through an old healed laparotomy scar.

Case Report

A sixty-year-old male presented to the general surgery department with complaints of pain in the right upper abdomen for the last 20 days and discharging sinus in the upper abdomen for one day. The pain was dull in nature. He was operated on for liver abscess four years back. On

examination, patient was conscious, cooperative and well oriented. His pulse, body temperature and blood pressure were normal. On local examination, a discharging sinus was seen in the epigastrium near the midline, overlying an old laparotomy scar (Figure 1). Fluid was mucoid in nature. Erythema was seen in the surrounding skin (Figure 1). Tenderness was noticed in the right hypochondrium and epigastrium on palpation. His Hb, TLC, DLC, ESR, and liver function tests were within normal limits.

The patient was referred to the Radiology Department for emergency ultrasonography (USG) of the abdomen. USG was carried out on a GE Logiq P5 machine, and revealed concentric thickening of the wall of the gall bladder with multiple calculi in its lumen. There was suspicious discontinuity of the outline of the wall in the fundic region of the gall bladder, and small peri-cholelithiasis fluid collection, raising suspicion of perforation. Contrast-enhanced computed tomography (CT) was planned for confirmation of USG findings. CT was conducted on a Philips Brilliance 16

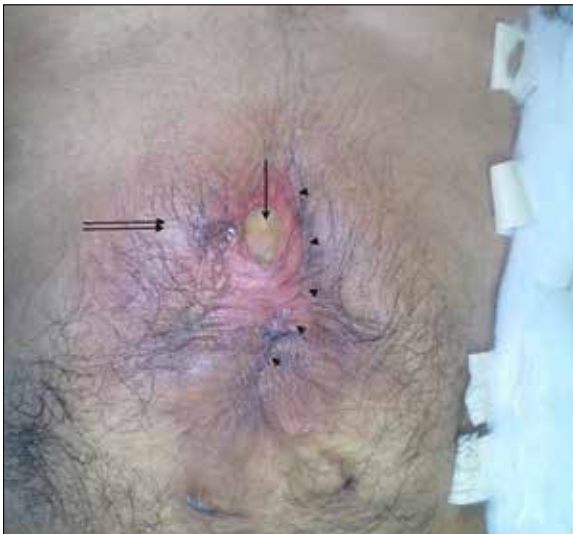

Figure 1. Photograph of the abdomen of the patient, showing external opening of the fistula (arrow) overlying an old laparotomy scar (arrow heads) and erythema of the surrounding skin (double arrow).

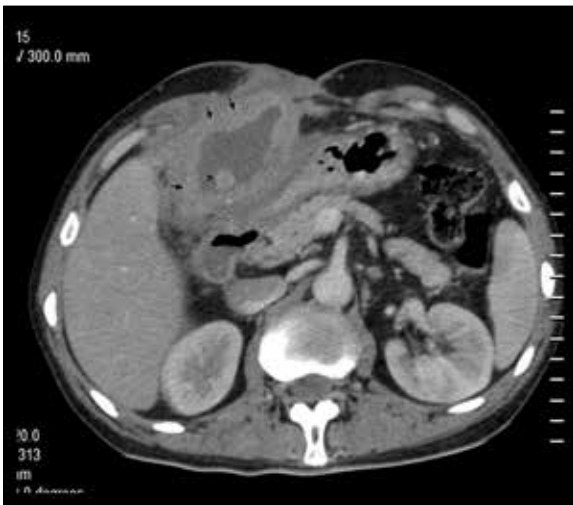

Figure 2. Contrast-enhanced axial CT showing the fundus of GB reaching up to the anterior abdominal wall. There is marked thickening of the GB wall (arrows). A calculus is also seen in the lumen of GB (arrow head).

machine. Oral as well as intravenous non-ionic low-osmolar iodinated contrast medium was given via the antecubital vein. Non-contrast followed by contrast-enhanced scans were acquired in the portal phase. On CT, the gall bladder (GB) was found to be well distended and the fundus of GB was reaching up to the anterior abdominal wall in the midline (Figure 2). The fundus of GB seemed to be adherent to the anterior abdominal wall and there was stranding in the subcutaneous and peri-cholecystic fat suggestive of inflammatory changes. There was concentric thickening of the wall of GB measuring up to 13 mm, showing heterogeneous enhancement (Figures 2–4). Multiple rounded hyperdense calculi were seen in the lumen of GB (Figures 2, 5). A defect of approximately 9 mm in size was seen in the wall of GB (Figures 3, 5) and a small fluid collection was observed in the peri-cholecystic area near the defect,

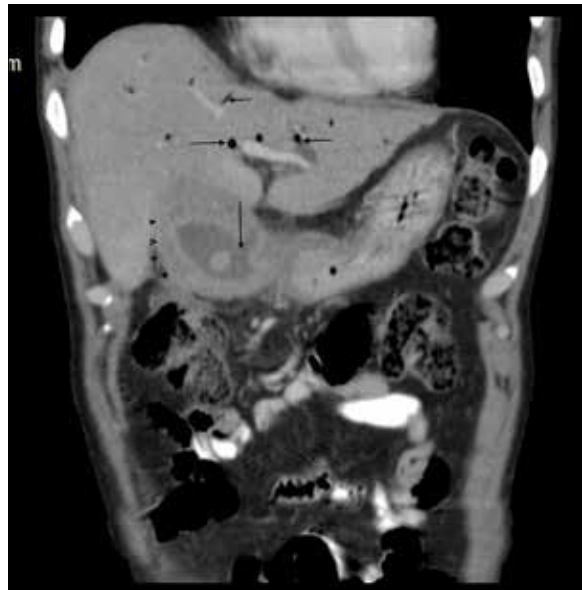


Figure 3. Coronal reformatted contrast-enhanced CT showing multiple air-density foci in IHBRS (horizontal arrows) suggestive of pneumobilia. Breach in the mucosal lining of GB is also seen (vertical arrow). There is concentric thickening of the GB wall showing inhomogeneous enhancement (arrow heads).

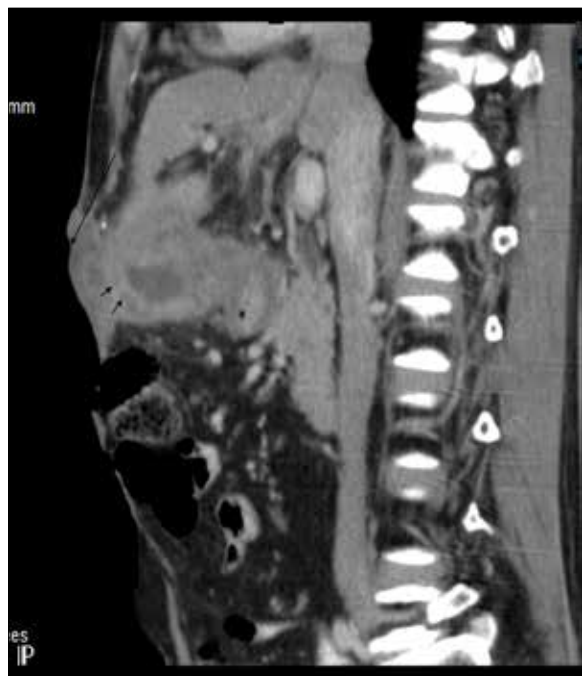

Figure 4. Sagittal reformatted contrast-enhanced CT showing GB fundus adherent to the anterior abdominal wall with ulceration of the overlying skin (long arrow). There is concentric thickening of the GB wall showing inhomogeneous enhancement (small arrows).

measuring approximately 36×25 mm (Figure 5). A fistulous tract was seen as a fluid-density streak extending from the peri-cholecystic area to the anterior abdominal wall and skin (Figure 5). The common bile duct (CBD) measured 7 mm in diameter. The intra-hepatic biliary radicles (IHBRS)

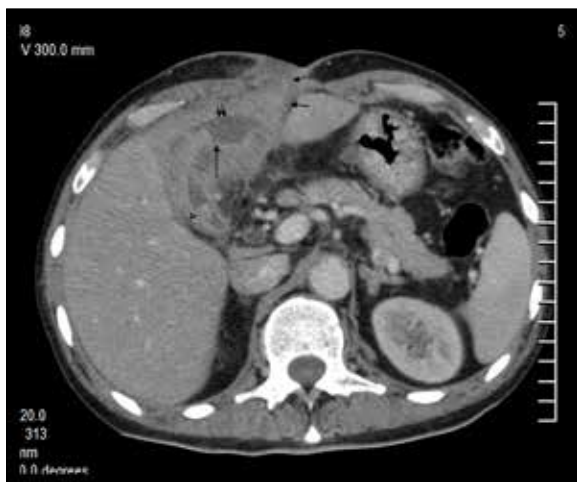

Figure 5. Contrast-enhanced axial CT showing a heterogeneously-enhancing thickened GB wall with small peri-cholecystic fluid collection (double arrow) adjacent to a small defect in the GB wall (long vertical arrow). Linear fistula tract is seen extending from the GB fossa to skin (small arrows). Hyperdense calculus is also noted in the lumen of GB (arrow head).

were not dilated. However, air-density foci were seen in IHBR, suggestive of pneumobilia (Figure 3).

Based on clinical and radiological findings, diagnosis of cholelithiasis with cholecystitis with perforation of the gall bladder with cholecysto-cutaneous fistula with pneumobilia was made.

The patient was managed conservatively with intra-venous antibiotics (ceftriaxone and gentamycin) and a supportive therapy. The wound showed signs of healing and cessation of active discharge during patient's stay in hospital. The patient was discharged on the 10th post-admission day and was advised to report back for surgery. Open cholecystectomy with excision of the cholecysto-cutaneous fistula was done under general anesthesia a few months later. A markedly inflamed gall bladder adherent to the adjacent liver and greater omentum was removed and sent for histopathological examination which revealed features suggested acute and chronic inflammatory changes. The patient was asymptomatic and healthy on a one-year follow-up.

Discussion

Cholelithiasis is a common clinical problem in today's practice. Various complications of cholelithiasis include acute/chronic cholecystitis, empyema of GB, localized or free perforation of GB, CBD stones leading to biliary colic, acute biliary pancreatitis and obstructive jaundice. Rarely, a large gall stone may perforate into GIT leading to gall stone ileus [1]. Spontaneous rupture of the gall bladder into the skin is an extremely rare complication of cholelithiasis in the present era. Very few cases have been reported in literature during the last few decades. Thelassus in the year 1670 was first to report a case of spontaneous cholecysto-cutaneous fistula [2]. Courvoisier reported 169 cases of spontaneous cholecysto-cutaneous fistula in the year

1890 [2]. One hundred and eighty-four cases of cholecysto-cutaneous fistula were reported by Naunyn [3] in 1892. Incidence of spontaneous cholecysto-cutaneous fistula has significantly gone down in the last century with the availability of better antibiotics and improved surgical management of gall stones and their complications. Henry and Orr encountered only 36 cases of external biliary fistula between 1890 and 1949 [4]. Very few cases of spontaneous cholecysto-cutaneous fistula have been published in literature in the last half-century, including individual case reports only.

Obstructing gall stone or malignancy are the most common causative factors for development of cholecysto-cutaneous fistula. Chronic obstruction due to calculus or mass leads to increased intra-luminal pressure causing decreased perfusion, necrosis and perforation of the GB wall. Perforated GB may lead to generalized peritonitis or localized abscess formation. An abscess may penetrate the anterior abdominal wall and may expel the contents exteriorly. In our case, the anterior abdominal wall was already weakened by the previous laprotomy scar, forming the path with least resistance. Only a handful of such cases have been reported to the best of our knowledge. Orestis Ionaditis et al. (2012) reported a case of spontaneous cholecysto-cutaneous fistula draining via an old surgical drain site scar [5]. Another such case was reported by Yamini Kapoor et al. [6] in one of the two cases in 2013.

Patients usually present with pain and discharging sinus. Right hypochondrium is the most common site of external opening; however, fistula opening may be seen in the left hypochondrium, umbilical region, right lumbar region, right iliac fossa and rarely in the gluteal region. Elderly women are most commonly affected. Ultrasonography is the initial radiological investigation. Gall stones, signs of acute cholecystitis, peri-cholecystic abscess/fluid collection may be found on USG. CT is the radiological investigation of choice, which can depict thickening of the GB wall, defect in the mucosa of GB, peri-cholecystic abscess and fistula tract. Few authors have reported the use of fistulography for delineation of the fistula tract [7].

Cholecysto-cutaneous fistulas are managed conservatively, initially with antibiotics and supportive therapy. Elective cholecystectomy with excision of the fistula tract is carried out later on.

Conclusions

Spontaneous cholecysto-cutaneous fistula is a rare complication of cholelithiasis in the present era of advanced medical care; and fistula draining through an old surgical abdominal scar is even rarer. Only a handful of such cases have been reported in literature so far. A high degree of suspicion is required by the clinicians and radiologists for early detection and management of this condition. Computed Tomography (CT) is the radiological investigation of choice for detailed evaluation of the fistulous tract and associated complications. Cholecysto-cutaneous fistula is managed conservatively initially, followed by elective cholecystectomy and excision of the fistula tract.

References:

1. Scheurer U: Clinical manifestations of cholelithiasis and its complications. *Praxis (Bern 1994)*, 1995; 84(20): 590-95
2. Courvoisier L: *Pathologie and Chirurgie der Gallenwege*. FCW Vogel, Leipzig, 1890
3. Naunyn B: Ulcerative affections of the biliary passage and fistula formation. *A Treatise on Cholei* Sydenham Society. New Sydenham Society, 1892; 138-51
4. Henry CL, Orr TG Jr.: Spontaneous external biliary fistulas. *Surgery*, 1949; 26: 641-46
5. Ioannidis O, Paraskevas G, Kotronis A et al: Spontaneous cholecystocutaneous fistula draining from an abdominal scar from previous surgical drainage. *Ann Ital Chir*, 2012; 83(1): 67-69
6. Kapoor Y, Singh G, Khokhar M: spontaneous cholecystocutaneous fistula – not an old time story. *Indian J Surg*, 2013; 75(Suppl. 1): S188-91
7. Flora HS, Bhattacharya S. Spontaneous cholecystocutaneous fistula. *HPB (Oxford)*, 2001; 3(4): 279-80