



Received: 2015.11.23
Accepted: 2016.01.07
Published: 2016.08.09

Authors' Contribution:

- A** Study Design
- B** Data Collection
- C** Statistical Analysis
- D** Data Interpretation
- E** Manuscript Preparation
- F** Literature Search
- G** Funds Collection

Stent-Assisted Endovascular Treatment of Anterior Communicating Artery Aneurysms – Literature Review

Damian Kocur¹**A****E****F**, Wojciech Ślusarczyk^{1,2}**A****E****F**, Nikodem Przybytko¹**A****E****F**,
Piotr Bażowski¹**A****E**, Adam Właszczuk²**E**, Stanisław Kwiek¹**A****E****F**

¹ Department of Neurosurgery, Medical University of Silesia, School of Medicine in Katowice, Katowice, Poland

² Department of Physiology, Medical University of Silesia, School of Medicine in Katowice, Katowice, Poland

Author's address: Damian Kocur, Department of Neurosurgery, Medical University of Silesia, School of Medicine in Katowice, Medyków 14 Str., 40-752 Katowice, Poland, e-mail: damkocur@gmail.com

MeSH Keywords:

Embolization, Therapeutic • Endovascular Procedures • Intracranial Aneurysm

PDF file:

<http://www.polradiol.com/abstract/index/idArt/896818>

Summary

The anterior cerebral artery is a common location of intracranial aneurysms. The standard coil embolization technique is limited by its inability to occlude wide-neck aneurysms. Stent deployment across the aneurysm neck supports the coil mass inside the aneurysmal sac, and furthermore, has an effect on local hemodynamic and biologic changes. In this article, various management strategies and techniques as well as angiographic outcomes and complications related to stent-assisted endovascular treatment of anterior communicating artery aneurysms are presented. This treatment method is safe and associated with low morbidity and mortality rates.

Background

Intracranial aneurysms are found in approximately 2% of adults [1]. Most of the unruptured aneurysms are asymptomatic and discovered incidentally but rupture of aneurysm results in a potentially life-threatening subarachnoid hemorrhage (SAH). In most series the anterior communicating artery (AcomA) is the most common location for intracranial aneurysms and ruptured aneurysms of this artery are the cause of 40% of aneurysmal subarachnoid hemorrhages in adults [2]. Either unruptured or ruptured brain aneurysms may be treated surgically or via endovascular approach. The main treatment goal of both methods is to exclude the aneurysm from circulation in order to prevent hemorrhage or rehemorrhage. Although surgical clipping of AcomA aneurysms is acknowledged to be a safe and effective procedure, it may be technically challenging because of deep midline aneurysm location, presence of small vessels and perforators, unfavourable fundus projection, frequent anatomy variations and the higher risk of postoperative cognitive impairment [2–6]. It is reported that AcomA aneurysms demonstrate the highest incidence of postoperative morbidity among all anterior circulation aneurysms [7].

Endovascular Techniques in Treatment of Acoma Aneurysms

Endovascular embolization is a less traumatic treatment option of brain aneurysms and with its high feasibility and effectiveness in AcomA aneurysms it is becoming the leading method [2,4,8]. In comparison with the other intracranial aneurysms embolization of AcomA aneurysms may be difficult due to the high frequency of small or complex aneurysms and common vascular variants in this location [5]. However, endovascular approach remains the first choice technique in cerebral aneurysms treatment in many neurosurgical centres. The primary technique of endovascular treatment of the cerebral aneurysms is coil embolization (coiling). In this method detachable coils are deployed within the aneurysm lumen. Unfortunately, the application of coiling is limited in case of aneurysms with unfavourable anatomy. Aneurysms with a “wide neck” are difficult to treat because of the risk of coil protrusion into the parent vessel or the high probability of incomplete occlusion [9,10]. Wide-necked aneurysms are defined as those with maximum neck width of 4.0 mm or those with aneurysm dome-to-neck ratio (maximum dome width/maximum neck width) of <2.0 or <1.5 [10–14]. Endovascular treatment of wide-necked AcomA aneurysms requires application of

adjuvant techniques of which the two most widespread are balloon remodelling technique (BRT) and stent-assisted coiling technique (SACT), methods primarily applied for endovascular treatment of sidewall aneurysms. In BRT a balloon is temporarily deployed and inflated across the aneurysm neck. Then coils are placed into the aneurysm sac and the balloon is removed [9]. Compared with SACT the balloon remodelling technique is associated with lower rate of aneurysm obliteration, lower rate of progression of occlusion at follow-up, higher rate of retreatment and similar procedural complication rate [15]. Moreover, in case of extremely wide-necked aneurysms BRT is inadequate [5].

First described by Higashida in 1997 SACT has widened the range of options for the treatment of wide-necked aneurysms, including AcomA aneurysms [5,6,16–19]. Because of a small length of the AcomA and acute angles of adjacent vessels, application of adjuvant techniques in endovascular treatment of AcomA aneurysms in relation to the other cerebral aneurysms is technically challenging [5,20]. A self-expandable stent serves as a scaffold which prevents the coil protrusion into the parent artery and results in denser coil packing [21]. Moreover, a stent may be deployed in case of earlier coil protrusion into the parent vessel as a prevention of a thromboembolic event [5,17,18,22]. In addition to their mechanical function, stents are reported to have hemodynamic effects as they redirect blood flow from the sac of the aneurysm toward the distal parent artery. That contributes to thrombosis of the aneurysmal sac and decreases the likelihood of recanalization [7,23]. Biological effects of intracranial stents are associated with stent-induced neointimal overgrowth [24].

There are various intervention techniques depending on the time of stent deployment in relation to coiling (Figure 1) [5,6,18,25]. In case of the treatment of wide-necked AcomA aneurysms, stents are commonly placed prior to coiling [5,6,18]. In the “jailing” technique the embolization microcatheter is navigated into the aneurysm before deployment of the stent [6,26]. The microcatheter placed between the vessel wall and the stent is stabilized during coiling. Another option is to place the microcatheter into the aneurysm lumen through the stent struts after deploying of the stent (trans-cell technique) [9]. However, crossing a deployed stent with a microcatheter may be technically challenging [26]. Raslan et al. reported this method as difficult and used the “jailing” technique as the first-choice method in the treatment of AcomA aneurysms, while Huang et al. deployed stents first [5,6]. According to this author the application of the “jailing” technique in endovascular embolization of AcomA aneurysms is limited due to the small diameter of ACA and vasospasm resulting from SAH [5]. Raslan et al. presented three possible stent placement configurations across the AcomA aneurysms (Figure 2). Stent may be deployed from ipsilateral A1 to contralateral A2 (most commonly), from ipsilateral A1 to ipsilateral A2 (less commonly) and from ipsilateral A1 to contralateral A1 segment (least common configuration) [6]. Huang in his study deployed stents in the ipsilateral A2 segments more commonly than in the contralateral A2 segments [5]. The strategy of stent placement depends on aneurysm neck location and symmetry of the anterior cerebral arteries [5]. Stent-assisted coiling of wide-necked

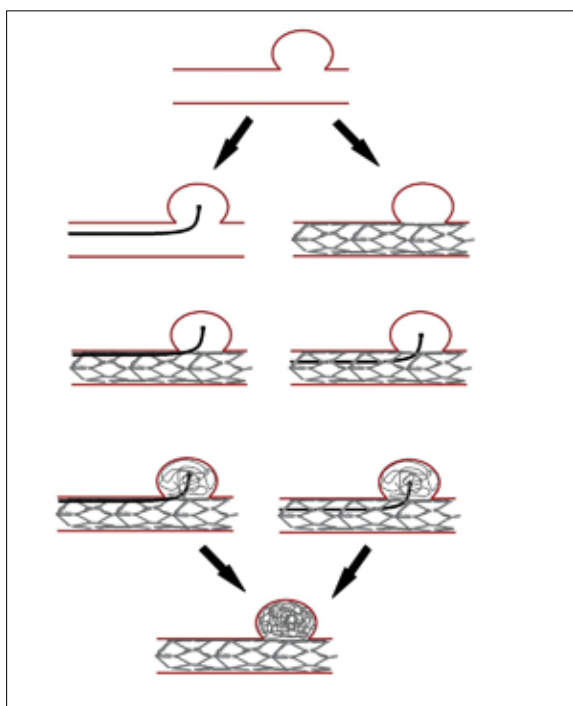


Figure 1. The illustration presents two different stent deployment techniques with respect to microcatheter insertion. The “jailing” technique depicted on the left side and the trans-cell technique on the right side. The final effect is the same.

and complex AcomA aneurysms may be challenging due to their anatomic and geometric features [20,27,28]. In such cases implantation of 2 stents (i.e. dual stent placement) in X- or Y-configuration or the “waffle cone” technique may be used (Figure 3) [20,27,28]. The X-configured dual stent placement is a feasible method for the treatment of wide-necked AcomA aneurysms involving both A1-A2 junctions where the AcomA is partly incorporated within the sac and both A2s protrude from the aneurysm [7]. In such technically challenging aneurysms (also from the surgical point of view) the first stent is deployed from the contralateral A2 to the ipsilateral A1 segment, crossing through the AcomA and the second stent is crossed from the other side [7,9]. The side with the smaller angle between the A1 – AcomA complex and the contralateral A2 segment is stented first [9]. The stents may be placed using two different methods. In the kissing technique stents are deployed in a parallel fashion while in the crossing technique a second stent is advanced through the first stent interstices [9]. In comparison to ipsilateral placement of stents with an “opposite L” configuration (i.e. deploying stents from the ipsilateral A2 to the A1 segment) the X-stent technique may be used in case of small angles between the A1-A2 segments [7]. Moreover, the latter technique preserves the patency of AcomA and alters flow direction at the neck of the aneurysm which may have an impact on long-term durability [7]. However, this technique is to be reserved for patients having good-sized A1s, bilaterally [7]. On the other hand, Y-configured dual stent placement is an option for patients with hypoplasia/aplasia of A1 on one side and complex AcomA aneurysms when the aneurysm neck involves the ipsilateral A2 and AcomA [7,20]. In this method stents are deployed through the large-sized A1 in the

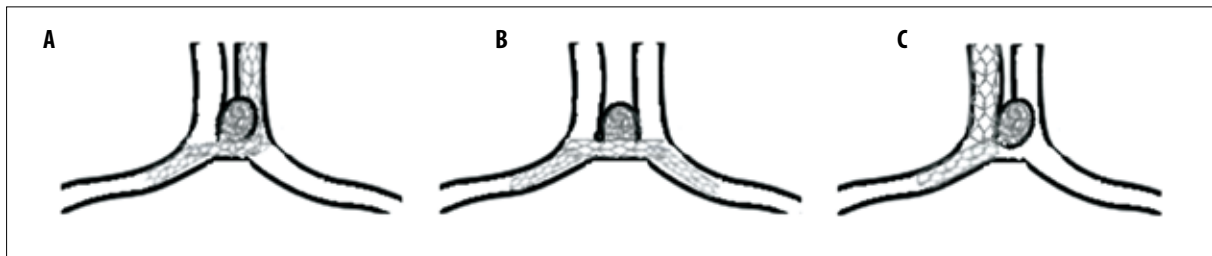


Figure 2. The schematic drawing presents three possible stent configurations according to Raslan et al. (A) Ipsilateral A1 to contralateral A2; (B) ipsilateral A1 to contralateral A1; (C) ipsilateral A1 to contralateral A1.

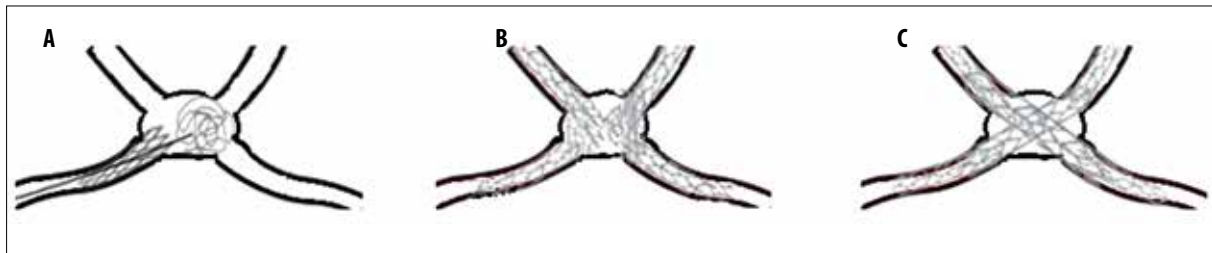


Figure 3. The schematic drawing presents three methods applied to wide-neck complex anterior communicating aneurysms. (A) “Waffle-cone” technique; (B) X-configured dual stent placement in the kissing technique; (C) X-configured dual stent placement in the crossing technique.

bilateral A2 segments [7,20]. In the “waffle cone” technique the distal end of a stent is placed into the aneurysm lumen and the proximal end of a stent is left in the afferent vessel (intra/extra-aneurysmal placement) [27,28]. This method allows for preservation of the parent artery patency. Coiling is done through the cone-shaped distal end of the stent [27]. The waffle cone technique may be a good alternative to dual stent placement in case of aneurysms incorporating bilateral A2 segments or involving the AcomA or if there is a difficulty in selecting a distal major vessel due to acute angles between the parent and distal arteries [5,27]. However, this technique carries a potential risk of aneurysm perforation, especially in freshly ruptured or smaller (<4 mm) aneurysms and the rate of recanalization due to flow direction in the aneurysm may be higher [5,27].

There are two types of stent designs depending on the size of cell areas and the type of connections between stent struts: open-cell design (Neuroform stents) and closed-stent design (Enterprise, LEO and Solitaire stents). All the aforementioned devices are self-expandable and made of nitinol (nickel titanium) [26]. The first stent assisting the treatment of a brain aneurysm with coils was the Neuroform stent, approved in 2002 [26]. The Neuroform stent has a longer record of use and is more established in the treatment of AcomA aneurysms than the Enterprise stent, its principal alternative. The latter is more flexible, easier to deploy and navigate. Furthermore, the advantage of the closed-stent design is higher effectiveness in keeping coils within an aneurysm [29,30]. In comparative analyses both Neuroform and Enterprise stents were reported to be safe and effective with comparable morbidity rates [31].

Angiographic Outcome and Recanalization

A meta-analysis conducted in 2013 concerning outcomes of embolization of AcomA aneurysms showed that non-stent and stent-assisted coiling of AcomA aneurysms is

associated with a high rate of complete angiographic occlusion [2]. In this study the rate of immediate and long-term complete and near-complete angiographic occlusion was 88% and 85%, respectively [2]. In case of complete occlusion there is absence of contrast medium filling within the coil mass. Near-complete occlusion is defined as small residual neck filling without any filling of the sac and in contrast to the residual aneurysm it requires no retreatment [2,6]. Angiographic results of three stent-assisted AcomA aneurysm embolization series showed that the complete and near-complete occlusion rate was 66–95% initially and 88–95% at follow-up [5,6,18]. Detailed data are presented in Table 1. Stent-assisted coil embolization of intracranial aneurysms is associated with a lower rate of immediate complete aneurysm occlusion compared with non-stent procedures [32]. One of the reasons is that coiling after stent deployment may be technically more difficult due to the limited manoeuvrability of the coiling microcatheter resulting in looser aneurysm packing [32]. On the other hand, stented aneurysms demonstrate a higher rate of delayed sac thrombosis at follow-up than non-stented ones [32]. Johnson et al. observed angiographic improvement (i.e. delayed aneurysm occlusion) at 6-month follow-up in 17 (63%) of 27 patients with initially incomplete occlusion after stent-assisted AcomA aneurysm coiling [18]. The reduction of aneurysm sac opacification is likely to result from delayed intra-aneurysmal thrombosis [20]. There are case reports demonstrating delayed aneurysm sac thrombosis when stent is placed across the aneurysm neck without coiling but these reports do not include AcomA aneurysms [33–36]. It is suggested that expected delayed intra-aneurysmal thrombosis should be taken into consideration in case of incomplete immediate stent-assisted embolization and insertion of additional coils is considered risky [6]. Moreover, stent deployment during intracranial aneurysm coiling is reported to improve the durability of aneurysm embolization probably because of arterial wall reconstruction at the level of the neck,

Table 1. Studies on stent-assisted coil embolization of AcomA aneurysms.

Study	No. of treated patients	No. of patients with complete and near-complete occlusion	No. of patients with angiographic follow-up	No. of patients with complete occlusion in last angiographic follow-up	Time of angiographic follow-up	No of patients with recanalization requiring retreatment
Huang et al. 2009 [5]	21	20 (95%)	12	11 (92%)	5.6 months (range, 1–12 months)	1 (8.3%)
Raslan et al. 2011 [6]	44	29 (66%)	33	24 (73%)	At least 3 months, mean 65 weeks (median, 52 weeks)	4 (12.1%)
Johnson et al. 2012 [18]	64	47 (73%)	55	39 (71%)	6 months	3 (5.5%)

stent endothelialization and change of the hemodynamics [17,20,22,32]. Nevertheless, as recurrences may still happen, radiographic follow-up is mandatory. Although digital subtraction angiography (DSA) is a standard follow-up imaging study, non-invasive and non-irradiating in nature, MR angiography (MRA) is an option [37]. It is reported that time of flight (TOF) MRA is sufficient and effective to assess re-opening of the coiled aneurysms treated using Enterprise stents, which produce more signal loss than Neuroform stents [37]. However, in patients with intracranial stents MRA cannot exactly reflect in-stent stenosis of the stented parent artery and it is suggested that DSA should be performed at least once during the follow-up period [37]. The reasons of recurrence are coil compaction or regrowth of the aneurysm [38]. The rate of recanalization after stent-assisted AcomA aneurysm embolization is 8–12% [5,6,18]. In a general population of all brain aneurysms treated with stent-assisted coiling the rate is 13–23% [13]. Recurrences are observed mainly within 6 months after treatment [17]. Risk factors for cerebral aneurysm recanalization after stented coiling are wide-necked aneurysms, partial occluded aneurysms and large or giant aneurysms [17]. Treatment options for residual or recurrent aneurysms after coil embolization include surgical clipping, re-coiling or observation [38]. There is no preferred method in this situation [38]. As the decision about retreatment is challenging, there are more or less conservative approaches among centres [6,18].

Complications

Stent-assisted coil embolization of intracranial aneurysms including AcomA aneurysms is reported to be a safe technique with low morbidity and mortality rates [5,17]. In this group the overall procedure-related complication, morbidity and mortality were 14.2%, 4.2% and 1.3%, respectively [17]. Morbidity and death rate in case of stent-assisted coiling of AcomA aneurysms is 0–5% [5,6,18].

The most frequent cause of morbidity and mortality accompanying stent-assisted coiling is thromboembolism. [17,29] According to literature, incidence of thromboembolic event in case of stent-assisted coiling ranges from 4.2 to 17.1% [17]. This complication is often clinically silent and then may be detected on a diffusion-weighted image (DWI) as a high-signal-intensity lesion (diffusion-positive lesions,

i.e. DPLs) or it produces transient neurologic symptoms [17,29,39]. It is acknowledged that deploying a stent during endovascular treatment induces local thrombogenicity, especially in the acute phase of treatment before endothelialization occurs [35]. However, it is reported that adjunctive devices such as stents did not increase the thromboembolic event rate if the dual antiplatelet regimen (acetylsalicylic acid and clopidogrel) was used and the thrombocyte aggregation level was evaluated rigorously [22,40]. In three studies on stent-assisted coiling of AcomA aneurysms no symptomatic periprocedural thromboembolic events were reported, although antiplatelet strategies varied [5,6,18]. It is worth mentioning that there was one case of disabling ACA territory infarct during orthopaedic surgery, 11 months after stent-assisted embolization, in a patient who no longer took antiplatelet drugs [18]. The dual antiplatelet therapy in patients with subarachnoid hemorrhage and unprotected ruptured aneurysm is controversial. It is reported that the application of this therapy in patients who suffered from SAH worsens the prognosis if intraprocedural rupture occurs during stent embolization [35].

Delayed intra-stent (in-stent) stenosis is a rare but important complication that may be clinically significant and potentially requires additional treatment [41]. It is hypothesized that vascular remodelling (neointimal hyperplasia) as well as formation of intra-stent thrombus may be responsible for the delayed narrowing of the stented segment of the parent artery. The flexibility and radial force of the used stent also matters [17,35,41]. In three studies on stent-assisted AcomA aneurysm coiling there is only one case of in-stent stenosis [5,6,18]. The narrowing was 45% and asymptomatic. In that case the Neuroform stent was used [6]. Despite the smaller parent vessels associated with the anterior communicating complex this complication in this cohort of aneurysms was similar to previously published rates of in-stent stenosis [6].

The difference in the diameters of A1 and A2, structural characteristics of the stent (open-cell vs. closed-cell design) and angular expansion of the stented vessels (the stented A2 segment is closer to a straight line with the ipsilateral A1) may have the influence on the risk of stent migration [20].

Small AcomA or basilar apex aneurysms associated with SAH carry the highest risk of intraprocedural rupture

during coiling [42]. Perforation may occur when a coil, a microcatheter, a microguidewire or a stent is deployed [5,6,18,42]. In case of an incomplete occlusion of a perforated aneurysm, packing of additional coils is attempted to control hemorrhage [5,6,42]. Disastrous clinical outcomes occur infrequently [5,6,18,42].

Other nonspecific complications include artery dissection, groin complications, hemorrhagic incident related to anti-coagulation and SAH-related complications (vasospasm and hydrocephalus) [22].

References:

- Rinkel GJ, Djibuti M, Algra A, van Gijn J: Prevalence and risk of rupture of intracranial aneurysms: A systematic review. *Stroke J Cereb Circ*, 1998; 29: 251-56
- Fang S, Brinjikji W, Murad MH et al: Endovascular treatment of anterior communicating artery aneurysms: A systematic review and meta-analysis. *Am J Neuroradiol*, 2014; 35: 943-47
- Finitis S, Anxionnat R, Lebedinsky A et al: Endovascular treatment of ACom intracranial aneurysms. Report on series of 280 patients. *Interv Neuroradiol J Peritherapeutic Neuroradiol Surg Proced Relat Neurosci*, 2010; 16: 7-16
- Guglielmi G, Viñuela F, Duckwiler G et al: Endovascular treatment of 306 anterior communicating artery aneurysms: overall, perioperative results: Clinical article. *J Neurosurg*, 2009; 110: 874-79
- Huang Q, Xu Y, Hong B et al: Stent-assisted embolization of wide-neck anterior communicating artery aneurysms: Review of 21 consecutive cases. *Am J Neuroradiol*, 2009; 30: 1502-6
- Raslan AM, Oztaskin M, Thompson EM et al: Neuroform stent-assisted embolization of incidental anterior communicating artery aneurysms: long-term clinical and angiographic follow-up. *Neurosurgery*, 2011; 69: 27-37
- Saatci I, Geyik S, Yavuz K, Cekirge S: X-configured stent-assisted coiling in the endovascular treatment of complex anterior communicating artery aneurysms: A novel reconstructive technique. *Am J Neuroradiol*, 2011; 32: E113-17
- Koebbe CJ, Veznedaroglu E, Jabbour P, Rosenwasser RH: Endovascular management of intracranial aneurysms: current experience and future advances. *Neurosurgery*, 2006; 59: S93-102; discussion S103-13
- Piotin M, Blanc R: Balloons and stents in the endovascular treatment of cerebral aneurysms: Vascular anatomy remodeled. *Front Neurol* 2014; 5: 41
- Brinjikji W, Cloft H, Kallmes DF: Difficult aneurysms for endovascular treatment: Overwide or undertall? *Am J Neuroradiol*, 2009; 30: 1513-17
- Fernandez Zubillaga A, Guglielmi G, Viñuela F, Duckwiler GR: Endovascular occlusion of intracranial aneurysms with electrically detachable coils: Correlation of aneurysm neck size and treatment results. *Am J Neuroradiol*, 1994; 15: 815-20
- Debrun GM, Aletich VA, Kehrli P et al: Selection of cerebral aneurysms for treatment using Guglielmi detachable coils: the preliminary University of Illinois at Chicago experience. *Neurosurgery*, 1998; 43: 1281-95; discussion 1296-97
- Debrun GM, Aletich VA, Kehrli P et al: Aneurysm geometry: An important criterion in selecting patients for Guglielmi detachable coiling. *Neurol Med Chir (Tokyo)*, 1998; 38(Suppl.): 1-20
- Cloft HJ, Joseph GJ, Tong FC et al: Use of three-dimensional Guglielmi detachable coils in the treatment of wide-necked cerebral aneurysms. *Am J Neuroradiol*, 2000; 21: 1312-14
- Chalouhi N, Starke RM, Koltz MT et al: Stent-assisted coiling versus balloon remodeling of wide-neck aneurysms: Comparison of angiographic outcomes. *Am J Neuroradiol*, 2013; 34: 1987-92
- Higashida RT, Smith W, Gress D et al: Intravascular stent and endovascular coil placement for a ruptured fusiform aneurysm of the basilar artery. Case report and review of the literature. *J Neurosurg*, 1997; 87: 944-49
- Gao X, Liang G: Complications and adverse events associated with stent-assisted coiling of wide-neck intracranial aneurysms. In: Murai Y (ed.), *Aneurysm, InTech*; 2012
- Johnson AK, Munich SA, Heiferman DM, Lopes DK: Stent assisted embolization of 64 anterior communicating artery aneurysms. *J Neurointerv Surg*, 2013; 5(Suppl. 3): iii62-65
- Poncyłjusz W, Biliński P, Safranow K et al: Stents in the treatment of wide-neck intracranial aneurysms: multicentre registry. *J Neurointerv Surg*, 2015; 7: 524-29
- Huang Q-H, Wu Y-F, Shen J et al: Endovascular treatment of acutely ruptured, wide-necked anterior communicating artery aneurysms using the Enterprise stent. *J Clin Neurosci*, 2013; 20: 267-71
- Akmangit I, Aydin K, Sencer S et al: Dual stenting using low-profile LEO baby stents for the endovascular management of challenging intracranial aneurysms. *Am J Neuroradiol*, 2015; 36: 323-29
- Geyik S, Yavuz K, Yurttutan N et al: Stent-assisted coiling in endovascular treatment of 500 consecutive cerebral aneurysms with long-term follow-up. *Am J Neuroradiol*, 2013; 34: 2157-62
- Fiorella D, Albuquerque FC, Deshmukh VR et al: Endovascular reconstruction with the Neuroform stent as monotherapy for the treatment of uncoilable intradural pseudoaneurysms. *Neurosurgery*, 2006; 59: 291-300; discussion 291-300
- Li C, Li Y, Jiang C et al: Stent alone treatment for dissections and dissecting aneurysms involving the basilar artery. *J Neurointerv Surg*, 2015; 7: 50-55
- Biondi A, Janardhan V, Katz JM et al: Neuroform stent-assisted coil embolization of wide-neck intracranial aneurysms: strategies in stent deployment and midterm follow-up. *Neurosurgery*, 2007; 61: 460-68; discussion 468-69
- Lima I, Bonaf A: Stent-assisted techniques for intracranial aneurysms. In: Murai Y (ed.), *Aneurysm, InTech*, 2012
- Guo X, Yan B, Guan S: Waffle-cone technique using solitaire AB stent for endovascular treatment of complex and wide-necked bifurcation cerebral aneurysms: Waffle-cone technique. *J Neuroimaging*, 2014; 24: 599-602
- Liu W, Kung DK, Policeni B et al: Stent-assisted coil embolization of complex wide-necked bifurcation cerebral aneurysms using the "waffle cone" technique. A review of ten consecutive cases. *Interv Neuroradiol J Peritherapeutic Neuroradiol Surg Proced Relat Neurosci*, 2012; 18: 20-28
- Harrigan MR, Deveikis JP: *Handbook of cerebrovascular disease and neurointerventional technique*. Totowa, NJ: Humana Press, 2009
- Kadkhodayan Y, Rhodes N, Blackburn S et al: Comparison of Enterprise with Neuroform stent-assisted coiling of intracranial aneurysms. *Am J Roentgenol*, 2013; 200: 872-78
- King B, Vaziri S, Singla A et al: Clinical and angiographic outcomes after stent-assisted coiling of cerebral aneurysms with Enterprise and Neuroform stents: A comparative analysis of the literature. *J Neurointerv Surg*, 2015; 7(12): 905-9
- Piotin M, Blanc R, Spelle L et al: Stent-assisted coiling of intracranial aneurysms: Clinical and angiographic results in 216 consecutive aneurysms. *Stroke*, 2010; 41: 110-15
- Ansari SA, Lassig JP, Nicol E et al: Thrombosis of a fusiform intracranial aneurysm induced by overlapping neuroform stents: Case report. *Neurosurgery*, 2007; 60: E950-51; discussion E950-51
- Doerfler A, Wanke I, Egelhof T et al: Double-stent method: therapeutic alternative for small wide-necked aneurysms. Technical note. *J Neurosurg*, 2004; 100: 150-54

Conclusions

Stent-assisted coil embolization of AcomA aneurysms is an acknowledged treatment method with a high success rate and low procedure-related mortality-morbidity rates.

Conflict of interest

None declared.

35. Tähtinen OI, Vanninen RL, Manninen HI et al: Wide-necked intracranial aneurysms: Treatment with stent-assisted coil embolization during acute (<72 hours) subarachnoid hemorrhage – experience in 61 consecutive patients. *Radiology*, 2009; 253: 199–208
36. Vanninen R, Manninen H, Ronkainen A: Broad-based intracranial aneurysms: Thrombosis induced by stent placement. *Am J Neuroradiol*, 2003; 24: 263–66
37. Cho YD, Kim KM, Lee WJ et al: Time-of-flight magnetic resonance angiography for follow-up of coil embolization with enterprise stent for intracranial aneurysm: Usefulness of source images. *Korean J Radiol*, 2014; 15: 161–68
38. Nakamura M, Montibeller GR, Götz F, Krauss JK: Microsurgical clipping of previously coiled intracranial aneurysms. *Clin Neurol Neurosurg*, 2013; 115: 1343–49
39. Seo D-H, Yoon S-M, Park H-R et al: Thromboembolic event detected by diffusion weighted magnetic resonance imaging after coil embolization of cerebral aneurysms. *J Cerebrovasc Endovasc Neurosurg*, 2014; 16: 175–83
40. Altay T, Kang HI, Woo HH et al: Thromboembolic events associated with endovascular treatment of cerebral aneurysms. *J Neurointerv Surg*, 2011; 3: 147–50
41. Fiorella D, Albuquerque FC, Woo H et al: Neuroform in-stent stenosis: Incidence, natural history, and treatment strategies. *Neurosurgery*, 2006; 59: 34–42
42. Brisman JL, Niimi Y, Song JK, Berenstein A: Aneurysmal rupture during coiling: Low incidence and good outcomes at a single large volume center. *Neurosurgery*, 2005; 57: 1103–9