



Received: 2016.05.31
Accepted: 2016.08.29
Published: 2017.05.01

Authors' Contribution:

- A** Study Design
- B** Data Collection
- C** Statistical Analysis
- D** Data Interpretation
- E** Manuscript Preparation
- F** Literature Search
- G** Funds Collection

Endovascular Repair of an Unusually Complex Anastomotic Pseudoaneurysm of an Aorto-Bisiliac Graft

Mirko Trentadue^{1ABCDEF}, Giovanni Puppini^{1ABCDEF}, Simone Perandini^{1ABCDEF},
Luca Mezzetto^{2ABDE}, Gian Franco Veraldi^{2ABD}, Stefania Montemezzi^{1D}

¹ Department of Radiology – Interventional Radiology Unit, University Hospital of Verona, Polo Chirurgico “P. Confortini”, Verona, Italy

² Department of Vascular Surgery, University Hospital of Verona, Polo Chirurgico “P. Confortini”, Verona, Italy

Author's address: Mirko Trentadue, Department of Radiology – Interventional Radiology Unit, University Hospital of Verona, Polo Chirurgico “P. Confortini”, Piazzale Stefani 1, Verona, Italy, 37124, e-mail: m.trentadue@hotmail.it

Background:

Anastomotic pseudoaneurysm is an underestimated complication of aorto-iliac grafts.

Case Report:

This case report describes an unusual presentation of a pseudoaneurysm with a particularly complex anatomy involving both the left iliac branches, which hindered the interpretation of diagnostic studies and therapeutic management in a patient with multiple comorbidities.

Conclusions:

The manuscript describes a successful management of such a complication by means of an elective endovascular approach.

MeSH Keywords:

Aneurysm, False • Aortic Aneurysm, Abdominal • Endovascular Procedures

PDF file:

<http://www.polradiol.com/abstract/index/idArt/899825>

Background

The risk of anastomotic pseudoaneurysm (APA) development at the anastomosis of bypass grafts after aortoiliac reconstructive surgery increases with time. The reported incidence of such a complication ranges widely in the literature (0.2 to 25%) and it is thought to be underdiagnosed, especially in the case of proximal, asymptomatic, retroperitoneal APAs [1–5].

In the reported case, the pseudoaneurysm involved both the iliac branches of the left side, an unusual presentation, hindering interpretation and treatment.

Case Report

A 78-year-old caucasian man, who was previously treated for an abdominal aortic aneurysm (AAA) by aneurysmectomy followed by aorto-bisiliac bypass with graft positioning and surgical re-implant of the left hypogastric artery on the graft, was referred 11 years later to our institution because of a large para-anastomotic pseudoaneurysm. The leakage involved both the internal and the external left iliac artery and it was detected during a routine ultrasound (US) examination (Figure 1) performed after a long time with no

follow-up during which no claudication, limb ischemia nor any other symptoms were referred. The patient was previously diagnosed with COPD, arterial hypertension, vascular encephalopathy and dilated cardiomyopathy.

Imaging investigations

Contrast-enhanced, multidetector, computed tomography angiography (CT-A) was performed (256-row CT, 1.25 mm slice thickness, matrix 512×512, 100 ml iopromide 370 mg/ml). The scan confirmed the ultrasound findings (Figure 2), showing a 55-mm-sized pseudoaneurysm encasing both the internal and external left iliac artery on their prosthetic anastomoses. Proximally to the false aneurysm, the graft had a narrow, acute angle kinking, while distally the opacification of both the native arteries appeared reduced due to contrast medium extravasation. On the contralateral side, a normal opacification of the external iliac artery was shown, while the internal iliac artery appeared briefly occluded in its proximal tract with distal recanalization.

Procedure

After a comprehensive evaluation of the imaging findings and of the patient's condition, the case was considered

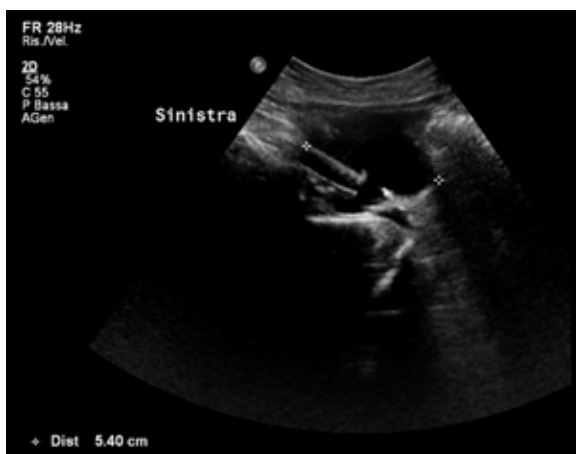

Figure 1. Ultrasound (US) image (oblique para-sagittal plane) showing an anechoic, eccentric, large sac clearly communicating with the lumen of the grafted left external iliac artery. The finding is consistent with a para-anastomotic pseudoaneurysm.

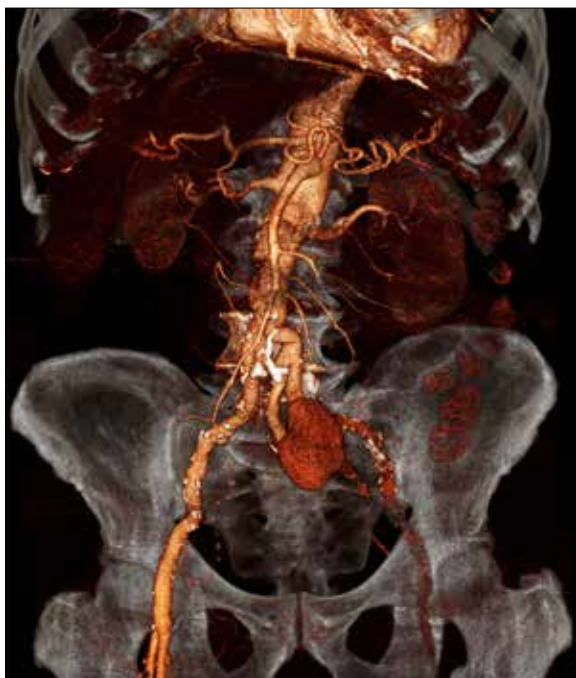

Figure 2. CT-Angiography image (shaded surface rendering) showing a large false aneurysm involving both the left iliac branches which are less opacified due to contrast media leakage into the sac. The CT-A also demonstrates kinking of the vessels upstream of the pseudoaneurysm.

suitable for an endovascular repair. Open surgery reconstruction was early ruled out because of the difficulties related to surgical re-intervention in a patient with multiple comorbidities. During the pre-procedural planning we decided to deploy a covered stent-graft in the left external iliac artery to exclude the pseudoaneurysm from the circulation via a left common femoral retrograde access. We also took into consideration the possibility of an access via the axillary artery to deploy another stent in the left hypogastric artery in an attempt to obtain a “double barrel” stenting.

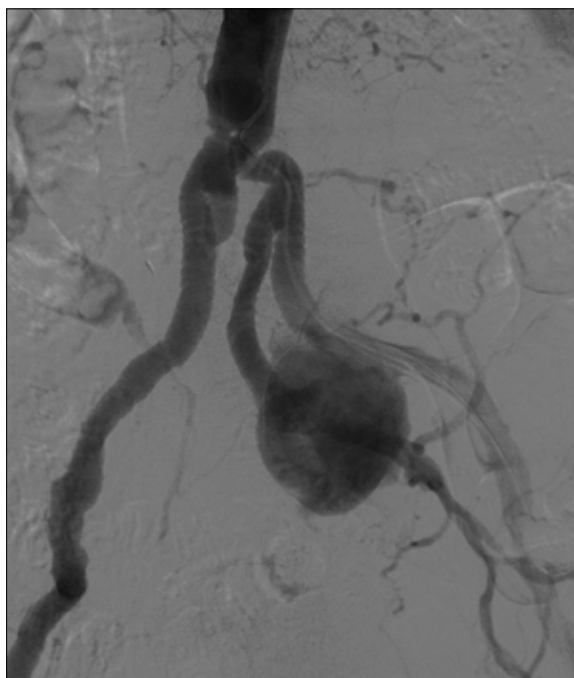


Figure 3. Pre-procedural Digital Subtraction Angiography (DSA), confirming CT-A findings and demonstrating a pseudoaneurysm on the left side with clear communication with both the iliac arteries. The complex anatomy of the upstream vessels on the left and a proximal occlusion of the right hypogastric artery are also shown.

After the retrograde approach, (6F Destination peripheral guiding sheath, Terumo) we performed a diagnostic aortography that confirmed a communication of the pseudoaneurysm at the distal anastomoses with the lumen of both the left iliac arteries, as suspected after angio-CT (Figure 3). For this reason and because of the upstream narrow kinking of the grafts, we decided to abandon the original plan to proceed via a radial/axillary antegrade approach. Furthermore, the presence of a satisfactory opacification of the distal branches of the contralateral hypogastric artery, in spite of its proximal focal stenosis, with a good blood supply to the pelvic viscera supported the decision to carry out an embolization of the prosthetic branch of the left internal iliac artery. Initially, systemic heparinization was induced and a 9×12 mm vascular plug (Amplatzer Vascular Plug II) was deployed via the retrograde left femoral access, navigating from the external iliac artery through the pseudoaneurysm (Figure 4). Subsequently, a fully covered stent (11×100 mm, Viabahn GORE Endoprosthesis) was deployed into the left external iliac artery. A complete exclusion of the pseudoaneurysm was also confirmed on post-procedural angiography (Figure 5). Hemostasis of the femoral access was achieved by means of a suture-mediated closure system (Perclose ProGlide, Abbott) and manual compression. The total duration of the procedure was 145 minutes and no periprocedural complications were registered. The patient was discharged 24 hours after the procedure with no symptoms.

Outcome

CT-A performed one month after the procedure showed a regular opacification of the left external iliac artery, while

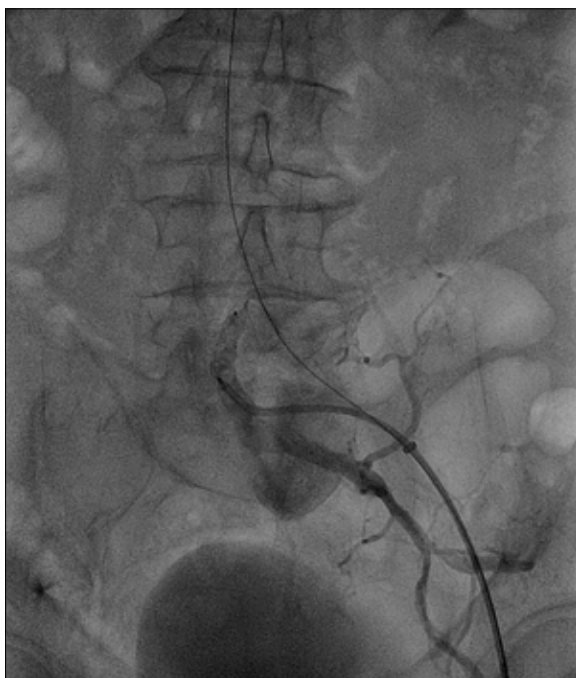


Figure 4. A DSA image during the procedure showing a vascular plug inside the proximal segment of the left internal iliac artery. Note the retrograde navigation of the device through the external artery and the pseudoaneurysmal sac, confirming the communication of both the branches with the leakage.

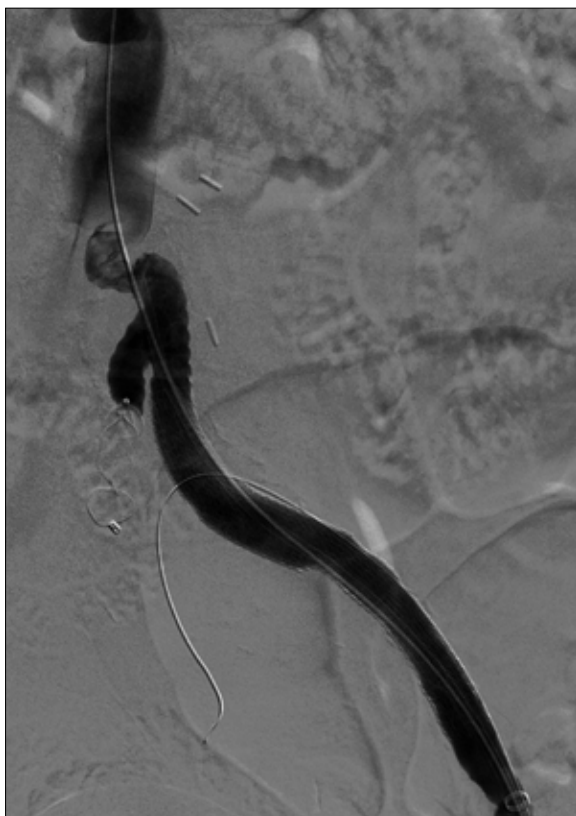


Figure 5. Post-procedure DSA image demonstrating a complete exclusion of the pseudoaneurysm after the placement of a covered stent into the external iliac artery and following the occlusion of the hypogastric artery with a vascular plug.

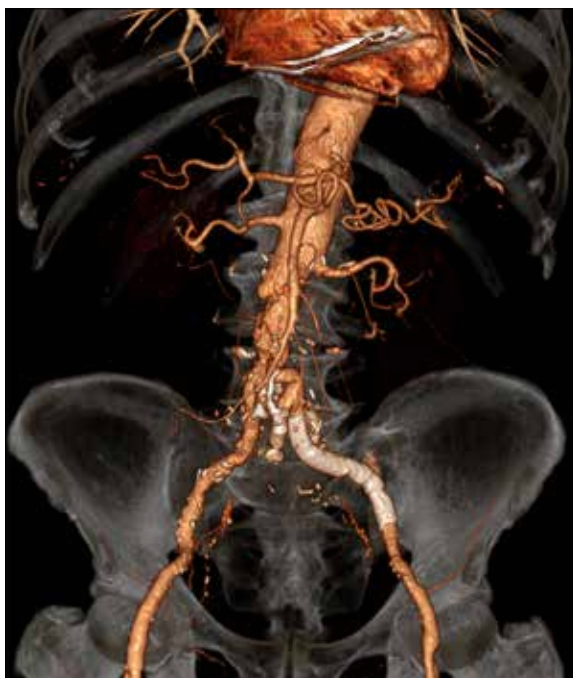

Figure 6. Follow-up CT-A (shaded surface rendering) confirms a complete exclusion of the pseudoaneurysm and the consequent restoration of a normal opacification in the external iliac artery. Distal recanalization of both the hypogastric arteries can also be observed.

the hypogastric artery demonstrated distal recanalization (Figure 6). No signs of endoleak and persistent exclusion of the pseudoaneurysm were also found on a Doppler ultrasound examination 3 months later. To date, after 6 months from the procedure, no symptoms have been noted with regard to the left lower limb. Furthermore, no symptom of vascular deprivation following left hypogastric artery occlusion, such as gluteal necrosis, claudication, colic or spinal cord ischemia, were reported.

Discussion

Para-anastomotic aneurysms are either true or false aneurysms. The former type is characterized by a fusiform and symmetric dilatation of the artery adjacent to the graft, whereas the latter type presents as an eccentric sac surrounded by fibrosis enclosing both the graft and the native artery [3,4]. The presented case is an example of the latter type.

The development of the sac is due to a progressive, pulsatile blood leakage into the soft tissues around the damaged artery and has been related to various pathogenetic conditions such as the worsening of the underlying atherosclerotic pathology, breakdown of the anastomotic suture, arterial hypertension, local infections and inflammatory reactions with subsequent fragility of the host arterial wall close to the anastomosis. Leakage becomes progressively encapsulated and shows a tendency to grow in a few months with possible rupture and consequent massive hemorrhage which is the most feared evolution [1,3,4,6,7].

Furthermore, the complication may cause arteriovenous fistulas or distal embolization with clinical onset of critical

limb ischemia. In case of a symptomatic APA, major reported signs and symptoms are abdominal pain, gastrointestinal hemorrhage, pulsatile abdominal mass and respiratory insufficiency [3,4,6,7]. At diagnosis, 8–40% of anastomotic pseudoaneurysms are ruptured, a condition whose reported mortality rate ranges from 61 to 67% [1,3,8].

Because of all the above-described reasons, APAs represent a complication which needs prompt and aggressive treatment. Nowadays, CT-Angiography (CT-A) represents the reference non-invasive imaging modality to make a diagnosis and to characterize the pseudoaneurysm and its associated complications such as retroperitoneal bleeding and arteriovenous, prosthetic-enteric or uretero-prosthetic fistulas. CT-A is also able to show clues of an impending rupture of false aneurysms such as fissuration or inhomogeneity of the parietal thrombus, and it allows for an optimal planning of the therapeutic approach [3,6].

Ultrasound-guided compression and minimally invasive treatments (e.g. percutaneous thrombin injection) can achieve thrombosis of femoral artery pseudoaneurysms in most cases [9], but if the pseudoaneurysm size is more than 6 cm or when the intra-abdominal arteries are involved, the range of therapeutic options is limited to the endovascular and the surgical approach. High mortality rates have been reported with regard to surgery. Emergency surgical repair has 70–83% morbidity and 8–70% mortality since most APAs occur in elderly patients with several comorbidities. The need for a prolonged aortic clamping in the presence of comorbidities and of an hostile abdomen, because of previous retroperitoneal intervention, often makes surgery challenging [1–5,8,10].

The endovascular approach is useful to reduce bleeding, interventional duration and complications including infections or iatrogenic damage with reduced morbidity and mortality, even when performed in an emergency setting with a post-operative mortality ranging from 0 to 3.6% [1–5,10,11]. Pseudoaneurysms involving both the proximal and distal graft anastomoses can be treated in the same way as aortic aneurysms, namely, with endoprosthesis

or stent-graft positioning with anchorages placed in the healthy pre- and post-anastomotic arterial lumen. Eccentric APAs, located either proximally or distally, may be treated with conic or tubular stent-grafts, possibly oversized to avoid migration, especially when treating the distal pseudoaneurysms. In such cases, the stent anchorage can also be placed inside the prosthetic lumen [3,10,12]. Coil embolization has also been proposed to treat small, proximal anastomotic aneurysms [3,13]. A relative contraindication to the endovascular approach is the presence of possible sources of infection of the graft, such as enteric fistulas [3].

In our case, the anastomotic pseudoaneurysm was incidentally found in an asymptomatic patient after 11 years since surgical AAA repair and its pathogenesis was thought to be degenerative, since no clinical or imaging evidence of graft infection was found. This late complication appeared particularly challenging since an open surgical repair was contraindicated because of the patient's general condition.

Furthermore, the unusual involvement of both branches of the iliac artery and the difficult anatomy found at imaging appeared to be challenging for an endovascular approach too. Procedural aortography clearly showed how both branches were actually feeding the pseudoaneurysm. Nevertheless, the endovascular approach, planned on the basis of a multidisciplinary evaluation, was considered the only viable option for the selected case.

Conclusions

The presented case shows a successful treatment achieved by means of an endovascular approach, confirming the effectiveness of the technique for treating patients with challenging anatomy. The immediate and late outcome was unremarkable, as there were no periprocedural complications and the patient's quality of life has been preserved.

Conflicts of interest

All the authors declare that they have no conflict of interest.

References:

1. Ten Bosch JA, Waasdorp EJ, de Vries JP et al: The durability of endovascular repair of para-anastomotic aneurysms after previous open aortic reconstruction. *J Vasc Surg*, 2011; 54(6): 1571–78
2. Duvnjak S, Andersen PE, Larsen KE, Roeder O: Endovascular repair of postoperative vascular graft related complications after aorto-iliac surgery. *Int Angiol*, 2014; 33(4): 386–91
3. Lagana D, Carrafiello G, Mangini M et al: Endovascular treatment of anastomotic pseudoaneurysms after aorto-iliac surgical reconstruction. *Cardiovasc Intervent Radiol*, 2007; 30(6): 1185–91
4. Morrissey NJ, Yano OJ, Soundararajan K et al: Endovascular repair of para-anastomotic aneurysms of the aorta and iliac arteries: Preferred treatment for a complex problem. *J Vasc Surg*, 2001; 34(3): 503–12
5. Tiesenhausen K, Hausegger KA, Tauss J et al: Endovascular treatment of proximal anastomotic aneurysms after aortic prosthetic reconstruction. *Cardiovasc Intervent Radiol*, 2001; 24(1): 49–52
6. Fukushima RB, Wolosker N, Benitti DA, Puech-Leao P: Endovascular treatment for iliac artery pseudoaneurysm with arteriovenous fistula after abdominal aortic aneurysm open repair. *Clinics (Sao Paulo)*, 2011; 66(8): 1499–500
7. Pogorzelski R, Fiszer P, Toutouchi S et al: Anastomotic aneurysms after arterial reconstructive operations – literature review. *Pol Przegl Chir*, 2014; 86(1): 48–56
8. Locati P, Socrate AM, Costantini E: Paraanastomotic aneurysms of the abdominal aorta: a 15-year experience review. *Cardiovasc Surg*, 2000; 8(4): 274–79
9. Wu AY, Al-Jundi W, Ziadi Z et al: Huge anastomotic femoral pseudoaneurysm following aorto-bifemoral bypass. *BMJ Case Rep*, 2011; 2011: pii: bcr0720103160
10. Curti T, Stella A, Rossi C et al: Endovascular repair as first-choice treatment for anastomotic and true iliac aneurysms. *J Endovasc Ther*, 2001; 8(2): 139–43
11. Magnan PE, Albertini JN, Bartoli JM et al: Endovascular treatment of anastomotic false aneurysms of the abdominal aorta. *Ann Vasc Surg*, 2003; 17(4): 365–74
12. van Herwaarden JA, Waasdorp EJ, Bendermacher BL et al: Endovascular repair of paraanastomotic aneurysms after previous open aortic prosthetic reconstruction. *Ann Vasc Surg*, 2004; 18(3): 280–86
13. Fann JI, Samuels S, Slonim S et al: Treatment of abdominal aortic anastomotic pseudoaneurysm with percutaneous coil embolization. *J Vasc Surg*, 2002; 35(4): 811–14